

Corrective Osteotomy and Intramedullary Pinning in a Golden Eagle with Angular Malunion Fracture of Radius and Ulna

Niloofer Seydi^{1*}, Ali Ghashghai¹ and Fatemeh Ramezanzpour²

¹ Assistant Professor, Department of Clinical Sciences, Faculty of Veterinary Medicine, Razi University, Kermanshah, Iran

² DVM Student, Faculty of Veterinary Medicine, Razi University, Kermanshah, Iran

Received: 20.05.2024

Accepted: 03.08.2024

Abstract

Some of avian orthopedic problems occur as a result of trauma (ceiling fan injuries, flying into a window or mirror, or getting stepped on); others occur from nutritional imbalances or as a result of genetic or developmental problems. An adult female golden eagle (*Aquila chrysaetos*) was presented to the clinic of faculty of veterinary medicine of Razi University (Kermanshah, Iran) with a history of being unable to fly. Physical examination revealed some abnormality in the left wing. Radiographic examination showed radius and ulna midshaft fracture angular malunion. The bird was prepared for aseptic surgery and so malunion part of the bone was cut. After correction and aligning of the bones, both ulna and radius were fixed with intramedullary pin. The bird was discharged without any complication. Case follow up showed an uneventful improvement and 6 weeks later the ulna pin was removed, but the radius pin was remained. Most of the orthopedic techniques developed for mammals can be applied to birds, taking into account the anatomical differences in avian species, and whether or not the bird can have flight restored. Fracture malunion in raptors can compromise muscle and tendon function and adversely affect normal activities that are essential for survival of these species. Malunion can be acutely corrected by osteotomy techniques, followed by bone fixation that provides sufficient stability to allow unimpeded healing with minimal soft tissue injury.

Keywords: Eagle, Intramedullary pin, Malunion, Osteotomy

Introduction

The Golden Eagle (*Aquila chrysaetos*) is one of the best birds of prey in the Northern Hemisphere. Like all eagles, golden eagle belongs to the eagle family. In Iran, this animal is found in many different parts of the country (Babaei et.al, 2022). Avian fractures heal in the same manner as those in mammals but the rate of bone heals is probably a little faster (Tully, 2002; Straw, 1984). It is most rapid in the smaller birds and one can detect signs of healing on X-ray plates within eight days (Ecams et al, 2007). Avian bones have a high calcium content,

and a thin, brittle nature (Ritchie et al, 1994). As in mammals, excessive displacement of the fractured ends, movement and infection all retard healing (Ecams et al, 2007). Wing and leg fractures in birds are the most common problems (Ecams et al, 2007). Thirty percent of the fractures involve only the ulna, 60% involve the ulna and radius, and 10% only the radius (Forbes, 1998). These bones have little soft tissue support, the soft tissue being prone to desiccation. In birds having a fracture of either the ulna or the radius, cage

* **Corresponding Author:** Niloofer Seydi, Assistant Professor, Department of Clinical Sciences, Faculty of Veterinary Medicine, Razi University, Kermanshah, Iran
E-mail: nseydi@razi.ac.ir



rest alone (with or without support) is usually adequate, if there is little displacement. The bird should be able to move its wings but not extend or flap them fully, for a period of 2-3 weeks. (Forbes, 1998). Recommended surgical techniques used to repair ulnar fractures include the use of an intramedullary pin, external skeletal fixator tie-in or a type I external skeletal fixator (Sarker et al, 2022). Because of the relative mobility of the radius, external coaptation alone is not recommended for the management of radial fractures, which are best stabilized with an intramedullary pin (Ritchie et al, 1994). Viable and nonviable malunions can occur in birds. Malunions occur when the ends of fractured bones heal but not to each other and can produce bone shortening, angulation of the distal fragment, rotation of the proximal or distal fragment, development of joint pain, or cosmetic deformity (Roush, 1980). Stabilization requires removing necrotic debris, freshening the bone ends and compressing and rigidly stabilizing the fracture site (Roush, 1980). The case study describes, corrective osteotomy and intramedullary pinning in an eagle with angular malunion fracture of radius and ulna.

History

An adult female golden eagle (*Aquila chrysaetos*) (Figure 1) was presented to the clinic of faculty of veterinary medicine of Razi University (Kermanshah, Iran) with a history of being unable to fly. Physical examination revealed some abnormality in the left wing. Radiographic examination showed radius and ulna midshaft fracture angular malunion (Figure 2a). The bird was anesthetized with midazolam (Exir-Iran, Tehran, Iran) (1mg/kg) and ketamine (Alfasan, holland) (20mg/kg). The antebrachium feathers were plucked, and the surgical site was prepared routinely for Aseptic surgery. The bird was restrained in dorsal recumbency and the affected region was draped. An incision was made on craniomedial side of the antebrachium. A

closing-wedge osteotomy was performed at the point of the greatest deformity of the ulna and radius by means of an oscillatory bone saw irrigated with 0.9% saline solution (Figure 3). After correction and aligning of the bones, the ulnar fracture was fixed with 2 mm Kirschner wire by retrograde intramedullary pinning method. The radius was fixed with an 1mm intramedullary pin via a shuttle method. The surgical site was vigorously irrigated with physiologic saline and muscles and subcutaneous tissues were sutured with simple continuous suture pattern using no. 3/0 catgut (Pezeskyaran, Tehran, Iran). The Skin was sutured with the same suture pattern using no. 2/0 nylon (Pezeskyaran, Tehran, Iran). Antibiotic therapy with enrofloxacin (Razak, Tehran, Iran) (20 mg/kg IM) was begun immediately after anesthetic induction and continued orally for 4 days. A figure-of-eight bandage was placed on the right wing, and the wing was bandaged to the body. The bandage was changed twice every five days and removed after 15 days. The owner of the bird was advised to keep the bird in confinement. Immediate postoperative radiographs showed correction of bone malalignment (Figure 2b). Although the recovery from the anesthesia was prolonged, but the bird was discharged without any complication. Case follow up showed an uneventful improvement and 6 weeks later the ulna pin was removed, but the radius pin was remained.



Figure 1: An adult female golden eagle (*Aquila Chrysaetos*) with angular malunion fracture of radius and ulna




Figure 2: Radiographic images of the radius and ulna before(a) and after(b) corrective osteotomy

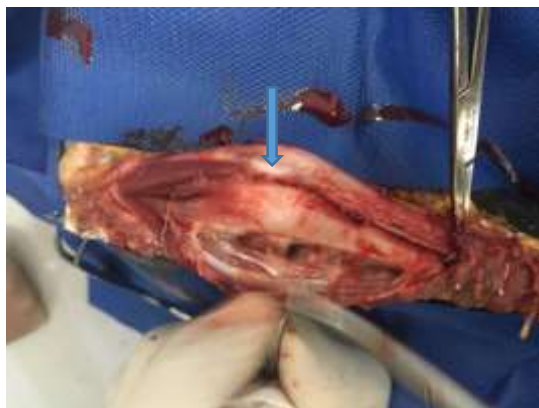

Figure 3: Intra-operative image of the malunion radius & ulna

Discussion and Conclusion

Fracture malunion in a raptor can compromise muscle and tendon function and adversely affect normal activities that are essential for survival in the wild. Several techniques of corrective osteotomies are described that should be used according to deformity, including transverse-opening wedge, closing wedge, reverse wedge, oblique, stairstep, transverse

derotational; and dome (Ecams et al, 2007). Malunion can be acutely corrected by osteotomy techniques followed by bony fixation that provides sufficient stability to allow unimpeded healing with minimal soft-tissue injury (Rochat et al, 2005). Different types of methods such as external coaptation, external skeletal fixation, intramedullary pin alone or tie-in, intramedullary rod, circular ring fixators, bone plates, and interlocking nail, may be used to fixate the fracture or osteotomy site (Sarker et al, 2022). In the majority of cases, the most satisfactory results in terms of restoration of limb anatomy and function are achieved using internal fixation. In comparison to mammalian patients, bone plating has received scant attention for a variety of reasons, including small patient and bone size, cost, morbidity associated with placement and in the case of wild birds the need for follow-up surgeries to remove implants (Ecams et al, 2007). Intramedullary (IM) pins and external skeletal fixators (ESF) alone continue to be used with success as shown in a metacarpal fracture in a golden eagle (*Aquila chrysaetos*) and tarsometatarsal fracture in a Harris hawk (*Parabuteo unicinctus*) (Grier, 1973). The introduction of the ESF – IM pin “tie in” or “hybrid” fixator, however, has revolutionised the management of avian long bone fractures (Ritchie et al, 1994). Internal fixation may be used for fracture management in both medium and large birds in much the same manner as mammals. The major problem involves the lack of appropriate sizes of pins, screws and plates. Most of these were developed for human or small animal use. Consequently, their size and weight are prohibitive, except for the larger raptors. Other problems associated with internal fixation include providing adequate exposure, minimal sepsis and articulation insult (Fowler et al, 2003). Steinman pins may be used for retrograde pinning of the humerus but seem to be of more value in ulnar fractures when the radius is also fractured (Bush, 1977). In

about 50% of cases either the radius or the ulna is fractured, but not both. The method of repair of fractures of the radius and ulna will depend upon the integrity of the other bone of the pair. When only one bone is fractured it is wiser to leave the fractured bone alone. The normal one will help to splint it. Even if there is not perfect alignment of the healed fractured bone which does not matter, the bird will manage quite adequately and fly again. Strapping of the wing for 2–3 days only is required. However, if both radius and ulna are fractured some method of splinting will be required (Rupiper, 1993; Kubiak et al, 2011). The ulna is pinned in normograde fashion. Retrograde placement is contraindicated, as it risks exiting the pin at the olecranon and damaging the joint (Helmer et al, 2006). However, in selecting a method of treatment for birds, care must

be taken with regard to device weight, fracture and/or osteotomy location, the absence of soft tissue support, pneumatic long bones, with large intramedullary spaces, brittle and thin cortical bone, and level of function expected after treatment (Ozsemir et al, 2021; MacCoy, 1992). Although repair of avian malunion fractures have been reported (Kuzma et al, 1991; Marlow et al, 1981; Mitchell et al, 2002; Rochat et al, 2005). the treatment is always challenging and each case should be evaluated individually. In this case, after correction and aligning of the bones, both ulna and radius were fixed. The bird was discharged without any complication. Case follow up showed an uneventful improvement and 6 weeks later the ulna pin was removed from the ulna, but the radius pin was remained.

Acknowledgment

The authors appreciate Mr. Amiri for referring this bird to the Faculty of Veterinary Medicine of Razi University and post-operative follow-up.

Conflict of Interest

The authors have no conflict of interest to declare.

Funding

This case report was funded by the research grants of Faculty of Veterinary Medicine, Razi University, Kermanshah, Iran.

References

- Babaei, M., Kalantari-Hesari, A., Esfandiyari, K., & Morovvati, H. (2022). Morphological and histological investigation of proventriculus structure in common kestrel (*Falco tinnunculus*), steppe eagle (*Aquila nipalensis*), golden eagle (*Aquila chrysaetos*), and imperial eagle (*Aquila heliaca*). *Iranian Veterinary Journal*, 18(1), 5-17.
- Bush, R. M. (1977). External fixation of avian fractures. *Journal of the American Veterinary Medical Association*.
- Ecams D, Frcvs H. (2007). Essentials of Avian Medicine and Surgery. 3rd edition, 164-176.
- Forbes, N. A. (1998). Avian orthopedics. *Veterinary Quarterly*, 20(sup1), S69-S70.
- Fowler, M. E., & Miller, R. E. (2003). Zoo and wild animal medicine.
- Grier, J. W. (1973). Techniques and results of artificial insemination with golden eagles. *Journal of Raptor Research*, 7(1), 1.
- Helmer, P., & Redig, P. (2006). Surgical Resolution of Orthopedic Disorders, [in:] Harisson JG, Lightfoot T.(eds.): Clinical Avian Medicine.
- Kubiak, M., & Forbes, N. (2011). Veterinary care of raptors: 2. Musculoskeletal problems. *In Practice*, 33(2), 50-57.
- Kuzma, A. B., & Hunter, B. (1991). A new technique for avian fracture repair using intramedullary polymethylmethacrylate and bone plate fixation.

- MacCoy, D. M. (1992). Treatment of fractures in avian species. *Veterinary Clinics of North America: Small Animal Practice*, 22(1), 225-238.
- Marlow, J. J., & Seibels, R. E. (1981). A technique for repairing fractures in birds.
- Mitchell M.A, Tully T.N. (2002) What is your diagnosis? *Journal of Avian Medicine and Surgery*.; 16:72–76
- Ozsemir, K. G., & Altunatmaz, K. (2021). Treatment of extremity fractures in 20 wild birds with a modified Meynard external fixator and clinical assessment of the results. *Veterinárni medicína*, 66(6).
- Rochat, M. C., Hoover, J. P., & DiGesualdo, C. L. (2005). Repair of a tibiotarsal varus malunion in a bald eagle (*Haliaeetus leucocephalus*) with a type 1A hybrid external skeletal fixator. *Journal of Avian Medicine and Surgery*, 19(2), 121-129.
- Roush, J. C. (1980). Avian orthopedics. *Current Veterinary Therapy VII. Philadelphia, PA: WB Saunders*, 662-673.
- Rupiper, D. J. (1993). Application of Visible Light Curing Composite Splints to Fractured Avian Legs. *Journal of the Association of Avian Veterinarians*, 147-149.
- Ritchie, B. W., Harrison, G. J., & Harrison, L. R. (1994). Avian medicine: principles and application, 1137–1170.
- Sarker, D., Paul, T., Yadav, S. K., & Das, B. C. (2022). Surgical management of complete transverse radioulnar fracture in Congo African grey parrot.
- Straw, R. C. (1984). The Kirschner-Ehmer splint in small animal orthopedics. *Modern Veterinary Practice*, 65(7), 503-508.
- Tully Jr, T. N. (2002). Basic avian bone growth and healing. *The veterinary clinics of North America. Exotic animal practice*, 5(1), 23-30.

Received: 20.05.2024

Accepted: 03.08.2024

استئوتومی اصلاحی و تثبیت شکستگی بدجوش خورده زاویه دار رادیوس و اولنا با پین داخل مدولاری در یک بهله عقاب طلائی

نیلوفر صیدی^{۱*}، علی قشقایی^۱ و فاطمه رمضان پور^۲

^۱ استادیار گروه علوم بالینی، دانشکده دامپزشکی، دانشگاه رازی، کرمانشاه، ایران

^۲ دانشجوی دکترای حرفه‌ای، دانشکده دامپزشکی، دانشگاه رازی، کرمانشاه، ایران

تاریخ دریافت: ۱۴۰۳/۲/۳۱

تاریخ پذیرش: ۱۴۰۳/۵/۱۳

چکیده

برخی از مشکلات ارتوپدی پرندگان در نتیجه ضربه (آسیب به وسیله پنکه سقفی، پرواز و برخورد با پنجره یا آینه، یا گذاشتن روی آن)، و برخی دیگر در اثر عدم تعادل تغذیه‌ای یا در نتیجه مشکلات ژنتیکی یا رشدی رخ می‌دهند. یک بهله عقاب طلائی ماده بالغ با سابقه ناتوانی در پرواز به کلینیک دانشکده دامپزشکی دانشگاه رازی (کرمانشاه، ایران) ارجاع شد. معاینه فیزیکی برخی ناهنجاری‌ها را در بال چپ نشان داد. در معاینه رادیوگرافی شکستگی بدجوش خورده زاویه‌ای در قسمت میانی بدنه استخوان رادیوس و اولنا مشخص شد. پرنده برای جراحی آسپتیک آماده شد و قسمتی از بدجوش خوردگی استخوان بریده شد. پس از اصلاح و تراز شدن استخوان‌ها، هر دو استخوان اولنا و رادیوس توسط پین داخل مدولاری ثابت شدند. پرنده بدون هیچ عارضه‌ای مرخص شد. پیگیری صورت گرفته بهبودی بدون مشکلی را نشان داد و ۶ هفته پس از جراحی، پین داخل مدولاری اولنا خارج گردید، اما پین داخل مدولاری رادیوس باقی ماند. بیش‌تر تکنیک‌های ارتوپدی مورد استفاده برای پستانداران را می‌توان با در نظر گرفتن تفاوت‌های آناتومیکی در گونه‌های مختلف پرندگان، و این که آیا پرنده می‌تواند دوباره پرواز کند یا نه، برای پرندگان به کار برد. بدجوش خوردگی شکستگی در پرندگان شکاری می‌تواند عملکرد ماهیچه‌ها و تاندون‌ها را به خطر بیندازد و بر فعالیت‌های عادی که برای بقای این گونه‌ها ضروری است، تأثیر منفی بگذارد. بدجوش-خوردگی استخوان را می‌توان با تکنیک‌های استئوتومی و به دنبال آن تثبیت استخوان که ثبات کافی را فراهم می‌کند تا امکان التیام بدون تداخل با حداقل آسیب بافت نرم فراهم شود، اصلاح نمود.

کلمات کلیدی: عقاب، پین داخل مدولاری، بدجوش خوردگی، استئوتومی

* نویسنده مسئول: نیلوفر صیدی، استادیار گروه علوم بالینی، دانشکده دامپزشکی، دانشگاه رازی، کرمانشاه، ایران

E-mail: nseydi@razi.ac.ir



© 2020 by the authors. Licensee SCU, Ahvaz, Iran. This article is an open access article distributed under the terms and conditions of the Creative Commons Attribution-NonCommercial 4.0 International (CC BY-NC 4.0 license) (<http://creativecommons.org/licenses/by-nc/4.0/>).