

# Iranian Veterinary Journal

## Founder

SHAHID CHAMRAN UNIVERSITY OF AHVAZ

## Director in Chief

Dr. Mansoor Mayahi

## Editor in Chief

Dr. Mohammad Rahim Haji Hajikolaie

## Expert

Mona Abbasi

## Editorial Board

Abbas Ali Pourkabireh, M., Professor of Clinical Biochemistry, Faculty of Veterinary Medicine, University of Tehran, Iran.  
Ahmadizadeh, M., Professor of Toxicology, Faculty of Health, Ahvaz Jundishapur University of Medical Sciences, Iran.  
Akhtardanesh, B., Professor of Small Animal Internal Medicine, Faculty of Veterinary Medicine, Shahid Bahonar University of Kerman, Iran.  
Baniadam, A., Associate Professor of Veterinary Surgery, Faculty of Veterinary Medicine, Shahid Chamran University of Ahvaz, Iran.  
Ghafourian Boroujerdnia, M., Professor of Immunology, Faculty of Medicine, Ahvaz Jundishapur University of Medical Sciences, Iran.  
Gharib Naseri, M.K., Professor of Physiology, Faculty of Medicine, Ahvaz Jundishapur University of Medical Sciences, Iran.  
Ghorbanpoor, M., Professor of Microbiology, Faculty of Veterinary Medicine, Shahid Chamran University of Ahvaz, Iran.  
Haji Hajikolaie, M.R., Professor of Large Animals Medicine, Faculty of Veterinary Medicine, Shahid Chamran University of Ahvaz, Iran.  
Hamidinejat, H., Professor of Parasitology, Faculty of Veterinary Medicine, Shahid Chamran University of Ahvaz, Iran.  
Hemmatzadeh, F., Associate Professor of Virology, Faculty of Animal and Veterinary Sciences, University of Adelaide, Australia.  
Jolodar, A., Professor of Molecular Genetics, Faculty of Veterinary Medicine, Shahid Chamran University of Ahvaz, Ahvaz, Iran.  
Karim, G., Professor of Health and Food Safety, Faculty of Veterinary Medicine, University of Tehran, Iran.  
Kohli, R.N., Professor of Veterinary Surgery, and Editor of National Academy of Veterinary Sciences, India.  
Morovvati, H., Professor of Histology, Faculty of Veterinary Medicine, University of Tehran, Iran.  
Naem, S., Professor of Parasitology, Faculty of Veterinary Medicine, University of Urmia, Iran.  
Najafzadeh Varzi, H., Professor of Medical Pharmacology, Faculty of Veterinary Medicine, Shahid Chamran University of Ahvaz, Iran.  
Pourmahdi Borojeni, M., Associate Professor of Epidemiology, Faculty of Veterinary Medicine, Shahid Chamran University of Ahvaz, Iran.  
Ranjbar, R., Associate Professor of Anatomical Sciences, Faculty of Veterinary Medicine, Shahid Chamran University of Ahvaz, Iran.  
Razi Jalali, M., Professor of Clinical Pathology, Faculty of Veterinary Medicine, Shahid Chamran University of Ahvaz, Iran.  
Seyfi Abad Shapouri, Professor of Virology, Faculty of Veterinary Medicine, Shahid Chamran University of Ahvaz, Ahvaz, Iran.  
Sahinduran, Sh., Professor of Internal Medicine, Faculty of Veterinary Medicine, Burdur Mehmet Akif Ersoy University, Burdur, Turkiye

## Advisory Editorial Board

Academic staffs of all veterinary medicine faculties and other relevant faculties and research centers

## Mailing Address of the Editor

Dr. Mohammad Razi Jalali, DVM, PhD  
Editor in chief of Iranian Veterinary Journal  
Ahvaz, Postal Code: 61355 P.O. Box : 145, Iran  
Tel / Fax : +98 61 33336312  
<http://ivj.ir>  
E-mail: [ivj@scu.ac.ir](mailto:ivj@scu.ac.ir)

This Journal has been granted the rating of **Scientific – Research** by the Commission for Evaluation of Iranian Scientific Journals, the Ministry of Science, Research and Technology, through the letter numbered 3.2910.545 dated 30.7.2006

This journal is indexed by Iran and Islamic World Scientific Citation Center (ISC)

## Published by

Regional Information Center for Science and Technology and Islamic World Science Citation Center

# IRANIAN VETERINARY JOURNAL

SCIENTIFIC – RESEARCH

## Contents

Title	Page
• Instructions for contributors	1
• Evaluation of epidemiological and clinical findings of canine hyperadrenocorticism in Iran Mohammad Asadi Iraee, Reza Avizeh, Mohammad Razijalali and Mahdi Pourmahdi Borujeni	5
• Association between presence of DNA and antibody in the serum during vertical transmission of <i>Neospora caninum</i> Razieh Ayati, Hossein Rezvan, Mohammad Mehdi Namavari, Ali Sadeghi-nasab, Sahar Hamoon Navard and Bahram Dadmehr	16
• Muscular Stomach in Birds of Prey, Common Kestrel ( <i>Falco tinnunculus</i> ), Steppe Eagle ( <i>Aquila nipalensis</i> ), Golden Eagle ( <i>Aquila chrysaetos</i> ) and Imperial Eagle ( <i>Aquila heliaca</i> ); A Morphological Evaluation Ali Kalantari-Hesari, Mohammad Babaei, Kaveh Esfandiyari and Hassan Morovvati	24
• Effects of uncontrolled queen importation and migratory beekeeping on the racial purity and spermatological parameters of honey bee ( <i>Apis mellifera anatoliaca</i> ) population in Central Anatolia Abdulkadir Kaya and Numan Akyol	35
• The effect of Eggplant peel extract addition ( <i>Solanum melongena</i> ) on Farahani ram sperm after oxidative stress (freeze-thawing) Hamidreza Khodadadi, Mahdi Khodaei- Motlagh, Mehdi Kazemi-Bonchenari and Hamid Reza Momeni	45
• The identification of the primordial germ cells in the male gonads of pheasant ( <i>Phasianus colchicus</i> ) embryos using histochemical and immunostaining techniques Farhad Mohammadi Gheshlagh, Azam Hosseini and Abolghasem Nabipour	52
• The effects of Chaste-berry fruits on hypothalamic-pituitary-ovarian markers gene expression and immune response of laying hens: Phytoestrogens in Chaste-berry are ER $\beta$ -selective Mahmood Nazari, Mohamad Reza Ghorbani, Mohamad Taghi Beighi Nassiri, Neda Fathimoghadam, Razieh Sabahi and Saiedeh Taghva Mosavi	61
• Effects of <i>Froriepia subpinnata</i> extract on serum biochemicals and histopathological changes of liver in rats treated with trichloroacetic acid Seyede Hamide Taheri Otaghsara, Gasemali Garoosi, Hossein Najafzadehvarzi and Sohrab Kazemi	72
• The study of fat, Protein, and production levels of milk in Holstein dairy cows treated with arginine Ali Tirgari, Majid Mohammadsadegh, Morteza Gorjidoz, Ali Afshar Bahrabad and Nima Farzaneh	83
• Evaluation of the estrus synchronization and reproductive performance of Farahani ewes during the breeding season following treatment with letrozole Mohammad Yahyaei, Mahdi Khodaei Motlagh and Sobhan Akarim Alamdar	90

## Guide for Authors

**Authors who are in the Farsi profile journal system do not need to create an English profile and should submit an article through their previous profile.**

The aim of the publication of the *Iranian Veterinary Journal* is to publish research papers in various fields of veterinary medicine, medicine, biology and other sciences related to scientific and practical applications in veterinary and medical sciences. Articles will be published containing new findings in the specialized fields mentioned above. A case report is also available in this journal. Received papers will be published by the relevant experts and reviewed by the editorial board after initial review and arbitration. All or part of the submission should not have been published or has already been submitted to another journal. If the article has previously been submitted to the congress or scientific congress, please indicate the full details of the congress or relevant congress. This journal is published the annual quarterly form in four issues.

### Essential files for submission

- 1) Main article file without the authors' names and containing all the parts of the article based on the base of the article.
- 2) Authors' Affiliation: For example First Name Last Name: Professor, Department of Clinical Sciences, Faculty of Veterinary Medicine, Shahid Chamran University of Ahvaz, Ahvaz, Iran

\* No need to send tables and figures in separate files.

### Types of Manuscripts

#### A. Original Article

The research paper is the result of the research work of the author or authors and has the title, abstract, keywords, introduction, materials and method, results, discussion, list of references and abstract of English, and **should not exceed 12 pages or less than 6 pages.**

#### B. Short Paper

This article is based on the type of work and the way of editing, as with the research paper. However, due to the importance and results of the research, the paper is presented in a compact and maximal format in **6 pages of the journal**. It is also necessary to have the title, abstract, keywords, introduction, materials and methods, results, discussion, bibliography and English.

#### C) Case Report

These reports contain rare and informative clinical and laboratory items and have the title, abstract, keywords, introduction, history, method of diagnosis, discussion and conclusion, bibliography and abstract in Persian, and should not be exceeded from **4 pages**.

### Essentials for writing and submitting the article

#### 1. The title

The title of the article is expressly and concisely brief and covers the whole article. The title of the article, the name of the author or authors, with the mention of a scientific or academic rank in both Farsi (for Persian speakers) and English with full postal address, mobile or fixed number, fax and e-mail address of the author on a separate page (page 1).

#### 2. Abstract

The abstract considering that the referrers to the article first use the summary of the article for evaluation, and given that the summary is usually published by the centres and scientific information institutes, this part of the article should be accurate and fluent, and a maximum of 300 words represent the chief complaint, purpose,

method, overall conclusions and conclusions of that research. Persian (for Persian speakers) abstract should also be included.

### 3. The keywords

The keywords are considered to be introduced and guidelines of the article, at least 4 and maximums of 8 words.

### 4. The introduction

The introduction contains the importance of research and the scientific background of the work.

### 5. Materials and methods

Materials and methods of the work include a detailed and complete description of the consumables, the number, type and description of the specimens, the devices specifically designed for the research, with their full specifications and the method of execution. If the usual methods are used, they should refrain from mentioning them and mention the references, but if a new method is used, the full description of that method, together with the mention of the scientific names and sources of supplies, is essential. The statistical methods used should be presented in a comprehensible manner and based on valid references.

### 6. The results

The results of the research can be presented in the form of a table with all lines, diagrams and images with the necessary explanations. Figures and tables should be completely clear and easy to understand, and at the same time express the true results of the experiments. Make clear images and graphs and avoid sending a copy of them. The axes of the chart are fully defined and avoid any unnecessary explanations. Each of the tables, charts and images with the number in the specified text and captions of the tables at the top of the table and captions of the figures are presented below the figures. All images, tables and charts should be included in the text of the article. Data

presented in tables or figures should not be discussed in this section. The results presented in the tables should not be repeated in the article, such as graphs or text.

### 7. Discussion

In the discussion, the presented results should be analyzed and interpreted, and it should attract the attention of the readers on the main subject of the research, the hypotheses in the introduction section and the results of the research. This section discusses the relationships between influential factors or shortcomings and proposes new ideas. Even if there is a consensus or difference between the results of this research and the research carried out in this field, the scientific and theoretical applications will emphasize the achievements of this research and the fundamental inference of this study and refrain from repeating the results.

8. The author/s can thank others which helped them to do research or prepare a paper. It should be noted that in the case of financial support and the use of laboratory equipment, the place of research and the name of the institution or persons concerned may be mentioned.

9. The list of references is limited to authoritative scientific books and articles and is not used in dissertations, articles presented at congresses and scientific congresses, and in internet sites.

**English Font and size:** Times New Roman, 12, 1.5space with 2 cm margins

**Persian Font and Size:** B lotus, 14, 1.5 space with 2 cm margins

It should be considered that the references excluded for page numbering.

### How to cite the references in the manuscript?

All references used in the article should be used with the name of the author or authors as follows:

In the case of the references at the end of the paragraph, the method of referring to it at the end of the paragraph and in parentheses is as follows:

- If one is an author, (Mellor 2005), if there are two authors, (Arthur and Noakes 2011) and more than two authors, (Pearson et al., 2012).

If the reference is mentioned at the beginning of the relevant paragraph, the method of referring to it at the beginning of the paragraph without brackets is given by the following examples:

- If two authors: Arthur and Noakes in 2011, they reported that. . . And more than two authors: Pearson et al., in 2012 Reported that ...

### How to list the references?

All references which are used in the article should be included in the references list. Also, all references should be written in alphabetical order without mentioning the number. It should be noted that in the case of Persian references, the English equivalent is brought to its end in parentheses in Persian.

### The use of theses, congresses, conferences, protocols, and sites in the references is not acceptable.

#### How to write references in the references list is as follows:

- Article: Herbert, R.; Nanney, J. and Spano, J.S. (1986). Erythrocyte distribution in ducks. American Journal of Veterinary Research, 50 (2): 958-960.

If the reference is part of a book, the surname of the author or authors of that book chapter with the initials, chapter title, title of the book, surname of the author or authors of the book, together with the first letters of the author's name, year of publication, publication number of the book, place release the book and number of pages, for example:

- Book: Arthur, G.H.; Noakes, D.E.; Pearson, H. and Parkinson, T.J. (1996).

Veterinary Reproduction and Obstetrics. 7<sup>th</sup> ed. Saunders, London, Pp: 634-645.

Also, the name of the journals in the references section should be completely written and avoid abbreviated terms.

If the number of the authors of the article is more than 6, then added et al. after the sixth person.

### Submission

The articles should be submitted through the electronic journal site to <http://www.ivj.ir>.

### Article responsibility

The scientific and ethical responsibility of the article lies with the author or authors.

### Submit a printed article (Reprint)

The published article is sent by the Islamic World Science Citation Center (ISC) for the corresponding authors of the article to distribute among the authors.

### Copyright

Please download and complete the copyright form and submit it through the journal's electronic system.

### Conflicts of Interest

Please download and complete Conflicts of Interest form and submit it through the journal's electronic system. Conflicts of interest comprise those which may not be fully apparent and which may influence the judgment of author, reviewers, and editors. They have been described as those which, when revealed later, would make a reasonable reader feel misled or deceived. They may be personal, commercial, political, academic or financial. "Financial" interests may include employment, research funding, stock or share ownership, payment for lectures or travel, consultancies and company support for staff. Authors must identify and declare any personal circumstances or interest that may be perceived as inappropriately influencing the

representation or interpretation of reported research results. If there is no conflict of interest, please state "The authors declare no conflict of interest." Any role of the funding sponsors in the design of the study; in the collection, analyses or interpretation of data; in the writing of the manuscript, or in the decision to publish the results must be declared in this section. If there is no role, please state "The founding sponsors had no role in the design of the study; in the collection, analyses, or interpretation of data; in the writing of the manuscript, and in the decision to publish the results". Complete the Conflicts of Interest form and submit it through the journal's electronic system.

### **Publication Fee**

Manuscripts that are accepted for publication in the Iranian Veterinary

Journal are subjected to pay a mandatory charge of IRR 4,000,000 per Article. This charge covers expenses for peer review, journal publication, and online hosting and archiving. The charge form will be sent to the corresponding author on acceptance of an article for publication in the journal. Please be advised the publication of the accepted manuscripts is dependent upon payment of the charge. To facilitate the payment of paid articles, from July 26, 2020, the journal online system was equipped with an electronic payment gateway. Dear Authors, by referring to their profile in the journal online system and click the payment section, they can pay through the payment portal and send the image of the payment receipt.

Manuscripts that are accepted for publication in the Iranian Veterinary Journal are subjected to pay a mandatory charge of IRR 4,000,000 per Article. This charge covers expenses for peer review,

## Evaluation of epidemiological and clinical findings of canine hyperadrenocorticism in Iran

Mohammad Asadi Iraee<sup>1</sup>, Reza Avizeh<sup>2\*</sup>, Mohammad Razijalali<sup>2</sup>  
and Mahdi Pourmahdi Borujeni<sup>3</sup>

<sup>1</sup> DVSc Student of Small Animal Internal Medicine, Faculty of Veterinary Medicine, Shahid Chamran University of Ahvaz, Ahvaz, Iran

<sup>2</sup> Professor, Department of Clinical Sciences, Faculty of Veterinary Medicine, Shahid Chamran University of Ahvaz, Ahvaz, Iran

<sup>3</sup> Professor, Department of Food Hygiene, Faculty of Veterinary Medicine, Shahid Chamran University of Ahvaz, Ahvaz, Iran

Received: 05.09.2022

Accepted: 03.11.2022

### Abstract

Hyperadrenocorticism (HAC), also known as Cushing's syndrome, is caused by chronic exposure to excessive glucocorticoids. The objective of this study was to determine the epidemiological and clinical (especially ophthalmic) findings of dogs with HAC to increase recognition of suspicious cases in clinical routines. This study was examined on thirty dogs from Tehran, Mazandaran, and Guilan provinces between April 2021 and May 2022. The dogs included in the current study, who all had confirmed Hyperadrenocorticism, were selected based on the clinical findings suggestive Cushing disease as well as positive low-dose dexamethasone-suppression test. Then, general information, clinical signs, and ophthalmic factors were examined and recorded. The data were analyzed using the Chi-square test, Fisher's exact test, McNemar test, independent samples t-test, one-way ANOVA and LSD post hoc test. The mean age for the dogs with HAC was 9.7 years. The risk of HAC was also higher in neutered than intact dogs and also in terrier breed than other ones. Furthermore, significant differences were statistically observed concerning ophthalmic evaluations, including eye lesions, palpebral reflex, ophthalmic structural disorders, conjunctival, sclera, lens, retina, iris, and optic nerve involvement. However, gender, breed, common clinical manifestations, behavioural status, PLR test, menace test, dazzle test, cotton test, and corneal involvement did not show significant differences statistically. It was concluded that indoor and gonadectomized dogs had higher frequency in the studied population. We conducted epidemiological and clinical study of Cushing's disease in dogs in Iran, and for the first time, we examined the eye factors associated with this syndrome. These results support a better understanding of the canine hyperadrenocorticism in Iran. According to this study, the studied population resembles the profile described in European and North American epidemiologic studies, and the clinical picture of the HAC dog appears to be similar worldwide.

**Key words:** Polyuria, Polydipsia, Hyperadrenocorticism, Dog, Eye

### Introduction

Hyperadrenocorticism (HAC), is characterized by chronic exposure to high levels of glucocorticoids (Gilor and Graves, 2011; Martins et al, 2019). This disorder is

commonly referred to as Cushing's syndrome, named after Harvey Cushing, a Boston neurosurgeon who first identified HAC in humans in 1932 (Galac, 2010). In

\* **Corresponding Author:** Reza Avizeh, Professor, Department of Clinical Sciences, Faculty of Veterinary Medicine, Shahid Chamran University of Ahvaz, Ahvaz, Iran  
E-mail: [avizeh@scu.ac.ir](mailto:avizeh@scu.ac.ir)



small animal practice, Cushing's syndrome is one of the more common endocrinopathies (Carotenuto et al, 2019). Excess glucocorticoids lead to physical and biochemical changes that significantly affect the animal's quality of life. Hypercortisolism generally results from pathological overproduction of adrenocorticotrophic hormone (ACTH) by either a functional pituitary tumor (PDH, pituitary-dependent hypercortisolism) or a primary adrenal disorder (ADH, adrenal-dependent hypercortisolism) (Behrend, 2010; Carotenuto et al, 2019). Other causes such as ectopic ACTH secretion or food-dependent hypercortisolemia have been reported in dogs; however, these conditions seem rare (Carotenuto et al, 2019; Castillo et al, 2014). In older dogs and certain breeds such as Miniature Poodles, Boxers, and Dachshunds, there appears to be a significant predisposition to HAC (Burkhardt et al, 2013; Fracassi et al, 2015; Martins et al, 2019; Van Rijn et al, 2016). Researchers have reported a potential predisposition for female dogs in some studies (Carotenuto et al, 2019; Gallelli et al, 2010; Wood et al, 2007). Most clinical manifestations occur slowly and gradually. Among these manifestations, polyuria, polydipsia, polyphagia, and abdominal enlargement are notable. On the other hand, ocular complications are common in animals with endocrine disease. Regarding laboratory findings, stress leukograms, alkaline phosphatase activity increases, and hypertriglyceridemia is prominent (Behrend, 2015). The diagnosis is based on the patient's history, a clinical evaluation, imaging studies, and hormonal tests, including the Low-Dose Dexamethasone Suppression Test (LDDST) and the ACTH stimulation test (Behrend et al, 2013). A variety of therapeutic options, including surgical and pharmacological treatments are available. The HAC etiologic classification determines the therapeutic approach since most pituitary neoplasms are treated with medications, in contrast to adrenal

neoplasms, which are treated with adrenalectomy as the first-line treatment. The prognosis of canine HAC varies depending on the severity of the condition and its comorbidities (Behrend, 2015). Several epidemiological studies were conducted on Cushing's disease, the factors affecting the development of this disease, as well as investigating the symptoms caused by this disease in different countries (Barker et al, 2005; Burkhardt et al, 2013; Carotenuto et al, 2019; Fracassi et al, 2015; Gallelli et al, 2010; O'Neill et al, 2016; Van Rijn et al, 2016).

The objective of this study was to determine the epidemiological, clinical, and ophthalmological findings in dogs with HAC to increase recognition of suspicious cases in clinical routines. This is the first epidemiological study conducted on Cushing's disease in dogs in Iran. Moreover, this study evaluated the eye factors caused from the syndrome for the first time.

## Material and methods

In this study, forty one dogs, suspected to have Cushing's disease were studied between April 2021 and May 2022. Several clinical symptoms, including polydipsia, polyuria, polyphagia, abdominal enlargement and hair loss were associated with these dogs. These features are clinical signs of Cushing's syndrome (Nelson and Couto, 2020). The dogs were randomly selected from the three provinces of Tehran, Mazandaran, and Guilan and referred to one of the well-equipped clinics in Tehran province following prior coordination for a definitive diagnosis. First, we performed the disease confirmation test using the LDDST in suspicious dogs. To conduct this test, the blood was taken from the cephalic vein (at zero time), and dexamethasone (Darou Pakhsh Co.) was injected intravenously at a 0.01 mg/kg dose. Additionally, 4 hours (first time) and 8 hours (second time) after dexamethasone injection, some blood was collected again from the cephalic vein, and the amount of



cortisol was measured (Nelson and Couto, 2020). Dogs with hypothyroidism, liver failure, diabetes mellitus, and chronic kidney disease and/or dogs being treated with glucocorticoids, phenobarbital and furosemide were excluded from the study. Based on the results of diagnostic tests and clinical symptoms, only 30 of the 41 dogs used to this study had Cushing's disease. Then, all of the information regarding the dogs, such as their age, sex, breed, neutered or intact status, place of life (indoor or outdoor), referring provinces, and clinical signs such as polydipsia, polyuria, polyphagia, abdominal enlargement, muscle weakness, skin disorders, alopecia, panting, behavioral status like anxiety, memory dysfunction, depression, disorientation and ophthalmic signs, was recorded in the prepared forms in advance. The ophthalmic factors were examined via a slit lamp examination, followed by intraocular pressure (IOP) measures, tear secretion, neurological eye tests, and tear break-up time (TBUT). Using a slit lamp device, eyelids, conjunctiva, cornea, iris, sclera, lens, retina and optic nerve were measured and classified into normal and abnormal. The eye pressure in both eyes was measured using a digital tonometer (iCare TONOVET), generally between 15 and 25 mmHg in normal dogs (Maggs, 2016). We also recorded the amount of tear secretion after sixty seconds in both eyes using a Schirmer tear test (STT) strip (ERC Schirmer tear test strip Co.) without using an anesthetic drug. In normal dogs, the standard amount of tear secretion is 15-25 mm in 60 seconds (Maggs, 2016). To maintain similar conditions, all STTs were

conducted in the morning (from 9:00 am to 1:00 pm), and for all measurements, the same brand of Schirmer paper was used to eliminate probable errors. In order to measure eye nerves and the animal's vision, several neurological tests, including Pupillary Light Reflex (PLR), Palpebral Reflex (PR), menace reflex and cotton ball were conducted. Another test was the TBUT, which measured the tear film break-up time. In this test, the eye's corneal surface was first stained with a fluorescein strip (Elham Teb Co.); then, after blinking the eye two to three times with our own hands, a time was recorded until the first dry spot appeared on the cornea. For normal dogs, this time is greater than 20 seconds (Maggs, 2016).

The data were analyzed using the Chi-square test, Fisher's exact test, McNemar test, independent samples t-test, one-way ANOVA and LSD post hoc test. As a result, the differences were considered statistically significant ( $P \leq 0.05$ ).

## Results

The overall data consisted of 41 dogs attending three provinces in Iran between April 2021 and May 2022. Based on the history, clinical findings, and positive results of the LDDS test, 30 dogs (73.17%) were identified with HAC. The distribution of percentages of cases is shown by frequency and place of life in Figure 1 .

According to the number of cases referred, the prevalence of dogs with HAC in indoor living locations was almost four times greater than that in outdoor living spaces, indicating a statistically significant difference ( $p < 0.001$ ) (Figure 1).

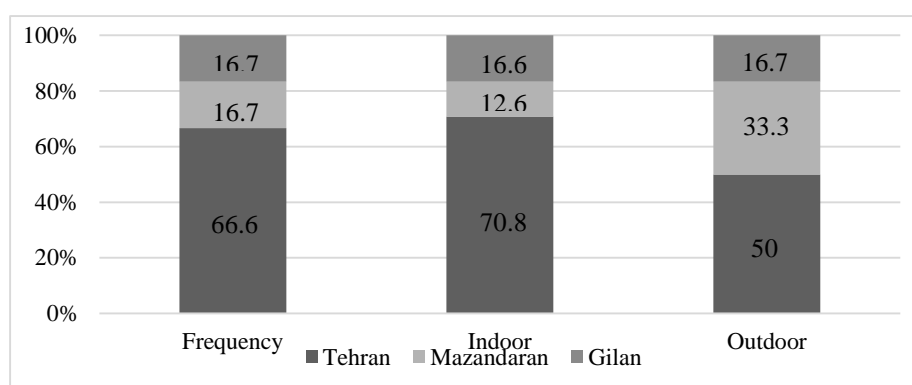


Figure 1. Dog percentage distribution with HAC according to the frequency and location of life

Only thirty out of forty one dogs with HAC had information regarding their age. The mean ( $\pm$  SD) age for dogs with HAC was  $9.7 (\pm 1.9)$  years, and only 3 of 30 dogs (10%) were less than 8 years old. For all 30 dogs with HAC, gender data (Figure 2) were also available. Female dogs appeared to be at a higher risk for HAC than males but the difference was not significant ( $p > 0.05$ ). In addition, neutered dogs had a

higher risk of HAC than intact dogs, which had a statistically significant difference ( $p < 0.05$ ) (Figure 2).

Among 30 dogs with HAC admitted to the three provinces during the study period, in spite of the existence of differences between breeds, no statistically significant differences were observed ( $p > 0.05$ ) (Table 1).

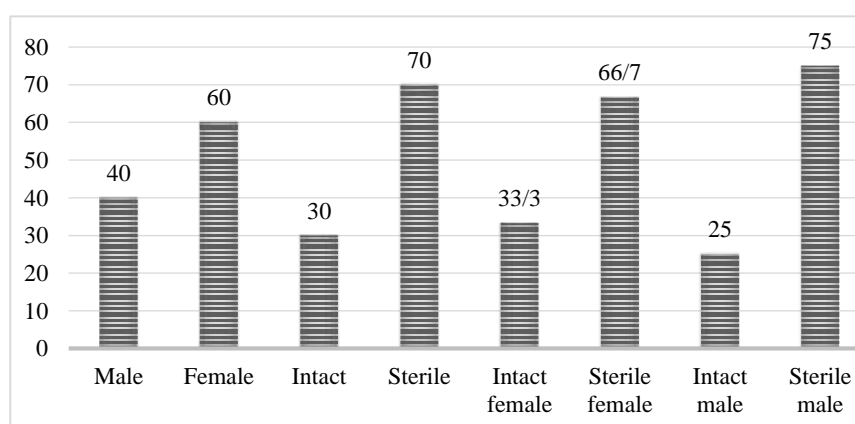


Figure 2. Distribution percentage of sex status's in dogs with HAC

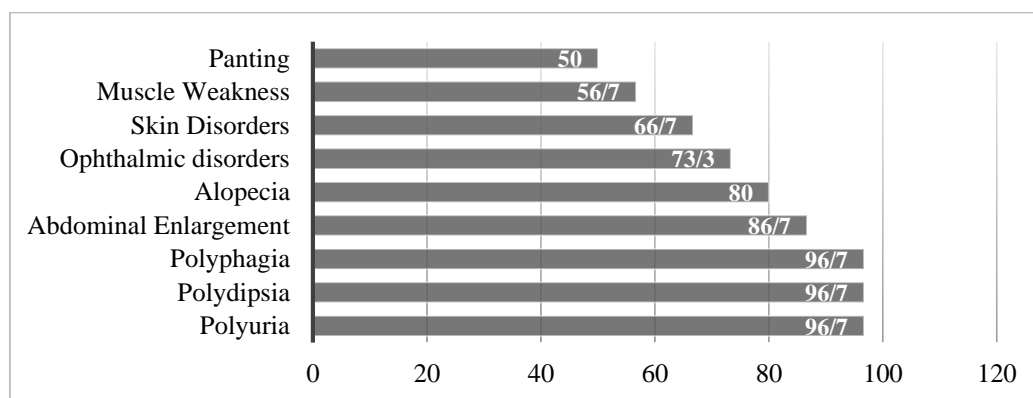
Table 1. Breed distribution of dogs with HAC in three provinces of Tehran, Mazandaran, Guilan

Breed	Frequency	Percentage
Boxer	3	10
German shepherd	4	13.3
Crossbred	4	13.3
Pomeranian	6	20
Poodle	4	13.3
Shih Tzu	2	6.7
Terrier	7	23.3
Total	30	100

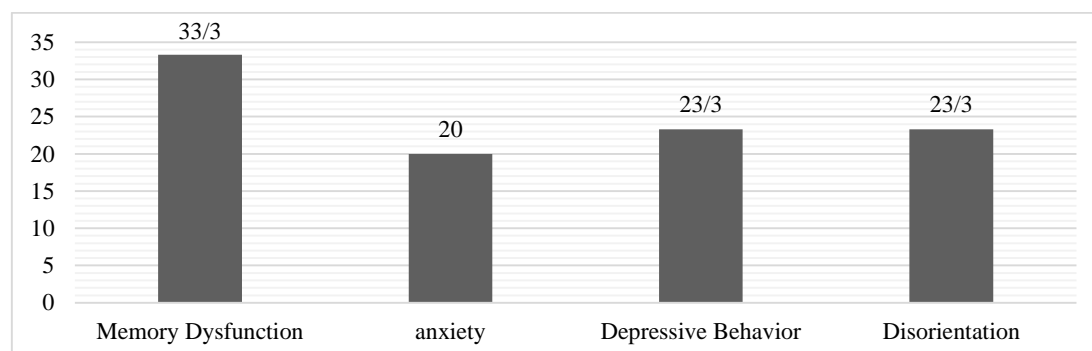
A summary of the most common clinical manifestations in this case series is shown in Figure 3. As is shown, polyuria, polydipsia, and polyphagia were observed in most cases. Additionally, other clinical symptoms with no significant difference were abdominal enlargement, alopecia,

ophthalmic disorders, skin disorders, muscle weakness, and panting ( $p>0.05$ ).

According to Figure 4, dogs with HAC showed memory dysfunction, anxiety, depressive behavior, and disorientation; however, no significant difference was found. ( $p>0.05$ ).



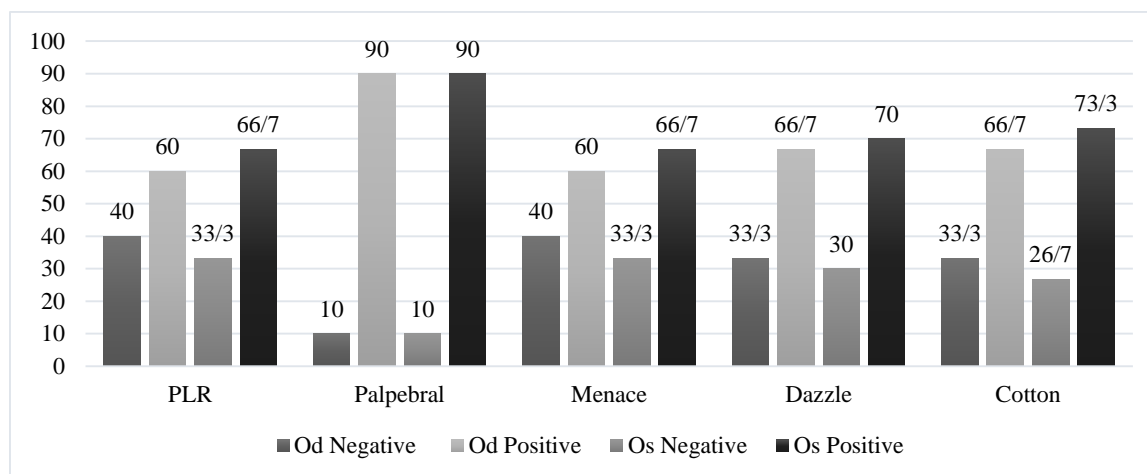
**Figure 3. Distribution percentage of clinical manifestation's in dogs with HAC in three provinces of Tehran, Mazandaran, Guilan**



**Figure 4. Distribution percentage of behavioural status's in dogs with HAC in three provinces of Tehran, Mazandaran, Guilan**

According to this study, most cases had at least one ocular lesion, indicating a significant difference ( $p<0.05$ ). A description of the neurological eye tests in this case series is illustrated in figure 5 in which a negative result of this test indicates an unhealthy eye and a positive result indicates a healthy eye. Regarding the PLR test, although positive PLR was higher than negative in both the oculus dextrus (OD) and oculus sinister (OS), these differences were not statistically significant ( $p>0.05$ ). Additionally, in the palpebral test, positive results were approximately nine times greater than negative results in both OD and

OS, indicating a statistically significant difference ( $p>0.05$ ). Furthermore, according to the menace test, despite the discrepancies between the positive and negative results, the difference between OD and OS was not statistically significant ( $p>0.05$ ). Moreover, the dazzle test showed a greater proportion of positivity than negativity in OS and OD; however, this was not statistically significant ( $p>0.05$ ). Additionally, although the positive results were higher than the negative ones in OS and OD, no statistically significant differences were observed ( $p>0.05$ ).

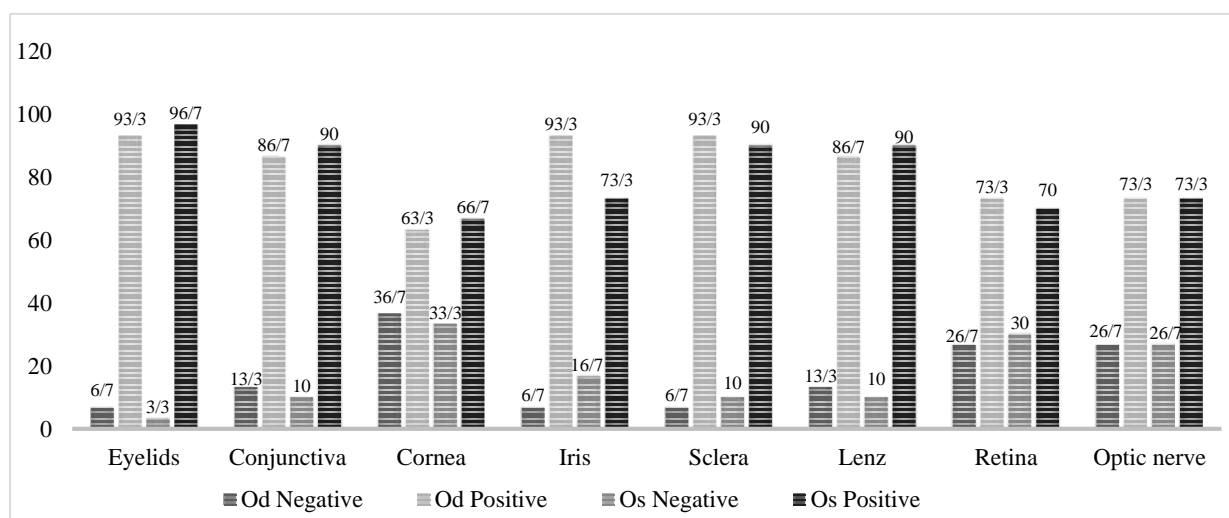


**Figure 5. Distribution of ophthalmic neurological tests in dogs with HAC in three provinces of Tehran, Mazandaran, Guilan. PLR: Pupillary light reflex, Od: oculus dextrus, Os: oculus sinister**

In the structural study of the eyes, negative indicates a healthy structure, while positive indicates an unhealthy one. Among dogs with HAC and ophthalmic structure disorders, eyelid involvement was significant both in OS and OD ( $p < 0.05$ ). Moreover, the number of healthy eyes among dogs with HAC was statistically significantly lower than the number of eyes that had conjunctival involvements ( $p < 0.05$ ). Additionally, regarding corneal involvement, no significant differences were observed ( $p > 0.05$ ). In contrast, the results of the positive tests were significantly greater than those of the negative tests based on the involvement of the iris ( $p < 0.05$ ). In addition, in terms of

sclera involvement, the positive results were significantly more than negative ones in both eyes ( $p < 0.05$ ). The results of the lens lesions were such that 13.3% of the right eye and 10% of the sinister eye were negative, indicating a statistically significant difference ( $p < 0.05$ ). Additionally, more eyes with retinal involvement were observed in OD and OS, which was statistically significant ( $p < 0.05$ ). Finally, optic nerve involvement was highly prevalent in dogs with HAC, indicating a significant difference ( $p < 0.05$ ) (figure 6).

In terms of IOP, TBUT, and STT, the mean values for Od were lower than those for Os, which was statistically significant ( $p < 0.001$ ) (table 2).



**Figure 6. Ophthalmic structure disorders in dogs with HAC in three provinces of Tehran, Mazandaran, Guilan. Od: oculus dextrus, Os: oculus sinister**

**Table 2. Mean values, standard deviation, range, and reference interval for the IOP, TBUT, STT in dogs with HAC in three provinces of Tehran, Mazandaran, Guilan. Od: oculus dextrus, Os: oculus sinister**

Parameters	Mean (standard deviation)		Range		Reference range
	Od	Os	Od	Os	
IOP	18.86 ( $\pm 2.64$ )	19.06 ( $\pm 3.15$ )	9.00	10.00	15-25
TBUT	22.76 ( $\pm 6.59$ )	23.70 ( $\pm 7.20$ )	22	24	20s<
STT	17.70 ( $\pm 5.01$ )	17.73 ( $\pm 5.39$ )	18	18	15-25

## Discussion

An accurate clinical-epidemiological profile contributes to the development of a diagnosis. Thus, it is essential to determine the clinical and epidemiological aspects of diseases. During the present study, classic disease presentations were observed, with well-defined clinical findings; however, clinical manifestations were discreet in some patients. These cases did not present alterations considered to be frequent such as polyuria and polyphagia. Despite all the advances in technology and methodology regarding hormonal analysis, clinical aspects and complementary exams are essential to determining the diagnosis (Behrend, 2015; Benchekroun et al, 2010; Martins et al, 2019).

During the period between April 2021 and May 2022, this rate of involvement was determined by suspected cases with clinical symptoms, not from all cases referred to clinics, which differs from a study of 119 primary-care veterinary practices in the United Kingdom that estimated the prevalence of HAC involvement in all referred cases (not suspicious cases with clinical symptoms) (O'Neill et al, 2016). In addition, 80% of indoor dogs had HAC, which may have been caused by different factors than outdoor dogs. It is due to several factors, such as the referral of more indoor dogs to clinics and the lack of supervisors to monitor the health and treatment of outdoor dogs. There is, however, a possibility that the incidence of this disease may be the same in both forms of living. In contrast, increased exposure to endocrine disruptors, such as food

contaminants (Koestel et al, 2017), toys, or plastic utensils, may also be contributing factors (Wooten and Smith, 2013). Such substances interfere with several physiological mechanisms, from the inhibition of hormone synthesis, that happens with lindane reducing StAR protein expression, and decreasing steroidogenesis, to steroid receptors binding, altering the process of transduction, signalling, and modulating enzymatic pathways in the metabolism of sexual hormones (for example, analogues of dichlorodiphenyltrichloroethane) (Koestel et al, 2017; Martins et al, 2019; Wooten and Smith, 2013).

In the present study, the age of diagnosis of this syndrome was 9.7 ( $\pm 1.9$ ) years, which was consistent with the age mentioned (approximately 9–11 years) in other studies (Barker et al, 2005; Burkhardt et al, 2013; Carotenuto et al, 2019; Fracassi et al, 2015; Gallelli et al, 2010; O'Neill et al, 2016; Van Rijn et al, 2015).

Research has consistently shown that HAC occurs more often in female dogs (Gallelli et al, 2010; Pöpl et al, 2016; Reusch and Feldman, 1991). However, there was no consensus regarding the existence of a gender predisposition over time. HAC was also more prevalent in female dogs in the present evaluation. On the other hand, in another study, ACTH-dependent HAC was more prevalent in female dogs. In contrast, ACTH-independent HAC was more prevalent in male dogs (Martins et al, 2019). Regarding reproductive health, studies have not shown

a higher incidence of HAC diagnosis in gonadectomized dogs (O'Neill et al, 2016). Despite this, Belanger et al (2017) found that gonadectomy was significantly associated with a higher risk of developing HAC in both males and females. Based on the results of the current study, HAC seems to be associated with gender. Furthermore, neutered dogs had a higher risk than intact ones and neutered females had a higher risk than intact females, which is in agreement with Peterson (2007), who states that females are more predisposed to developing HAC because of the interaction between female sexual hormones and the hypothalamic-pituitary axis. The only environmental risk factor identified in studies on canine HAC was gonadectomy in female patients (Martins et al, 2019).

Dachshunds, Terriers, and Boxers have been identified to have a significantly higher risk of developing HC. Similar conclusions were also reached by many other studies (Bell et al., 2006; Burkhardt et al, 2013; Carotenuto et al, 2019; Fracassi et al, 2015; Hanson et al, 2007; Helm et al, 2011; O'Neill et al, 2016; Rodriguez Piñeiro et al, 2011; Van Rijn et al, 2015, 2016). This finding has been confirmed and reinforced in the present study. According to this study, the terrier had the highest percentage (23.3%), although this breed had been associated with much lower risks in other studies (Carotenuto et al, 2019; Fracassi et al, 2015; Hanson et al, 2007; Helm et al, 2011; O'Neill et al, 2016; Van Rijn et al, 2016). In contrast, breeds like Pomeranian, included in this study, have not been found to have a significant risk difference; for example, O'Neill et al. (2016) reported an elevated risk for Bichon Frisé, which was not included in this study. The reason for the differences between the results of our study and those of other previously published reports may be the result of either the different distribution/representation of canine breeds in different geographical areas or the defining features of other studies that did

not take into account the prevalence of different breeds. Even though there are overlaps among the studies, none examines the same breeds. In our study, we found a high risk in the Pomeranian (20%), a breed that was not described as predisposed in other studies (Carotenuto et al, 2019; Fracassi et al, 2015; Hanson et al, 2007; Helm et al, 2011; O'Neill et al, 2016; Van Rijn et al, 2016).

According to O'Neill et al (2016), large breed dogs present a lower risk of developing ACTH-dependent HAC than small breed ones. In the formation and maintenance of modern breeds, selective pressure may have led to significant changes in size and muscle mass due to the diversity among dog breeds. Medium and small-sized dogs were more HAC affected, which could be explained by data from a study that compared gene expression among dog sizes, identifying variants regarding a lower expression of IRS-4, IGSF-1 and ACSL-4 in small and medium-sized dogs (Martins et al, 2019; Plassais et al, 2017). Similarly, most dogs suffering from HAC syndrome in this study were small. There is evidence that such substrates are essential in pituitary development (Martins et al, 2019; Wang et al, 2017) and steroidogenesis (Martins et al, 2019; Midzak and Papadopoulos, 2016), which may explain the correlation between the occurrence of HAC and size.

Based on the results of the present study, the main clinical manifestations of HAC are classified as frequent, less frequent, and infrequent. However, a greater understanding of this endocrinopathy has identified subtle clinical signs. Besides, more classic manifestations in this study, led to less frequent ones such as skin disorders, muscle weakness and panting. There are also infrequent ones, such as abdominal enlargement, alopecia, and ophthalmic disorders. Additionally, polyuria, polydipsia, and polyphagia were frequent symptoms. In other studies, less frequent signs such as lethargy/apathy,

hyperpigmentation, comedones, pyoderma, poor hair regrowth and infrequent ones, such as thromboembolism, ligament ruptures, facial nerve paralysis, cutis calcinosis, testicular atrophy, myopathy and persistent anestrus were observed (Behrend, 2010; Martins et al, 2019).

Furthermore, Notari et al (2016) suggest that previous experience with glucocorticoids may be associated with behavior problems caused by fear, anxiety, and frustration. A study of the adverse effects of HAC on behavior and cognition in dogs is imperative since these changes constantly impair the dog-owner relationship; that is, owners can consider when making treatment decisions. In this study, memory dysfunction was associated with a higher risk (33.3%) than depressive behavior (23.3%), disorientation (23.3%), and anxiety (20%), correlating to da Silva et al (2007) stating that dogs with HAC exhibited a higher final score of cognitive dysfunction, specifically, higher memory dysfunction. Hypercortisolism appears to accelerate neurodegenerative processes, leading to more intense behavioral and cognitive changes than observed in age-matched dogs without HAC. There is, however, a lack of studies in veterinary medicine on the effects of chronic hypercortisolism on dog cognition and behavioral symptoms that might be associated with HAC.

Several ocular abnormalities were observed in the structural disorders and neurological tests of this study. Approximately 73% of all eyes were affected by one or more abnormalities, which is a significant number. However, some of these abnormalities, such as cataracts, are linked to ageing in dogs. On

the other hand, the left eye is more involved in neurological tests than the right eye, for which no specific reason can be identified. In another study, ocular abnormalities were found in both hyperthyroid and euthyroid cats, with approximately 75% of all eyes affected (Van der Woerd and Peterson, 2000). According to the results of the STT and TBUT tests, there is an increase in IOP and eye dryness associated with this disease.

Nevertheless, this is the first epidemiological, clinical, and ophthalmological study on canine HAC in Iran. This study concludes that the profile of the population studied resembles that described in European epidemiologic researches, and the clinical picture of the HAC dog across the globe is similar. This clinicopathological characterization of the north and central Iranian population contributes to a better understanding of this challenging and frequent disease in Iran. In the presence of vague clinical signs or minor laboratory or ultrasound abnormalities that are compatible with HAC, special attention should be paid. Because dogs have a longer life expectancy and are more likely to be diagnosed with HAC when they are young, it is beneficial to know how local cases of HAC behave in contrast to international literature to support accurate diagnosis in clinical routine. In addition, unusual HAC-associated signs are likely to appear in some dogs more prominently than the clinical signs of classic HAC. It is essential to recognize the vast range of clinicopathological abnormalities secondary to this endocrine disease in order to improve suspicion and investigation of HAC.

### Acknowledgments

The authors express their gratitude to the Research Council of Shahid Chamran University of Ahvaz for its financial support.

### Conflict of interest

The authors declare that they have no known conflict of interest.

## Funding

This research was carried out in the form of a thesis with the financial support of Shahid Chamran University of Ahvaz.

## References

- Barker, E. N., Campbell, S., Tebb, A. J., Neiger, R., Herrtage, M. E., Reid, S. W., & Ramsey, I. K. (2005). A comparison of the survival times of dogs treated with mitotane or trilostane for pituitary-dependent hyperadrenocorticism. *Journal of Veterinary Internal Medicine*, 19(6): 810-815.
- Behrend, E.N. (2015). *Canine and feline endocrinology* (4th ed., pp. 377-444). St Louis, SL: W.B. Saunders.
- Behrend, E. N., Kooistra, H. S., Nelson, R., Reusch, C. E., & Scott-Moncrieff, J. C. (2013). Diagnosis of spontaneous canine hyperadrenocorticism: 2012 ACVIM consensus statement (small animal). *Journal of Veterinary Internal Medicine*, 27(6): 1292-1304.
- Belanger, J. M., Bellumori, T. P., Bannasch, D. L., Famula, T. R., & Oberbauer, A. M. (2017). Correlation of neuter status and expression of heritable disorders. *Canine Genetics and Epidemiology*, 4(1): 6.
- Bell, R., Neiger, R., McGrotty, Y., & Ramsey, I. K. (2006). Study of the effects of once daily doses of trilostane on cortisol concentrations and responsiveness to adrenocorticotrophic hormone in hyperadrenocorticoid dogs. *The Veterinary Record*, 159(9): 277-281.
- Benchenkroun, G., de Fornel-Thibaud, P., Rodríguez Piñeiro, M. I., Rault, D., Besso, J., Cohen, A., Hernandez, J., Stambouli, F., Gomes, E., Garnier, F., Begon, D., Maurey-Guenec C., & Rosenberg, D. (2010). Ultrasonography criteria for differentiating ACTH-dependency from ACTH independency in 47 dogs with hyperadrenocorticism and equivocal adrenal asymmetry. *Journal of Veterinary Internal Medicine*, 24(5): 1077-1085.
- Burkhardt, W. A., Boretti, F. S., Reusch, C. E., & Sieber-Ruckstuhl, N. S. (2013). Evaluation of baseline cortisol, endogenous ACTH, and cortisol/ACTH ratio to monitor trilostane treatment in dogs with pituitary-dependent hypercortisolism. *Journal of Veterinary Internal Medicine*, 27(4): 919-923.
- Carotenuto, G., Malerba, E., Dolfini, C., Brugnoli, F., Giannuzzi, P., Semprini, G., & Fracassi, F. (2019). Cushing's syndrome an epidemiological study based on a canine population of 21,281 dogs. *Open Veterinary Journal*, 9(1): 27-32.
- Castillo, V. A., Pessina, P. P., Garcia, J. D., Hall, P., Gallelli, M. F., Miceli, D. D. & Cabrera Blatter, M. F. (2014). Ectopic ACTH syndrome in a dog with a mesenteric neuroendocrine tumour: a case report. *Veterinary Medicina*, 59(7): 352-358.
- Da Silva, C. C., Cavalcante, I., de Carvalho, G. L. C. & Pöppel, Á. G. (2021). Cognitive dysfunction severity evaluation in dogs with naturally-occurring Cushing's syndrome: A matched case-control study. *Journal of Veterinary Behavior*, 46: 74-78.
- Fracassi, F., Corradini, S., Floriano, D., Boari, A., Aste, G., Pietra, M., Bergamini, P. F. & Dondi, F. (2015). Prognostic factors for survival in dogs with pituitary-dependent hypercortisolism treated with trilostane. *The Veterinary Record*, 176(2): 49-55.
- Galac, S. (2010). Recent developments in canine Cushing's syndrome. Utrecht Universiteit Utrecht, Faculteit Diergeneeskunde Thesis Universiteit Utrecht. - With ref. - With summary in Dutch and Slovene. 1, 978.
- Gallelli, M. F., Cabrera M. F. B. & Castillo V. (2010). A comparative study by age and gender of the pituitary adenoma and ACTH and alpha-MSH secretion in dogs with pituitary-dependent hyperadrenocorticism. *Research in Veterinary Science*, 88(1): 33-40.
- Gilor, C. & Graves T. K. (2011). Interpretation of laboratory test for canine Cushing's syndrome. Topics in *Companion Animal Medicine*, 26(2): 98-108.
- Hanson, J. M., Teske, E., Voorhout, G., Galac, S., Kooistra, H. S. & Meij, B. P. (2007). Prognostic factors for outcome after transsphenoidal hypophysectomy in dogs with pituitary-dependent hyperadrenocorticism. *Journal of Neurosurgery*, 107(4): 830-840.
- Helm, J. R., Mclauchlan, G., Boden, L. A., Frowde, P. E., Collings, A. J., Tebb, A. J., Elwood, C. M., Herrtage, M. E., Parkin, T. D. & Ramsey, I. K. (2011). A comparison of factors that influence survival in dogs with adrenal-dependent hyperadrenocorticism treated with mitotane or trilostane. *Journal of Veterinary Internal Medicine*, 25(2): 251-260.



- Koestel, Z. L., Backus R. C., Tsuruta, K., Spollen, W. G., Johnson S. A., Javurek, A. B., Ellersieck, M. R., Wiedmeyer, C. E., Kannan, K., Xue, J., Bivens, N. J., Givan, S. A. & Rosenfeld, C. S. (2017). Bisphenol A (BPA) in the serum of pet dogs following short-term consumption of canned dog food and potential healthconsequences of exposure to BPA. *The Science of the Total Environment*, 579: 1804-1814.
- Lane, IF., Roberts, S. T. & Lappin, M. R. (1993). Ocular manifestations of vascular disease: Hypertension, hyperviscosity, and hyperlipidemia. *Journal of American Animal Hospital Association*, 29: 28-36.
- Maggs, D. J., Miller, P., & Ofri, R. (2016). *Slatter's Fundamentals of Veterinary Ophthalmology* (6th ed., pp. 79-109). St Louis, SL: W.B. Saunders.
- Martins, F. S., Carvalho, G. L. C., Jesus, L., Pöpl, Á. G., & González, F. H. (2019). Epidemiological, clinical, and laboratory aspects in a case series of canine hyperadrenocorticism: 115 cases (2010-2014). *Pesquisa Veterinária Brasileira*, 39(11): 900-908.
- Midzak, A. & Papadopoulos, V. (2016). Adrenal mitochondria and steroidogenesis: from individual proteins to functional protein assemblies. *Frontiers in Endocrinology*, 7: 106.
- Nelson, R. W. and Couto, C. G. (2020). *Small Animal Internal Medicine* (6th ed., pp. 857-897). St Louis, SL: Elsevier.
- Notari, L., Burman, O. & Mills, D. S. (2016). Is there a link between treatments with exogenous corticosteroids and dog behavior problems?. *The Veterinary Record*, 179(18): 462-467.
- O'Neill, D. G., Scudder, C., Faire, J. M., Church, D. B., McGreevy, P. D., Thomson, P. C. & Brodbelt, D. C. (2016). Epidemiology of hyperadrenocorticism among 210,824 dogs attending primary-care veterinary practices in the UK from 2009 to 2014. *The Journal of Small Animal Practice*, 57(7): 365-373.
- Peterson, M. E. (2007). Diagnosis of hyperadrenocorticism in dogs. *Clinical Techniques in Small Animal Practice*, 22(1): 2-11.
- Plassais, J., Rimbault M., Williams F. J., Davis B.W., Schoenebeck J. J. & Ostrander E. A. (2017). Analysis of large versus small dogs reveals three genes on the canine X chromosome associated with body weight, muscling and back fat thickness. *PLoS Genetics*, 13(3), e1006661.
- Pöpl, A. G., Coelho, I. C., Silveira, C. A., Moresco, M. B., & Carvalho, G. L. C. (2016). Frequency of endocrinopathies and characteristics of affected dogs and cats in southern Brazil (2004-2014). *Acta Scientiae Veterinariae*, 44(1): 1379.
- Reusch, C. E., & Feldman, E. C. (1991). Canine hyperadrenocorticism due to adrenocortical neoplasia: pretreatment evaluation of 41 dogs. *Journal of Veterinary Internal Medicine*, 5(1): 3-10.
- Rodriguez Piñeiro, M. I., De Fornel-Thibaud, P., Benchekroun, G., Garnier, F., Maurey-Guenec, C., Delisle, F., & Rosenberg, D. (2011). Use of computed tomography adrenal gland measurement for differentiating ACTH dependence from ACTH independence in 64 dogs with hyperadrenocorticism. *Journal of Veterinary Internal Medicine*, 25(5): 1066-1074.
- Van der Woerd, A. & Peterson, M. E. (2000). Prevalence of ocular abnormalities in cats with hyperthyroidism. *Journal of Veterinary Internal Medicine*, 14(2): 202-203.
- Van Rijn, S. J., Galac, S., Tryfonidou, M. A., Hesselink, J. W., Penning, L. C., Kooistra, H. S., & Meij, B. P. (2016). The influence of pituitary size on outcome after transsphenoidal hypophysectomy in a large cohort of dogs with pituitary-dependent hypercortisolism. *Journal of Veterinary Internal Medicine*, 30(4): 989-995.
- Van Rijn, S. J., Hanson, J. M., Zierikzee, D., Kooistra, H. S., Penning, L. C., Tryfonidou, M.A., & Meij, B. P. (2015). The prognostic value of perioperative profiles of ACTH and cortisol for recurrence after transsphenoidal hypophysectomy in dogs with corticotroph adenomas. *Journal of Veterinary Internal Medicine*, 29(3): 869-876.
- Wang, Y., Brûlé, E., Silander, T., Bak, B., Joustra, S. D., & Bernard D. J. (2017). The short mRNA isoform of the immunoglobulin superfamily, member 1 gene encodes an intracellular glycoprotein. *PLoS One*, 12(7): e0180731.
- Wood, F. D., Pollard, R. E., Uerling, M. R. Feldman, E.C. (2007). Diagnostic imaging findings and endocrine test results in dogs with pituitary-dependent hyperadrenocorticism that did or did not have neurologic abnormalities: 157 cases (1989– 2005). *Journal of the American Veterinary Medical Association*, 231(7): 1081-1085.
- Wooten, K. J., & Smith, P. N. (2013). Canine toys and training devices as sources of exposure to phthalates and bisphenol A: quantitation of chemicals in leachate and in vitro screening for endocrine activity. *Chemosphere*, 93(10): 2245-2253.

Received: 05.09.2022

Accepted: 03.11.20

## Association between presence of DNA and antibody in the serum during vertical transmission of *Neospora caninum*

Razieh Ayati<sup>1</sup>, Hossein Rezvan<sup>2\*</sup>, Mohammad Mehdi Namavari<sup>3</sup>, Ali Sadeghi-nasab<sup>4</sup>, Sahar Hamoon Navard<sup>5</sup> and Bahram Dadmehr<sup>6</sup>

<sup>1</sup> MSc, Department of Pathobiology, Faculty of Veterinary Science, Bu-Ali Sina University, Hamedan, Iran

<sup>2</sup> Associate Professor, Department of Pathobiology, Faculty of Veterinary Science, Bu-Ali Sina University, Hamedan, Iran

<sup>3</sup> Associate Professor, Razi Vaccine and Serum Research Institute, Shiraz, Iran

<sup>4</sup> Assistant Professor, Department of Clinical Sciences, Faculty of Veterinary Science, Bu-Ali Sina University, Hamedan, Iran

<sup>5</sup> Assistant Professor, Department of Pathobiology, Faculty of Veterinary Science, Bu-Ali Sina University, Hamedan, Iran

<sup>6</sup> Instructor, Department of Basic Sciences, Applied Science Education Center of Farab Amarlou, Jirandeh, Iran

Received: 02.08.2022

Accepted: 14.12.2022

### Abstract

*Neospora caninum* is an intracellular parasite causing abortion and reproductive failure in cattle. The aim of this study was to determine the association between serum parasitemia and seropositivity in cows with no sign of abortion and their full term calves. For this purpose, 49 serum samples of normal full term delivering dairy cattle and their precolostral new born calves were tested by using PCR, nested-PCR and a new developed whole cell-based ELISA. Fourteen of 49 mothers (28.57%) and 6 of 49 calves (12.24%) showed anti-*Neospora* serum antibodies and *Neospora* DNA, concurrently. All infected calves were born from infected mothers and the vertical rate of transmission among all samples was 6 out of 49 (12.24%) and from infected mothers 6 out of 14 (42.84%), based on different serum analyses. Eight out of 14 calves (57.14%) born from infected mothers were *Neospora* free. In conclusion, despite the presence of anti-*Neospora* serum antibodies in infected cows and calves, the parasite was not completely removed from the blood and so it seems that the presence of antibodies is not necessarily a sign of effective immunity.

**Key words:** *Neospora caninum*, Antibodies, DNA

### Introduction

*Neospora caninum* is an obligate intracellular parasite (Dubey, 2003), which is accounted for as a major cause of reproductive failures. During the second and third semester of the pregnancy, the infected animals may deliver either preterm or apparently healthy born (AHB) calves (Dubey and Schares, 2006). As for other pathogenic agents, *Neospora* is recognized

by the fetal immune system and controlled by the fetal immune system; thereafter the abortion decreased after the first trimester transplacental transmission. These pregnant mothers may deliver AHB calves which were vertically infected with the parasite and may pose various pathologic foot prints on the fetal tissues (Dubey, 2003).

\* **Corresponding Author:** Hossein Rezvan, Associate Professor, Department of Pathobiology, Faculty of Veterinary Science, Bu-Ali Sina University, Hamedan, Iran  
E-mail: [h.rezvan@basu.ac.ir](mailto:h.rezvan@basu.ac.ir)



The essential role of AHB calves in keeping and spreading the infection among the population has been discussed in some recent studies. The role of dogs, as the definitive host in industrial livestock is almost controlled; therefore, the main root of transmission for *Neospora* in cattle of industrial farms is congenital (Santos et al, 2012). In these farms, AHB calves remain infected during their whole life transferring the parasite to their offsprings (Nasir et al, 2012).

As a matter of fact, cell-mediated immunity (CMI) plays a major role in protection of *N. caninum* as an obligate intracellular parasite (Guy et al, 2001; Paré et al, 1997; Stenlund et al, 1999). Increased serum antibodies may be used as an indirect indicator of parasite multiplication, whether antibodies can directly influence recrudescence (Guy et al, 2001; Paré et al, 1997; Stenlund et al, 1999). The present study was designed to evaluate the association of anti-*Neospora* antibody and the possible presence of *Neospora* DNA in the serum of pregnant cows and their AHB precolostral calves.

## Materials and Methods

### Samples

Blood samples were obtained from 49 full term pregnant cows immediately after delivery and their AHB calves before receiving their colostrum in an industrial dairy farm. The samples were taken from the jugular vein using venoject plain tubes with no anti-coagulants. The tubes were centrifuged at 1000g for 10 minutes and the sera were collected and kept at -20 until used.

### ELISA

ELISA plates (Biofil, Canada) were coated with  $2 \times 10^6$  *Neospora* tachyzoites per well and incubated at room temperature for 3 days. The plates were washed with a washing buffer containing PBS and 0.05% Tween 20 for three times and blocked with a blocking buffer containing PBS and

marvel milk 5% for 1h at 37°C. The serum samples were loaded onto the ELISA plates in duplicate after a dilution of 1 in 100 in the blocking buffer and incubated at 37°C for 1 h followed by three times washes. A number of serum samples collected from *Neospora* positive cows were used as positive controls and the blocking buffer with no serum was used as the negative control. HRP conjugated sheep anti-bovine IgG-heavy chain antibody (Bethyl, USA) was diluted in PBS (1:1000) containing 5% marvel milk and added to the plates incubating at 37°C for 1 h. After three times washes with the washing buffer, a substrate containing DMSO, TMB 10 µg/ml, sodium acetate 0.1% and hydrogen peroxide 10% (all from Sigma-Aldrich, USA) was added and the plates were incubated again at room temperature for 40 minutes. 2M H<sub>2</sub>SO<sub>4</sub> was used to stop the reaction and the plates was then read at 450nm on a micro-plate ELISA reader (ELX808, Bio Tec, USA). The ratio of sample/positive control (S/P) ODs was calculated according to the following equation.

$$S/P = \frac{\text{sample} - \text{NC}}{\text{PC} - \text{NC}}$$

NC: Negative Control

PC: Positive Control

Samples with the S/P ratio of 0.50 or above were considered as positive for *N. caninum* infection (Hajikolaei, Goraninejad, Hamidinejat, Ghorbanpour, & Paryab, 2007; Yu et al., 2007).

### PCR

*N. caninum* NC5 gene was detected in serum samples using Np6 forward (5'-CTCGCCAGTCAACCTACGTCTTCCT>-3') and Np21 reverse (5'-CCCAGTGCGTCCAATCCTGTAACC>-3') primers (Müller, Zimmermann et al. 1996). The PCR was programmed as 10 minutes at 95°C for primary denaturation and 35 cycles of 95°C for 1 minute, 65°C 1 min and 72°C for 2 minutes and a final extension at 72°C for 10 min.

### Nested-PCR

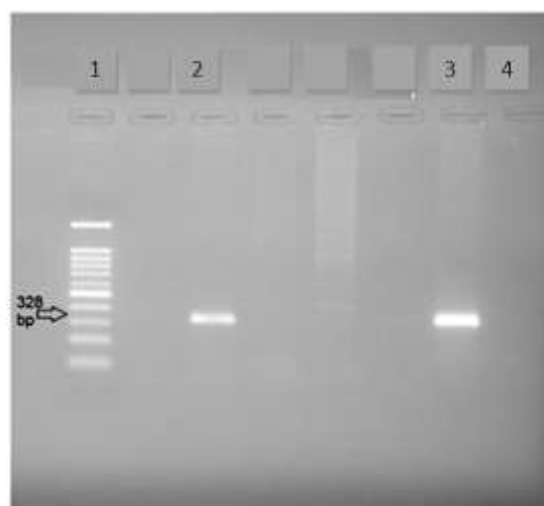
1 µl of the PCR products was subjected to nested-PCR for confirming the presence of *N.caninum* NC5 gene using 5'-GTGTTGCTCTGCTGACGTGT-3' forward and 5'-TACCAACTCCCTCGGTTTCAC-3' reverse primers. The nested PCR was programmed as 10 minutes for primary denaturation at 95°C and 35 cycles of 1 minute at 95°C for denaturation, 45 seconds at 54°C for annealing and 1 minute at 72°C for extension. Finally, the reaction was completed with a final extension at 72°C for 10 minutes.

**Statistical Analysis:** Statistical analysis of the relationship and correlation coefficient between nominal variables was performed by Chi-square and Phi correlation coefficient, respectively. Data normality was checked out by Kolmogorov Smirnov method. Pearson's correlation coefficient was done for s/p data. Data analyses were performed at the  $\alpha=0.05$  level by SPSS 19.0 software (SPSS Inc., Chicago, IL, USA) and MedCalc 20.1.4.


### Results

Anti-*Neospora* antibodies were detectable in 14 mothers (28.57%) and 6 calves (12.24%) (Table 1). A significant positive correlation was observed between the serum ELISA titer (S/P ratio) of mothers and calves ( $r=0.351$ ,  $n=49$ ,  $p\text{-value}=0.013$ ). Cows and new born calves with positive serum PCR showed a high S/P ratio of ELISA titer (Table 3).

Based on PCR and Nested-PCR findings (Figures 1 & 2), there was a significant relationship between maternal and offspring infection ( $r=0.591$ ,  $n=49$ ,  $p\text{-value}=0.000036$ ), (Tables 1 & 2). The rate of vertical transmission was 42.84% (6 infected calves out of 14 infected dams); the overall rate of vertical transmission from all mothers to the infected foetuses was 12.24% (6 infected calves out of 49 total dams). Impressively, some of the calves born from infected mothers were *Neospora* free and all infected calves were born from infected mothers (Table 2). The results of PCR and Nested-PCR were completely consistent with each other.



**Figure 1. Detection of *Neospora caninum* DNA in bovine serum; 1: ladder 2: serum samples 3: positive control (*Neospora* DNA) 4: negative control**



**Figure 2. Confirmation of *Neospora caninum* NC5 gene in PCR product by nested PCR;1: Negative Control 2: Standard DNA 3: Cow serum samples 4: Calf serum samples.**

**Table 1: Detection of anti-*Neospora caninum* antibodies and *Neospora caninum* DNA by ELISA, PCR and nested-PCR\***

	Caws				Calves			
Sample No.	S/P **	ELISA	PCR	nested-PCR	S/P **	ELISA	PCR	nested-PCR
1	0.842	+	+	+	0.706	+	+	+
2	0.524	+	+	+	0.021	-	-	-
3	0.56	+	+	+	0.42	-	-	-
4	0.669	+	+	+	1.032	+	+	+
5	0.911	+	+	+	0.141	-	-	-
6	0.572	+	+	+	0.576	+	+	+
7	1.197	+	+	+	0.706	+	+	+
8	0.588	+	+	+	1.26	+	+	+
9	0.685	+	+	+	1.44	+	+	+
10	0.834	+	+	+	0.228	-	-	-
11	0.649	+	+	+	0.04	-	-	-
12	0.766	+	+	+	0.108	-	-	-
13	0.991	+	+	+	0.108	-	-	-
14	0.508	+	+	+	0.347	-	-	-
Total Positive (%)	0.73±0.19	14 (28.57)	14 (28.57)	14 (28.57)	0.51±0.44	6 (12.24)	6 (12.24)	6 (12.24)

\*: Cows with S/P ELISA titer greater than 0.5, PCR or nested PCR were considered positive (n=14); S/P: OD of standard samples to positive samples ; \*\*: Mean±Standard Deviation.

**Table 2: Infection status of mothers and its relationship with maternal infection of calves (n=49)\***

	Positive calves	Negative calves	Vertical Transmission Rate (%)	Relative Risk (CI95%)
Positive Dam	6	8	42.85%	31.2 (1.9-519.6)
Negative Dam	0	35	0%	
Total	6	43	12.24%	
p-value	0.000036			0.016

\*: Cows with S/P ELISA titer greater than 0.5, PCR or nested PCR were considered positive (n=49); CI95%: 95% confidence interval

**Table 3: S/P ELISA titer status of infected mothers and their calves (n=14)\***

	calf		
	PCR positive (n=6)	PCR negative (n=8)	p-value
Dam S/P	0.76±0.23	0.72±0.18	0.732
Calf S/P	0.95±0.35	0.18±0.14	0.002

\*: Calves with S/P ELISA titer greater than 0.5, PCR or nested PCR were considered positive; S/P: OD of standard samples to positive samples ; \*\*: Mean±Standard Deviation.

## Discussion

Based on serum *Neospora* genomic findings, statistical analysis showed a significant relationship ( $p$ -value=0.000036) between maternal infection and the possibility of newborn infection (Table 2). Transplacental transmission rate observed in 12.24% of all cows and 42.85% of positive cows. The first report on the abortion was caused by *Neospora* in Iran addressed rates of 13% for abortion (Razmi et al, 2007) and 14.4% for total vertical transmission (Razmi et al, 2010), which was almost similar to the findings of this research.

According to other investigations, the rate of vertical transmission in cattle varies from 4 to even 100 percent and the rate of abortion in these studies is around 11%; the rate of abortion in animals with a high titre of anti-*Neospora* antibody was usually shown to be higher than that in animals with no titre of the antibody (Dubey et al, 2007; Macedo et al, 2013). In our results, statistical analysis showed that the relative risk for the vertical transmission and the rate of transplacental transmission for *N.caninum* from seropositive mothers to their ABH calves were 31.2 and 42.85%, respectively (Table 2). The high relatively risk for transplacental transmission of the parasite emphasizes that the vertical transmission plays an important role in the remaining and distribution of the infection in large dairy farms.

All of the serum samples in this study were tested for *Neospora* DNA by PCR and further confirmed by nested-PCR. The results showed that the *Neospora* DNA was only detectable in the sera containing anti-

*Neospora* antibody with OD above the cut-off point (OD more than 0.5). Similar results were also obtained in buffalo, where *Neospora* DNA was only detected in the sera of seropositive buffaloes (unpublished data). Although PCR positive results were observed merely in mothers and newborns with ELISA titers above the cut point, another interesting point of the present study is that, despite the high titer of the ELISA of 14 dams, 6 of them (42.85%) were unable to prevent placental transmission of the infection in contrast to 8 dams (57.14%). It seems that the recent group of 8 cattle have been able to show effective placental immunity despite the evidenc of the infection. The significant high level of ELISA titer in 6 congenitally infected calves is quite conceivable (Table 3). The results showed an overall rate of 12.24% for *Neospora* infection in AHB calves. All of the infected calves were born from seropositive mothers. These results confirmed the previous findings showing that the rate of vertical transmission of *Neospora* in seropositive cows was higher than that in seronegative cases (Santos et al, 2012).

Yet in naturally infected cattle, *Neospora* DNA has been detected in the semen, blood, brain and fetal tissues (Ferre et al, 2005; Okeoma et al, 2004). Detection of *Neospora* DNA in the serum of pregnant cows was also reported (McInnes et al, 2006). On the other hand, some previous studies addressed a high level of anti-*Neospora* antibody in acute phases of the infection and detection of *Neospora* DNA in the blood after parasitemia (Ferre et al, 2005;

Okeoma et al, 2005). Simultaneous detection of anti-*Neospora* antibody in the serum and *Neospora* DNA in WBCs was also reported in some studies (Okeoma et al, 2005; Okeoma et al, 2004); but this is the first report on a 100 percent concurrency in detection of *Neospora* DNA and anti - *Neospora* antibody in the serum of both mothers and their precolostral calves in cattle immediately after delivery. DNA of other protozoa such as *Toxoplasma*, which are highly similar to *Neospora*, was also detected by other researchers in mouse and human sera (Hafid et al, 2000; Meganathan et al, 2010). They believed that using the serum for diagnosis of such parasites by PCR, can be employed in retrospective studies (McInnes et al, 2006). Some other researchers could not find the *Neospora* DNA in the serum of seropositive cows with abortion caused by *Neospora*, so emphasized the lack of association between the presence of *Neospora* DNA and anti-*Neospora* antibodies in the serum (McInnes et al, 2006). Therefore, the association between the presence of DNA and anti-*Neospora* antibodies in *Neospora* infected cows occurs only when they are infected in the second semester of the pregnancy resulting in delivering AHB calves. In addition, we used a whole-cell based ELISA and it is thought that using the whole parasite renders a higher specificity for ELISA in diagnosing *Neospora*. In our results, the level of the antibody in 9 *Neospora* DNA negative cows was significantly high but below the cut-off point. It seems when the level of the antibody was higher than the cut-off point, the *Neospora* DNA was detectable in the serum and after removing the parasite from the blood by the immune system, the level of antibody in the serum dropped below the cut-off point.

Although in epitheliochorial placenta, bloods of mothers and fetuses are not

mixed together (Dubey et al, 2006), the parasite is able to break the placental barrier in some of *Neospora* positive mothers and arrive the foetal blood producing a high level of the antibody in the serum of AHB calves before receiving the colostrum. Therefore, the antibody detected in the calves' sera was produced by the foetus itself. This confirms the capability of foetal immune system in producing an immune response against the parasite (Table 3). This was in line with some other studies, which reported a high level of anti-*Neospora* antibody in the sera of precolostral calves delivered by mothers with a history of *Neospora* caused abortion (Bou et al, 1999). It is known that pathogenic agents are recognized by the foetal immune system after the first trimester of pregnancy, so that the possibility of creating persistent infection by *Neospora* has been discussed by some of *Neospora* researchers (McInnes et al, 2006). So, the AHB calves of our study received the infection after the first trimester of pregnancy and the foetal immune system was able to recognize the parasite and prevent the abortion by producing the antibody.

In the present study, the similarity of ELISA and PCR results in mothers, was also observed in their AHB calves indicating a similar phenomenon occurred in both mothers and the calves.

There was a strong association between the presence of *Neospora* DNA and high levels of anti- *Neospora* antibody in the serum of *Neospora* infected cows and their precolostral AHB calves. Although placental immunity plays an effective role in preventing vertical transmission, this parasite can be transmitted vertically to calves born from infected mothers at a relatively high rate. The placental barrier is capable to stop the parasite from transmission and needs to be more investigated.



## Acknowledgements

The authors would like to thank Bu-Ali Sina University for funding the project, Razi Vaccine and Serum Research Institute, Shiraz, Iran, for the generous donation of the *N. caninum* isolate and Miss S. Azami for her technical assistance. The authors also express sincerely thanks to B. Payedar, production manager of the Agricultural and Industrial Company of Avindasht for his assistance in sampling.

## Conflict of interest

We declare that there is no conflict of interest.

## Funding

This study was supported by project from Bu-Ali Sina University, Hamedan, Iran.

## References

- Bou, G., Figueroa, M. S., Marti-Belda, P., Navas, E., & Guerrero, A. (1999). Value of PCR for detection of *Toxoplasma gondii* in aqueous humor and blood samples from immunocompetent patients with ocular toxoplasmosis. *Journal of Clinical Microbiology*, 37(11), 3465-3468.
- Dubey, J. P. (2003). Review of *Neospora caninum* and neosporosis in animals. *Korean Journal of Parasitology*, 41(1), 1-16.
- Dubey, J. P., Buxton, D., & Wouda, W. (2006). Pathogenesis of bovine neosporosis. *Journal of Comparative Pathology*, 134(4), 267-289.
- Dubey, J. P., & Scharles, G. (2006). Diagnosis of bovine neosporosis. *Veterinary Parasitology*, 140(1-2), 1-34.
- Dubey, J. P., Scharles, G., & Ortega-Mora, L. M. (2007). Epidemiology and control of neosporosis and *Neospora caninum*. *Clinical Microbiology Reviews*, 20(2), 323-367.
- Ferre, I., Aduriz, G., Del-Pozo, I., Regidor-Cerrillo, J., Atxaerandio, R., Collantes-Fernandez, E., Ortega-Mora, L. M. (2005). Detection of *Neospora caninum* in the semen and blood of naturally infected bulls. *Theriogenology*, 63(5), 1504-1518.
- Guy, CS, Williams, Diana JL, Kelly, DF, McGarry, JW, Guy, F, Björkman, C, Trees, Alexander J. (2001). *Neospora caninum* in persistently infected, pregnant cows: spontaneous transplacental infection is associated with an acute increase in maternal antibody. *The Veterinary record*, 149(15), 443-449.
- Hafid, J., Guichard, D., Flori, P., Bourlet, T., Raberin, H., Genin, C., & Sung, R. T. (2000). Detection of *Toxoplasma gondii* by polymerase chain reaction in sera of acutely infected mice. *Journal of Parasitology*, 86(4), 857-859.
- Hajikolaie, Haji M. R., Goraninejad, S., Hamidinejat, H., Ghorbanpour, M., & Paryab, R. (2007). Occurrence of *Neospora caninum* antibodies in water buffaloes (*Bubalus bubalis*) from the south-western region of Iran. *Bulletin of the Veterinary Institute in Pulawy*, 51(2), 233.
- Macedo, C. A., Macedo, M. F., Cardim, S. T., Paiva, M. C., Taroda, A., Barros, L. D., Garcia, J. L. (2013). *Neospora caninum*: evaluation of vertical transmission in slaughtered dairy cows (*Bos taurus*). *Revista Brasileira de Parasitologia Veterinaria*, 22(1), 13-17.
- McInnes, L. M., Ryan, U. M., O'Handley, R., Sager, H., Forshaw, D., & Palmer, D. G. (2006). Diagnostic significance of *Neospora caninum* DNA detected by PCR in cattle serum. *Veterinary Parasitology*, 142(3-4), 207-213.
- Meganathan, P., Singh, S., Ling, L. Y., Singh, J., Subrayan, V., & Nissapatorn, V. (2010). Detection of *Toxoplasma gondii* DNA by PCR following microwave treatment of serum and whole blood. *The Southeast Asian Journal of Tropical Medicine and Public Health*, 41(2), 265-273.
- Nasir, A., Lanyon, S. R., Scharles, G., Anderson, M. L., & Reichel, M. P. (2012). Sero-prevalence of *Neospora caninum* and *Besnoitia besnoiti* in South Australian beef and dairy cattle. *Veterinary Parasitology*, 186(3-4), 480-485.
- Okeoma, C. M., Stowell, K. M., Williamson, N. B., & Pomroy, W. E. (2005). *Neospora caninum*: quantification of DNA in the blood of naturally infected aborted and pregnant cows using real-time PCR. *Experimental Parasitology*, 110(1), 48-55.



- Okeoma, C. M., Williamson, N. B., Pomroy, W. E., Stowell, K. M., & Gillespie, L. (2004). The use of PCR to detect *Neospora caninum* DNA in the blood of naturally infected cows. *Veterinary Parasitology*, 122(4), 307-315.
- Pare, Julie, Thurmond, Mark C, & Hietala, Sharon K. (1997). *Neospora caninum* antibodies in cows during pregnancy as a predictor of congenital infection and abortion. *The Journal of parasitology*, 82-87.
- Razmi, G. R., Maleki, M., Farzaneh, N., Talebkhan Garoussi, M., & Fallah, A. H. (2007). First report of *Neospora caninum*-associated bovine abortion in Mashhad area, Iran. *Parasitology Research*, 100(4), 755-757.
- Razmi, G. R., Zarea, H., & Naseri, Z. (2010). A survey of *Neospora caninum*-associated bovine abortion in large dairy farms of Mashhad, Iran. *Parasitology Research*, 106(6), 1419-1423.
- Santos, R. R., da Rocha, C. M., Goncalves Tde, M., & Guimaraes, A. M. (2012). Quantification of vertical transmission of *Neospora caninum* in dairy cows in Minas Gerais, Brazil. *Revista Brasileira de Parasitologia Veterinaria*, 21(3), 294-297.
- Stenlund, Susanne, Kindahl, Hans, Magnusson, Ulf, Uggla, Arvid, & Björkman, Camilla. (1999). Serum antibody profile and reproductive performance during two consecutive pregnancies of cows naturally infected with *Neospora caninum*. *Veterinary parasitology*, 85(4), 227-234.
- Yu, Jinhai, Xia, Zhaofei, Liu, Qun, Liu, Jing, Ding, Jun, & Zhang, Wei. (2007). Seroepidemiology of *Neospora caninum* and *Toxoplasma gondii* in cattle and water buffaloes (*Bubalus bubalis*) in the People's Republic of China. *Veterinary parasitology*, 143(1), 79-85.

Received: 02.08.2022

Accepted: 14.12.2022

## Muscular Stomach in Birds of Prey, Common Kestrel (*Falco tinnunculus*), Steppe Eagle (*Aquila nipalensis*), Golden Eagle (*Aquila chrysaetos*) and Imperial Eagle (*Aquila heliaca*); A Morphological Evaluation

Ali Kalantari-Hesari<sup>1\*</sup>, Mohammad Babaei<sup>2</sup>, Kaveh Esfandiyari<sup>3</sup> and Hassan Morovvati<sup>4</sup>

<sup>1</sup> Assistant Professor, Department of Pathobiology, Faculty of Veterinary Science, Bu-Ali Sina University, Hamedan, Iran

<sup>2</sup> Assistant Professor, Department of Clinical Sciences, Faculty of Veterinary Science, Bu-Ali Sina University, Hamedan, Iran

<sup>3</sup> PhD Graduated of Histology, Faculty of Veterinary Medicine, University of Tehran, Tehran, Iran

<sup>4</sup> Professor, Department of Basic Sciences, Faculty of Veterinary Medicine, University of Tehran, Tehran, Iran

Received: 17.11.2022

Accepted: 19.12.2022

### Abstract

Muscular stomach or gizzard is one of the most important parts of gastrointestinal tract in birds for mechanical and chemical digestion and can vary depending on the bird's eating habits. In the present study, the morphology of muscular stomach in common kestrel, steppe eagle, golden eagle and imperial eagle has been investigated and compared. **Materials & Methods:** In this study, common kestrel (n=4), steppe eagle (n=5), golden eagle (n=4) and imperial eagle (n=6) which died because of broken leg and wing, sent to the faculty of veterinary science at Bu-Ali Sina University of Hamadan. The gizzard samples were fixed in 10% formalin buffer solution and the histological process was carried. Finally, H&E, Masson's trichrome, Orcein and PAS staining were utilized. **Results:** The most important difference between the stomach of steppe, golden, and imperial eagles and common kestrel was the lack of keratinous layer in the surface of stomach in eagles. The histological structure of stomach in imperial eagle was more similar to that of steppe eagle. The differences of the stomach of imperial eagle were due to the presence of a thick muscle layer in several different rows with different directions in comparison with steppe and golden eagles. **Conclusions:** It can be concluded that, the structure of muscular stomach in common kestrel was similar to gizzard, while the stomach in three species of eagles did not have a keratinous layer.

**Keywords:** Birds of prey, Common kestrel, Eagles, Histology, Muscular stomach

### Introduction

One of the most important parts of digestive system in birds, which is responsible for the mechanical and chemical digestion of food, is the stomach. In birds, stomach is anatomically and functionally composed of two distinct parts; the glandular stomach or proventriculus and

the muscular stomach or gizzard. The proventriculus is attached to esophagus and the chemical digestion of food (by the secretion of the enzyme pepsin and hydrochloric acid) takes place in proventriculus. The gizzard, on one side, is connected to proventriculus by strait and on

\* **Corresponding Author:** Ali Kalantari-Hesari, Assistant Professor, Department of Pathobiology, Faculty of Veterinary Science, Bu-Ali Sina University, Hamedan, Iran  
E-mail: [a.kalantarihesari@basu.ac.ir](mailto:a.kalantarihesari@basu.ac.ir)



the other side is connected to duodenum. It is also responsible for the mechanical digestion of food. Depending on the type of diet, there are two types of stomachs, one of which belongs to carnivorous and fish-eating birds, which is, due to the use of relatively soft and bulky foods, compatible to store this type of food. The stomach in this type of birds is bag-shaped and has a thin wall. Another type of stomach belongs to birds that eat foods such as insects, plants and seeds. Since the food of these birds is slow to digest, they need a stomach that can also do physical digestion. In this type of bird, gizzard clearly has thick and expanded muscle layers and the proventriculus-gizzard junction is easily recognizable from the outside (Hristov, 2020; Hanafy et al, 2020; El-Mansi et al, 2021; Madkour et al, 2022).

The common kestrel belongs to *Falco tinnunculus* family and lives in open areas, groves, lagoons and near towns and villages. This bird is smaller than other birds of prey but larger than most sparrows. The common kestrel is found in abundance in Iran (Groombridge et al, 2002).

The Golden Eagle (*Aquila chrysaetos*) is one of the best birds of prey in the Northern Hemisphere. Like all eagles, golden eagle belongs to the eagle family. The color of these birds is dark brown, along with light brown or golden feathers on the head and neck. The golden eagle is sometimes known as the best bird among other eagles and other birds of prey (Collopy et al, 2017). In Iran, this animal is found in many different parts of the country. Golden eagle can be found in deserts of Iran and cities such as Ardabil, Yazd, and other cities from northwest to east of the country.

The steppe eagle (*Aquila nipalensis*) is a bird of prey from the eagle family. This bird is found as an immigrant in Iran and is protected. This bird is 75 cm long. The adult bird has dark brown color or lighter, with a variety of under-wing covering, similar to other parts of the body. Beneath the wing they have uniform color with darker or

lighter flight feathers, and broad dark bands are seen at the end margin of their wings, which is darker at the end of the wings. The bird's habitat is in open areas, semi-desert steppes and foothills, and near wetlands and garbage dumps in desert cities (Vazhov et al, 2013).

The Imperial Eagle (*Aquila heliaca*) is a species of bird of prey from the eagle family, which has dark brown ornamental feathers during adulthood. This bird is considered a large eagle. Females are about 25% larger than males. The imperial eagle is very similar to the golden eagle, and can be distinguished from the golden eagle by its taller beak, smoother wings during flight, white spots on the shoulders and wings, lighter and more colorful shoulders, and darker color on the rest of the body. Also, immature imperial eagles are much lighter in color than immature golden eagles. The imperial eagle's favorite habitat is open plains with few trees, and unlike many other eagles, it does not live in mountains and forests. Rabbits, hamsters and pheasants are the main prey of this eagle (HorvátH et al, 2018).

The histological structure of proventriculus and gizzard has been reported in native sparrows (Raji and Asadi, 2013), common starlings (Sayrafi and Aghagolzadeh, 2020), domestic ducks and pigeons (Hassan & Moussa, 2012), seagulls (Selvan et al., 2008), red junglefowl (Kadhim et al., 2011), and yellow-billed grosbeak (Zhu et al, 2013). However, so far, no study has been done on the histological structure of muscular stomach (gizzard) in common kestrel, steppe eagle, golden eagle and imperial eagle. Therefore, in the present study, the structure of this organ was investigated and compared in these birds.

## Materials and method

In this study, common kestrel (n=4), steppe eagle (n=5), golden eagle (n=4) and imperial eagle (n=6) which died because of broken leg and wing, were sent to the

faculty of veterinary science at Bu-Ali Sina University of Hamadan. Muscular stomach samples were taken and placed in 10% buffer formalin solution for fixation. After 72 hours, the samples entered the tissue passage stages (using the Tissue Processor DS9602). After completing the passage steps and preparing the paraffin blocks, 5µm slides (Rotary Microtome DS4055) were prepared from the samples. The prepared slides entered the H&E staining process and, after drying, were examined by optical microscope (Medic M-107 BN). Histomorphometric examination was performed by a Dino-Lite lens digital camera and Dino-capture 2 software (Shahrooz et al, 2018; Kalantari et al, 2015; Akbari et al, 2018). For histochemical evaluation of muscular stomach structure in four species of birds of prey in current study, three types of staining consist of Masson's trichrome (for investigation and tracking collagen fibers), Orcein (for evaluation and tracing elastic fibers), and Periodic acid Schiff (PAS) (for considering of carbohydrates density) stainings were utilized (Sayrafi and Aghagolzadeh, 2019).

## Results

### Histological structure of the stomach in common kestrel

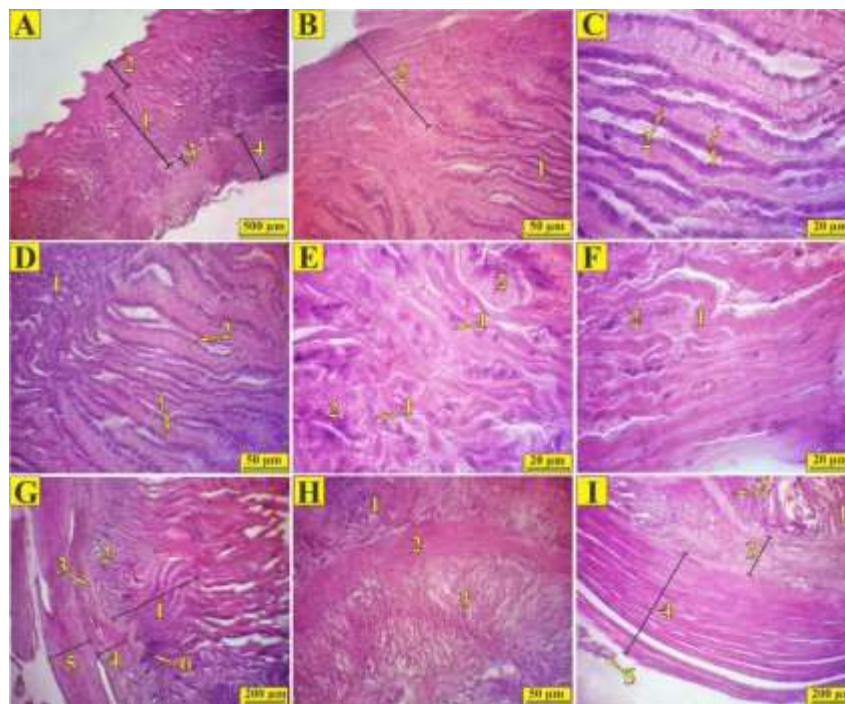
The structure of stomach in common kestrel has the general shape of tubular organs and consists of four layers of mucosa (epithelial tissue, lamina propria, and mucosal muscle), submucosa, muscular

layer (muscularis) and the outermost layer (serosa), (Figure 1B). The stomach mucosa in common kestrel has large folds. The surface of mucosa in this bird contains a relatively thick keratinous layer (Figures 1A and 1B).

The epithelium in all three initial, middle, and end parts of common kestrel stomach is composed of long or short columnar epithelium with basal nucleus. Superficial epithelial cells turn into simple cuboidal mucosal gland cells (Figures 1C and 1D). The secretions of rugged layer generate from the mucosal glands and after passing through the glands' ducts and superficial epithelium turn into a relatively thick layer (Figures 1E and 1F). The mucosal glands are made of simple tubular tissues that are located within lamina propria. The lamina propria is made of loose connective tissue and is filled with diffuse lymphatic tissue that fills the space between the glands (Figure 1G).

The mucosal muscle, as a continuous layer of smooth muscle, separates the lamina propria and submucosa. The submucosa is made of dense connective tissue (Figure 1H).

The not-so-thick muscle layer in the common kestrel stomach contains several relatively thin layers of smooth muscle, all in the same direction and separated from each other by a thick connective tissue. Thick serosa covers the outside of the organ and contains nerves and blood vessels (Figure 1I).



**Figure 1.** Histological structure of stomach in common kestrel (H&E staining). **A:** Cross section of the initial part of stomach in common kestrel, 1) Mucosa, 2) Keratinous layer, 3) Submucosa, 4) Muscle layer. **B:** Cross section of the stomach mucosa in common kestrel, 1) Mucosal glands, 2) Keratinous layer. **C:** Cross section of the stomach mucosa in common kestrel, 1) Simple apical columnar epithelium, 2) Simple cuboidal epithelium of mucosal glands. **D:** Cross section of the stomach mucosa in common kestrel, 1) Mucosal glands, 2) Simple apical columnar epithelium, 3) Simple cuboidal epithelium of mucosal glands. **E, F:** Cross section of the stomach secretory glands in common kestrel, 1) Secreting keratinous layer, 2) Simple apical columnar cells. **G:** Cross section of the middle part of stomach in common kestrel, 1) Mucosal glands, 2) lamina propria, 3) Mucosal muscle, 4) Submucosa, 5) Muscle layer, 6) Diffuse lymphatic tissue. **H:** Cross section of stomach mucosal muscle in common kestrel, 1) lamina propria, 2) Mucosal muscle, 3) Submucosa. **I:** Cross section of stomach muscle layer in common kestrel, 1) Mucus, 2) Mucosal muscle, 3) Submucosa, 4) Muscle layer, 5) Serosa.

### Histological structure of stomach in steppe eagle

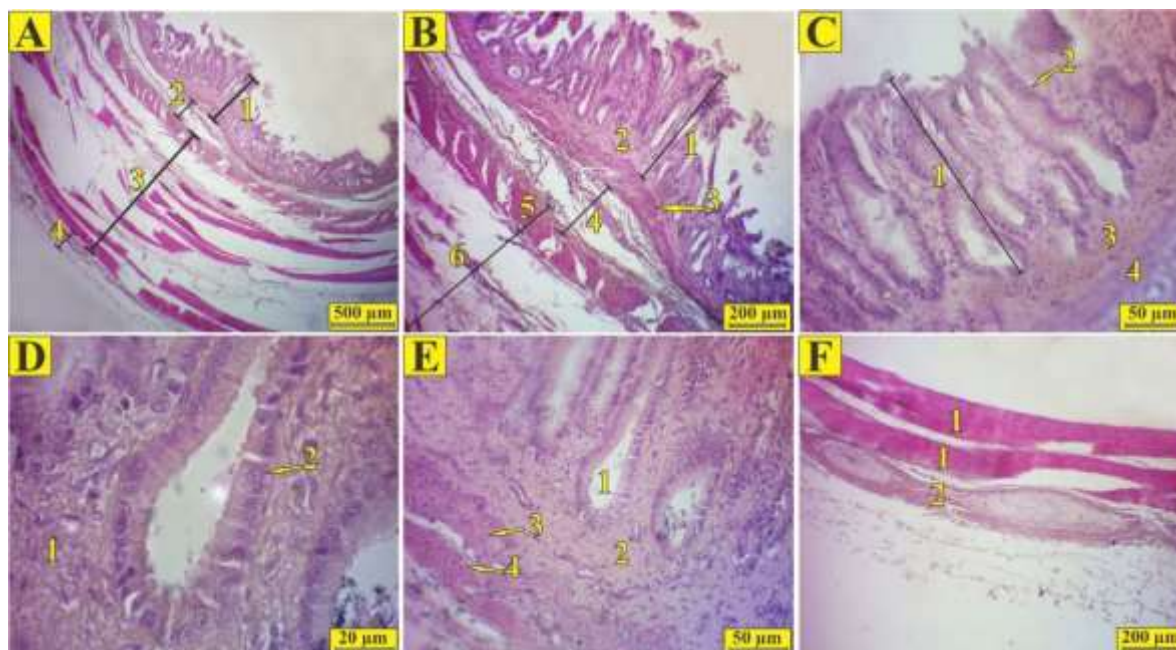
Histologically, slight differences were observed between the stomach of common kestrel and steppe eagle. Stomach in steppe eagle had a tubular shape and consisted of four layers of mucosa (epithelial tissue, lamina propria, and mucosal muscle), submucosa, muscle layer, and serosa (Figures 2A and 2B). The differences between the stomach of the eagle and common kestrel are due to the fact that; the stomach in the steppe eagle contained short folds and multiple villis. The most important difference was the lack of keratinous layer in the superficial part of the steppe eagle's stomach.

The epithelial tissue in all three initial, middle and end parts of this organ was made

of short to tall columnar tissues (Figure 2C). The mucosal glands with simple tubular tissue and epithelium with simple columnar to simple cuboidal tissues were visible (Figure 2D). The mucosal muscle was also visible in two layers, with the upper layer being continuous and the lower one being discontinuous in some areas (Figure 2E).

The submucosa was made of relatively thick and dense connective tissue that contained blood vessels and nerves (Figure 2B). The muscle layer was relatively thick and was visible as separate bundles (separated by connective tissue). The innermost muscle layer seemed to have a different direction than the other layers. The outermost layer of this organ was made of thick serosa that contained nerves and blood vessels (Figures 2B and 2F).



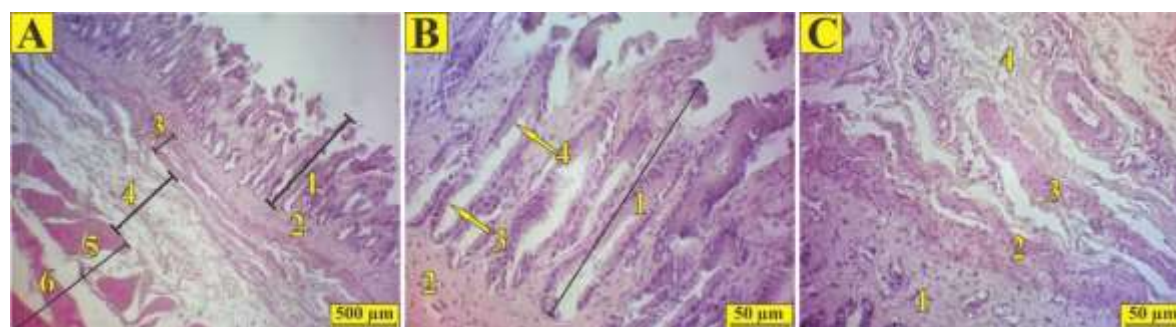


**Figure 2.** Histological structure of stomach in the steppe eagle (H&E staining). A: Cross section of the middle part of stomach in steppe eagle, 1) Mucosa, 2) Submucosa, 3) Muscle layer, 4) Serosa. B: Cross section of the middle part of stomach in steppe eagle, 1) Mucosal glands, 2) lamina propria, 3) Mucosal muscle, 4) Submucosa, 5) First muscle layer, 6) others muscle layers. C: Cross section of mucosa in the stomach of steppe eagle, 1) Mucosal glands, 2) Simple apical columnar epithelium, 3) lamina propria, 4) Mucosal muscle. D: Cross section of stomach mucosa in steppe eagle, 1) lamina propria, 2) Glandular epithelium. E: Cross section of the mucosal muscle layer in the stomach of steppe eagle, 1) Mucosal gland, 2) lamina propria, 3) Upper mucosal muscle, 4) Lower mucosal muscle. F: Cross section of the muscle layer in the stomach of steppe eagle, 1) Muscle layers, 2) Serosa.

### Histological structure of stomach in golden eagle

The histological structure of stomach in the golden eagle was similar to that of the steppe eagle's (Figure 3). Significant structural difference between the stomach of golden eagle and common kestrel was the

lack of keratinous layer in the stomach of golden eagle. Also, the mucosal muscle in the stomach of golden eagle contained two layers of smooth muscles, with the upper layer being continuous and the lower one being discontinuous in some areas (Figure 3C).



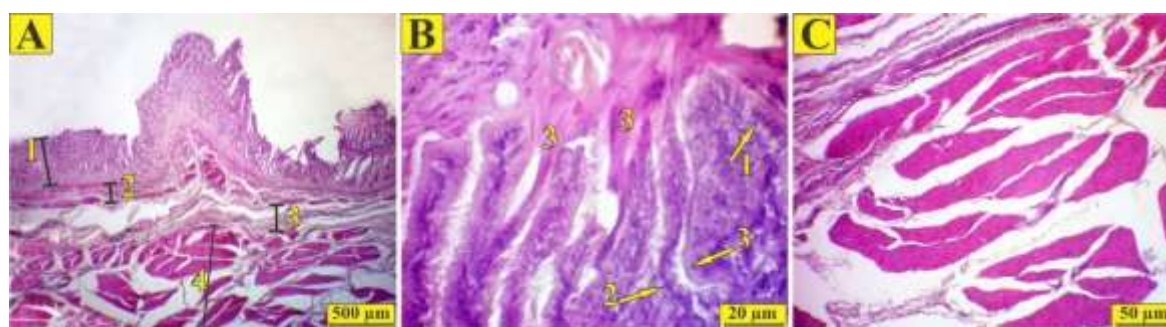
**Figure 3:** Histological structure of stomach in golden eagle (H&E staining). A: Cross section of the end part of stomach in golden eagle, 1) Mucosal glands, 2) lamina propria, 3) Mucosal muscle, 4) Submucosa, 5) First muscle layer, 6) Other muscle layers. B: Cross section of stomach mucosa in golden eagle, 1) Mucosal glands, 2) lamina propria, 3) Simple cuboidal epithelium of the glands, 4) simple apical columnar epithelium. C: Cross section of mucosa and submucosa in golden eagle stomach, 1) lamina propria, 2) Upper layer of mucosal muscle, 3) Lower layer of mucosal muscle, 4) Submucosa.

### Histological structure of stomach in imperial eagle

The structure of stomach in imperial eagle was similar to that of the steppe eagle's (Figure 4). The mucosal layer was visible as two layers of smooth muscles, with the upper layer being continuous and the lower one being discontinuous (Figure 4A). The most significant structural difference between the stomach of golden eagle and common kestrel was the lack of clear superficial keratinous layer in the stomach of imperial eagle, although the

secretion of keratinous layer between mucosal glands was visible (Figure 4B). The difference between the stomach of imperial eagle and stomach of steppe and golden eagles was due to the presence of thick muscle layer in several rows with different directions (Figure 4C).

The results of histomorphometric examination of different parts of the stomach in common kestrel, steppe eagle, golden eagle and imperial eagle are presented in Tables 1 and 2.



**Figure 4.** Histological structure of stomach in imperial eagle (H&E staining). **A:** Cross section of the middle part of stomach in imperial eagle, 1) Mucosa and lamina propria, 2) Mucosal muscle layers, 3) Submucosa, 4) Muscle layer. **B:** Cross section of the secreting stage of keratinous layer in the mucosal glands, 1) Simple apical columnar epithelium, 2) Cuboidal epithelium of the glands, 3) The secreting stratum keratinous layer. **C:** Cross section of the muscle layer in the stomach of imperial eagle.

**Table 1. Results of stomach morphometry in common kestrel and steppe eagle**

	Parameter	The initial one third	The middle one third	The end one third
Common kestrel	Epithelium height ( $\mu\text{m}$ )	$14.435 \pm 1.174$	$12.640 \pm 3.817$	$15.007 \pm 0.686$
	Thickness of mucosal layer ( $\mu\text{m}$ )	$374.970 \pm 74.458$	$322.815 \pm 8.088$	$558.120 \pm 39.037$
	Thickness of mucosal muscle ( $\mu\text{m}$ )	$39.247 \pm 1.174$	$50.605 \pm 13.611$	$24.697 \pm 10.117$
	Thickness of submucosa ( $\mu\text{m}$ )	$261.460 \pm 81.339$	$74.217 \pm 17.078$	$33.242 \pm 9.923$
	Thickness of muscle layer ( $\mu\text{m}$ )	$499.047 \pm 3.661$	$969.650 \pm 42.273$	$171.280 \pm 35.604$
	Diameter of sub-mucosal glands ( $\mu\text{m}$ )	$11.515 \pm 2.716$	$12.120 \pm 0.913$	$13.837 \pm 2.090$
Steppe eagle	Epithelium height ( $\mu\text{m}$ )	$345.407 \pm 23.999$	$442.780 \pm 51.387$	$489.092 \pm 54.247$
	Thickness of mucosal layer ( $\mu\text{m}$ )	$31.740 \pm 1.890$	$31.572 \pm 7.722$	$63.637 \pm 17.115$
	Thickness of mucosal muscle ( $\mu\text{m}$ )	$152.027 \pm 53.876$	$101.402 \pm 19.186$	$226.877 \pm 25.993$
	Thickness of submucosa ( $\mu\text{m}$ )	$595.407 \pm 82.824$	$1149.105 \pm 41.552$	$852.255 \pm 31.637$
	Thickness of muscle layer ( $\mu\text{m}$ )	$12.441 \pm 2.547$	$11.208 \pm 1.112$	$12.857 \pm 1.226$
	Diameter of sub-mucosal glands ( $\mu\text{m}$ )	$327.446 \pm 21.784$	$469.719 \pm 47.456$	$441.777 \pm 50.374$

All data were represented as the mean  $\pm$  standard deviation.

**Table 2. Results of stomach morphometry in golden eagle and imperial eagle**

	Parameter	The initial one third	The middle one third	The end one third
Golden eagle	Epithelium height ( $\mu\text{m}$ )	$29.583 \pm 1.786$	$33.547 \pm 5.458$	$67.614 \pm 14.415$
	Thickness of mucosal layer ( $\mu\text{m}$ )	$171.372 \pm 42.574$	$119.486 \pm 22.104$	$241.417 \pm 21.578$
	Thickness of mucosal muscle ( $\mu\text{m}$ )	$624.415 \pm 71.803$	$1264.475 \pm 61.741$	$846.475 \pm 33.345$
	Thickness of submucosa ( $\mu\text{m}$ )	$10.499 \pm 1.574756$	$12.145 \pm 2.432$	$11.843 \pm 1.476$
	Thickness of muscle layer ( $\mu\text{m}$ )	$362.477 \pm 22.464$	$439.419 \pm 50.447$	$455.771 \pm 38.437$
	Diameter of sub-mucosal glands ( $\mu\text{m}$ )	$36.443 \pm 2.189$	$29.554 \pm 2.472$	$72.603 \pm 16.347$
Imperial eagle	Epithelium height ( $\mu\text{m}$ )	$185.547 \pm 40.568$	$127.574 \pm 19.144$	$255.478 \pm 18.774$
	Thickness of mucosal layer ( $\mu\text{m}$ )	$683.159 \pm 73.458$	$1309.447 \pm 475$	$831.499 \pm 32.255$
	Thickness of mucosal muscle ( $\mu\text{m}$ )	$14.435 \pm 1.174$	$12.640 \pm 3.817$	$15.007 \pm 0.686$
	Thickness of submucosa ( $\mu\text{m}$ )	$374.370 \pm 74.458$	$322.815 \pm 7.088$	$558.120 \pm 39.037$
	Thickness of muscle layer ( $\mu\text{m}$ )	$39.247 \pm 5.661$	$50.605 \pm 13.611$	$24.697 \pm 10.117$
	Diameter of sub-mucosal glands ( $\mu\text{m}$ )	$261.460 \pm 81.339$	$74.217 \pm 17.078$	$33.242 \pm 9.923$

All data were represented as the mean  $\pm$  standard deviation.

### Histochemical results

Masson's trichrome staining: Histochemical examination of the Stomach structure in all four species of birds of prey showed the same results. Thus, in Masson's trichrome staining (to examine collagen fibers) showed that these fibers were mainly present in the lamina propria of the stomach of all four species of birds. However, very thin streaks of collagen fibers were visible in around the muscular layer, and also in the stomach serosa. No noteworthy differences were observed between species (Figures 5A, 5D, 5G, and 5J).

Orcein staining: The density of the elastic fibers in the stomach was not very noticeable. These fibers were seen only in the submucosa layer. Noticeable differences were not observed between species (Figures 5B, 5E, 5H, and 5K).

PAS staining: In the investigation of sections stained with PAS, it was observed that the most part of lamina propria had positive reaction to PAS staining. Also, the thick basement membrane of the mucosal layer epithelium in the stomach was well visible. Considerable differences were not seen between four species of birds of prey (Figures 5C, 5F, 5I, and 5L).



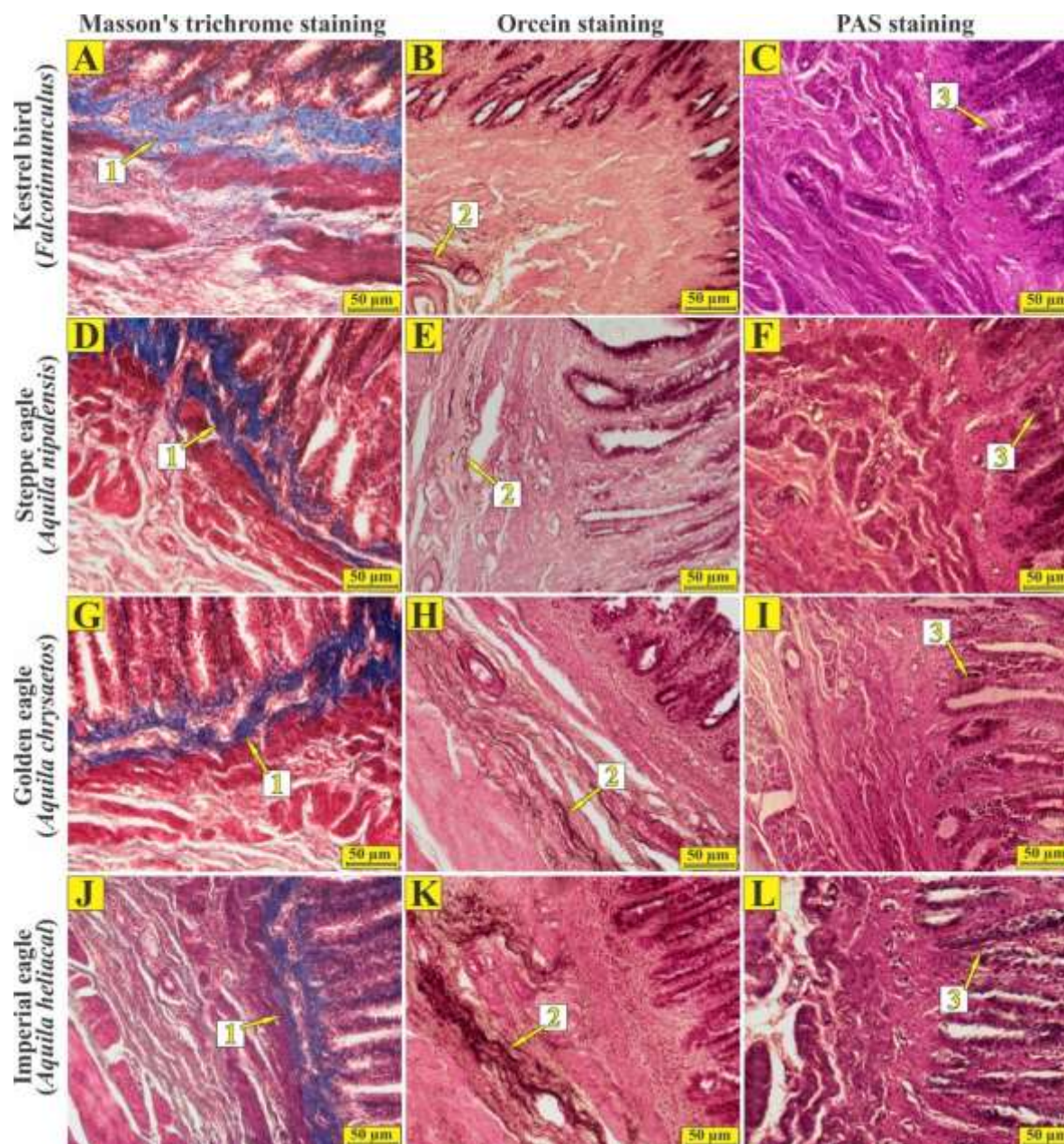


Figure 5. Histological sections of stomach in Common kestrel (*Falco tinnunculus*), Steppe eagle (*Aquila nipalensis*), Golden eagle (*Aquila chrysaetos*), and Imperial eagle (*Aquila heliaca*). Histochemical stainings.  $\times 100$ . A, D, G, and J respectively related to Masson's trichrome staining of stomach in Common kestrel, Steppe eagle, Golden eagle, and Imperial eagle, 1) Density of collagen fibers in the lamina propria. B, E, H, and K respectively related to Orcein staining of stomach in Common kestrel, Steppe eagle, Golden eagle, and Imperial eagle, 2) Elastic fibers. C, F, I, and L respectively related to Masson's trichrome staining of stomach in Common kestrel, Steppe eagle, Golden eagle, and Imperial eagle, 3) basement membrane of the epithelium layer.

## Discussion

The stomach in sparrow, like other birds, consists of four layers of mucosa, submucosa, muscularis, and serosa (Raji and Asadi, 2013). The stomach in starling also consists of four layers (Sayrafi and Aghagolzadeh, 2020). Also, in domestic

ducks and pigeons (Hassan and Moussa, 2012), seagulls (Selvan et al, 2008) and red junglefowl (Kadhim et al, 2011), reports show that stomach has four layers, while in yellow-billed grosbeak it only has three layers of mucosa, muscularis, and serosa

(Zhu et al, 2013). In the present study, the histological structure of muscular stomach in common kestrel, steppe eagle, golden eagle and imperial eagle was observed in four layers.

In sparrows and chickens, the mucosal folds are big and leaf-shaped. In the American red starling, mucosal folds are leaf shaped (Klem et al, 1976). The mucosal folds in owls are short and oval-shaped (De Oliveira Rocha & Inforzato de Lima, 1998). The number of mucosal folds in the red-crested finch is low (Catroxo et al, 1997). The type of food is involved in the formation and thickness of keratinous layer, and probably the higher the animal's diet in terms of wood content is, the thicker the keratinous layer will be. Studies show that the thickness of keratinous layer in omnivorous birds is thicker than in carnivorous and frugivorous birds (Jain, 1976). The mucosal layer of muscular stomach in sparrows has short longitudinal folds and its epithelium is made of simple columnar tissues. This mucosal layer is covered by a thick layer of glycoprotein (Raji and Asadi, 2013). The mucosal epithelium in chickens, owls, and red-crested finches is simple cylindrical (Catroxo et al, 1997; De Oliveira Rocha and Inforzato de Lima, 1998). In the present study, the mucosa in the muscular stomach of common kestrel was observed to have large folds containing the keratinous layer; whereas in the steppe eagle, the golden eagle and the imperial eagle it had large folds and multiple villi without the keratinous layer. Also, the epithelium in all four types of birds of prey studied in the present study was made of long or short columnar tissues.

The lamina propria in the sparrows, chickens, American red-crested finches and owls has been reported to be made of loose connective tissue. It is also being reported that the epithelium of the secretory units is made of simple columnar tissue. But the epithelium in some species, such as pigeons and hawks, is made of simple cuboidal

tissue (Catroxo et al, 1997; Klem et al, 1976). In another report, lamina propria in the sparrow's gizzard was made of loose connective tissue and a large number of simple tubular glands were observed parallel to each other. The secretory units in the mucosa of sparrow's gizzard are made of simple tubular tissue with a simple short columnar epithelium at the base of the glands and a long columnar tissue near the epithelium (Raji and Asadi, 2013). In the present study, lamina propria was made of loose connective tissue in common kestrel and contained diffuse lymphatic tissue, and in the steppe, golden and imperial eagles, it was made of relatively dense connective tissue. lamina propria in common kestrel was also made of simple tubular glands with simple cuboidal epithelium, but in the steppe, golden and imperial eagles, it was made of simple tubular glands with simple columnar to simple cuboidal epithelium.

It has been said that mucosal muscle does not exist in owls and American red-crested finches and submucosa- lamina propria is composed of loose connective tissue. It has also been reported that mucosal muscle does not exist in sparrow's gizzard and lamina propria and therefore submucosa cannot be distinguished (Raji and Asadi, 2013). In the present study, the mucosal muscle in common kestrel contained continuous smooth muscle layer and in all three species of eagles, contained two smooth muscle layers, with the upper layer being continuous and the lower one being discontinuous.

The submucosal in all four species studied in the present study was made of dense connective tissue, but it was thicker in the steppe, golden and imperial eagles. In this regard the results of the present study are consistent with all previous reports (Catroxo et al, 1997; Klem et al, 1976).

The muscular layer in sparrow's gizzard is very thick and visible in both inner longitudinal layer and outer circular layer. Between the loose connective tissue muscles, the blood vessels and Auerbach

network were visible (Raji and Asadi, 2013). In the present study, the muscle layer in common kestrel was not so thick and different muscle layers had different directions, while in the steppe eagle and the golden eagle, the muscle layer was relatively thick and the innermost muscle layer had a different direction than other layers. In regard to the muscle layer of imperial eagle, it was observed that the muscle layer was relatively thick and the muscle layers had different directions in relation to each other.

The structure of serosa layer in chickens, sparrows, red-crested finches and owls consists of loose connective tissue along with blood vessels, nerves and fat cells (Catroxo et al, 1997; De Oliveira Rocha and Inforzato de Lima, 1998). The serosa in sparrow's gizzard is made of loose

connective tissue, containing mesothelial cells, blood vessels, nerves and fat cells (Raji and Asadi, 2013). In the present study, the outermost layer of serosa was thickened in all four species.

According to the available sources, diet, eating habits, and amount of food consumed have been shown to affect the histology of gastrointestinal tract. Structural differences in the histology of proventriculus and stomach can be due to the variety and type of food consumed by the bird. In the present study, it was shown that the structure of stomach in four birds of prey, such as kestrel, steppe eagle, golden eagle and imperial eagle was similar to the structure of these organs in other birds, and slight structure differences were observed in our study compared to some reports.

### Acknowledgments

The authors would like to thank Dr. Erfan Moeini Fard, the veterinary doctor of Hamedan environment organization, for supplying the specimens.

### Conflict of interest

The authors declare that they have no conflict of interests.

### Funding

This research was funded by a grant (No. 99-153) from Bu Ali Sina University, Hamedan, Iran.

### References

- Akbari, G., Babaei, M., & Goodarzi, N. (2018). The morphological characters of the male external genitalia of the European hedgehog (*Erinaceus Europaeus*). *Folia morphologica*, 77(2): 293-300. [DOI: 10.5603/FM.a 2017.0098] [PMID: 29064545]
- Catroxo, M., Lima, M., & Cappellarco, C. (1997). Histological aspects of the stomach (Proventriculus and gizzard) of the red-capped cardinal (*Paroaria gularis gularis*, Linnaeus, 1766). *Revista chilena de anatomía*, 15(1): 19-27. [DOI: 10.4067/S0716-98681997000100003]
- Collopy, M. W., Woodbridge, B., & Brown, J. L. (2017). Golden eagles in a changing world. *Journal of Raptor Research*, 51(3), 193-196. [DOI: 10.3356/0892-1016-51.3.193]
- De Oliveira Rocha, S., & Inforzato de Lima, M.A. (1998). Histological aspects of the stomach of burrowing owl: *spéotyto cunicularia*, Molina, 1782. *Revista chilena de anatomía*, 16(2), 191-197.
- El-Mansi, A. A., El-Bealy, E. A., Rady, A. M., Abumandour, M. A., & El-Badry, D. A. (2021). Macro-and microstructures of the digestive tract in the Eurasian collared dove, *Streptopelia decaocto* (Frivaldszky 1838): Adaptive interplay between structure and dietary niche. *Microscopy Research and Technique*, 84(12), 2837-2856. [DOI: 10.1002/jemt.23843] [PMID: 34036668]
- Hanafy, B. G., Abumandour, M. M., & Bassuoni, N. F. (2020). Morphological features of the gastrointestinal tract of Garganey (*Anas querquedula*, Linnaeus 1758) Oesophagus to coprodeum. *Anatomia, histologia, embryologia*, 49(2), 233-250. [DOI: 10.1111/ahe.12519] [PMID: 31793044]



- Hassan, S.A., & Moussa, E.A. (2012). Gross and microscopic studies on the stomach of domestic duck (*Anas platyrhynchos*) and domestic pigeon (*Columba livia domestica*). *Journal of Veterinary Anatomy*, 5: 105–127. [DOI: 10.21608/JVA.2012.44877]
- HorvátH, M., Solti, B., Fatér, I., JuHáSz, T., HaraSztHy, L., Szitta, T., Ballók, Z. & PáSztorykovácS, S. (2018). Temporal changes in the diet composition of the Eastern Imperial Eagle (*Aquila heliaca*) in Hungary. *Ornis Hungarica*, 26(1), 1-26. [DOI: 10.1515/orhu-2018-0001]
- Hristov, H. (2020). Avian Stomach Anatomy—A Mini Review. *Bulgarian Journal of Veterinary Medicine*, 24(4), 461-468. [DOI: 10.15547/bjvm.2311]
- Jain, D.K. (1976). Histomorphology and proteolytic activity in the gastric apparatus of frugivorous, carnivorous and omnivorous species of birds. *Acta biologica Academiae Scientiarum Hungaricae*, 27(2-3): 135-145. [PMID: 16419]
- Kadhim, K.K., Zuki, A.B.Z., Noordin, M.M., & Babjee, S.M.A. (2011). Histomorphology of the stomach, proventriculus and ventriculus of the red jungle fowl. *Anatomia Histologia Embryologia*, 40(3): 226–233. [DOI: 10.1111/j.1439-0264.2010.01058.x] [PMID: 21443757]
- Kalantari-Hesari, A., Shahrooz, R., Ahmadi, A., Malekinejad, H., & Saboori, E. (2015). Crocin prevention of anemia-induced changes in structural and functional parameters of mice testes. *Journal of Applied Biomedicine*, 53: 213–223. [DOI: 10.1016/j.jab.2015.02.001]
- Kangas, V. M., Carrillo, J., Debray, P., & Kvist, L. (2018). Bottlenecks, remoteness and admixture shape genetic variation in island populations of Atlantic and Mediterranean common kestrels (*Falco tinnunculus*). *Journal of Avian Biology*, 49(10), e01768. [DOI: 10.1111/jav.01768]
- Klem, J.R., Brancato, C.R., & Catalano, J.F. (1976). Huzmin, F.C. Gross morphology and general histology and omnivorous species of birds. *Acta biologica Academiae Scientiarum Hungaricae*, 27,135-145. [DOI: 10.1111/ahe.12504] [PMID: 31617250]
- Madkour, F., Mohamed, S. A., Abdalla, K. E., & Ahmed, Y. A. (2022). Post-hatching Development of Ventriculus in Muscovy Duck: Light and Electron Microscopic Study. *Journal of Advanced Veterinary Research*, 12(1), 42-53.
- Raji A.R., & Asadi, M. (2013). Histological and histochemical study of the proventriculus and gizzard of the *Passer domesticus*. *Veterinary Journal (Pajouhesh & Sazandegi)*, 26(3): 2-9. [DOI: 10.22092/VJ.2013.101017]
- Sayrafi, R., & Aghagolzadeh, M. (2020). Histological and histochemical study of the proventriculus (*Ventriculus glandularis*) of common starling (*Sturnus vulgaris*). *Anatomia Histologia Embryologia*, 49(1): 105-111. [DOI: 10.1111/ahe.12495]
- Selvan, P.S., Ushakumary, S., & Ramesh, G. (2008). Studies on the histochemistry of the proventriculus and gizzard of post-hatch guinea fowl *Numida meleagris*. *International Journal of Poultry Science*, 7(11): 1112-1116.
- Shahrooz, R., Agh, N., Jafari, N., Kalantari, A., Jalili, R., & Karimi, A. (2018). Effects of Fish Oil Replacement with Vegetable Oils in Rainbow Trout (*Oncorhynchus mykiss*) Fingerlings Diet on Growth Performance and Foregut Histology. *Turkish Journal of Fisheries and Aquatic Sciences*, 18: 825-832. [DOI: 10.4194/1303-2712-v18\_6\_09]
- Vazhov, S.V., Bachtin, R.F., Barashkova, A.N., & Smelansky, I.E. (2013). On the Study of the Steppe Eagle in the Altai Kray, Russia. *Raptors Conservation*, 27: 162-171.
- Zhu, L., Wang, J.J., Shi, X.D., Hu, J., & Chen, J.G. (2013). Histological observation of the stomach of the yellow-billed grosbeak. *International Journal of Morphology*, 31, 512–515.

Received: 17.11.2022

Accepted: 19.12.2022

## Effects of uncontrolled queen importation and migratory beekeeping on the racial purity and spermatological parameters of honey bee (*Apis mellifera anatoliaca*) population in Central Anatolia

Abdulkadir Kaya<sup>1\*</sup> and Numan Akyol<sup>2</sup>

<sup>1</sup> Ph.D Student, Department of Reproduction and Artificial Insemination, Veterinary Faculty, Kırıkkale University, Kırıkkale, Türkiye and Institute of Health Sciences, Ankara University, Ankara, Türkiye

<sup>2</sup> Professor, Department of Reproduction and Artificial Insemination, Veterinary Faculty, Kırıkkale University, Kırıkkale, Türkiye

Received: 04.01.2023

Accepted: 09.04.2023

### Abstract

Widespread immigrant beekeeping activity, inadequate quality queen bee production and the excess of uncontrolled crossbreeding are great problems for the quality of honey bee races in Türkiye. However, the effects of uncontrolled crossbreeding on the spermatological parameters are not fully known. In this study, samples were analyzed in terms of morphometric parameters such as cubital index, hantel index and discoidal shift. Drones belonging to the same colonies were investigated in terms of spermatological parameters such as total motility, Plasma Membrane Integrity (PMI), Mitochondrial Membrane Potential (MMP) and spermatozoa concentration (SCON). The wing index values of the samples were similar to those of some races. Racial similarities rates were 50% Caucasian (*A. m. caucasia*), 49% Anatolian (*A. m. anatoliaca*), 24% Brown (*A. m. mellifera*), 13% Italian (*A. m. ligustica*) and 8% Carnolian (*A. m. carnica*). These results showed that the expected Anatolian had changed greatly race in the region and there is a danger of crossbreeding of bee races (*Apis mellifera anatoliaca*) in Central Anatolia Region. The averages of spermatological parameters were 85% motility, 82% PMI, 78% MMP and  $5.9 \times 10^9$ /ml sperm concentration. In addition, no significant correlative relationship was found between morphometric and spermatological parameters. In this study, the samples of honey bee colonies in the Central Anatolia Region showed random and uncontrolled crossbreeding among different races. The spermatological parameters were found to be sufficient for fertility but no significant relationship was detected statistically between the spermatological and morphometric parameters.

**Key words:** *Apis mellifera anatoliaca*, Drone, Morphometry, Sperm, Türkiye

### Introduction

Honey bees are included in the genus *Apis*, belonging to the order Hymenoptera and consist of 10 different species. These species are classified as *Apis florea*, *Apis*

*dorsata*, *Apis cerana*, *Apis mellifera*, *Apis nuluensis*, *Apis laboriosa*, *Apis koshevnikovi*, *Apis nigrocincta*, *Apis andreniformis* and *Apis binghami* (Engel,

\* **Corresponding Author:** Abdulkadir Kaya, Ph.D Student, Department of Reproduction and Artificial Insemination, Veterinary Faculty, Kırıkkale University, Kırıkkale, Türkiye and Institute of Health Sciences, Ankara University, Ankara, Türkiye  
E-mail: [abdulkadirkaya@kku.edu.tr](mailto:abdulkadirkaya@kku.edu.tr)



1999; Otis, 1996). Ruttner's (2013) study, honey bee samples were taken from different parts of the world, using the morphometric analysis method, and were classified into four main lineages: A (Africa), M (Western Europe), C (Eastern and Southeast Europe) and O (Middle East) major evolutionary lineage.

In his classification of the Anatolian peninsula, Rutter stated that there are Anatolian bees in the Central Anatolia, Aegean, Mediterranean and Black Sea Regions, Iranian bees in the Southeastern Anatolia Region, Caucasian bees in the Northeast Anatolia Region and Carniolan bees in the Thrace Region. Many studies using classical morphometry, geometric morphometry and molecular methods support this grouping (Alattal et al, 2019; Henriques et al, 2020; Modaber et al, 2019). In a study, race differences were observed in some regions and it was concluded that the reason for this was due to commercial queen sales and migratory beekeeping (Kambur and Kekeçoğlu, 2018).

For the morphometric classification of honey bee data, such as body size and shape, wing width and length, leg length, as well as genetic material are used. Honey bees can be classified using only the wing index parameters (cubital index, dumb-bell (hantel) index and discoidal shift values). For example, Romanian honey bees were classified using the wing index values (Cauia et al, 2008). Similarly, the same method was used for the morphometric analysis of bees in the Tomsk region of Russia (Ostroverkhova et al, 2015). In study, samples belonging to the Central Anatolia Region were examined in terms of morphometric parameters and honey bee race similarities were determined.

Spermatological parameters are an important factor for the reproductive ability of the honey bees and survival of the colony. It has been proven that these parameters are affected positively or negatively by many factors such as age of drones (Rhodes et al, 2011), body size

(Bratu et al, 2022), genetic factors (Rhodes et al, 2011), temperature (Stoian et al, 2020), nutrition (Zhao et al, 2021), colony management (Ben Abdelkader et al, 2014), seasonal fluctuations (Rhodes et al, 2011), diseases (Collins and Pettis, 2001), insecticides (Ciereszko et al, 2017), miticides (Johnson et al, 2013), semen cryopreservation (Loeza-Concha et al, 2019) and sperm retrieval method (Collins, 2004).

In this study, racial similarities and spermatological parameters of the colonies in the Central Anatolian region were determined. In addition, it was investigated whether these parameters were related to each other.

## Material and Methods

*Collection of bee samples:* All samples were collected from Central Anatolia, Türkiye (39° 50' 23.222" N 33° 30' 31.961" E). The apiaries where the samples were collected consist of centers and districts.

*Collection of drones:* Three colonies were randomly selected from 15 different apiaries in the Central Anatolia Region. Samples were collected in mid-July, with 50 samples from each hive. Thus, 50 drones were collected from each hive representing a study group. A total of 2250 drones and 45 colonies were used for the study.

*Collection of worker bees:* In the same way, 50 worker bees were obtained from the same hives from which drones were collected. In total, 2250 worker bee samples were obtained from 45 colonies. Each hive represented a study group.

*Morphometric analysis:* After the worker bee samples were kept on blotting paper for a while, their right front wings were dissected with the help of forceps and a stereo microscope (Euromex Nexius Zoom/Netherlands). The wings placed on the slide were fixed with the help of tape. Each wing photograph was transferred to the computer environment with the help of a camera adapted to a stereo microscope at the same position and suitable clarity. Forty

wings were used for each colony. Eight landmarks on the wing were marked with the help of the Tps Dig (v. 1.1) program. These values were analyzed as whether or not a relationship with the index values of the Caucasian, Anatolian, Brown, Italian and Carniolan races with the help of the CBeeWing program (American spelling) (Bouga et al, 2011). With the help of the program, the similarity of each colony to the mentioned races was obtained as a percentage (%).

The racial similarity percentages and wing index values (cubital index values, hantel index values and discoidal index values) were also statistically correlated with spermatological parameters (motility, PMB, MMP, SCON) (Table 2, Table 3).

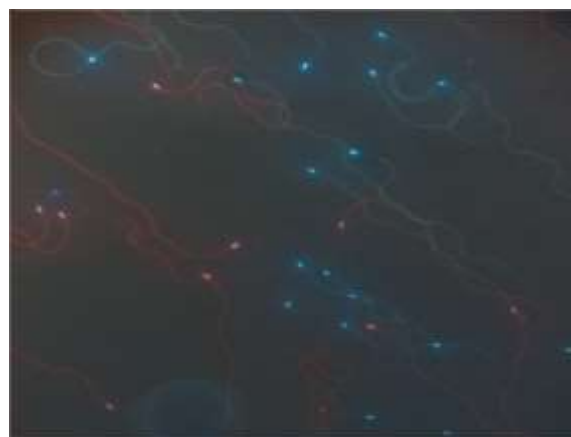
*Collection of semen from drones:* Artificial insemination device and stereo microscope were used for sperm collection. In the sperm collection process, the semen collection technique suggested by Cobey et al. (Cobey et al, 2013) was used. Averages of 30  $\mu$ l of semen were obtained from each colony.

*Motility:* The percentage of sperm motility was determined using a phase-contrast microscope (DM1000, Leica, Germany) with a heated stage at 33°C. Sperm diluted with Kiev buffer at a ratio of 1:30 (Murray et al, 2022). After, 5  $\mu$ l of diluted semen were determined by examining 40  $\times$  objective lens microscope slide and covered with a coverslip. Motile sperm rate was determined as a percentage (Quartuccio et al, 2020).

*Assessment of concentration of spermatozoa (SCON):* Pure sperm (10  $\mu$ l) was diluted with Hancock solution in the Eppendorf tube. Three or four times pipetting were applied to homogenize the sperm. Thoma slide and phase-contrast microscope was used for sperm counting (Ben Abdelkader et al, 2021).

*Assessment of plasma membrane integrity (PMI):* For the assessment of plasma membrane integrity, Hoechst 33342 (Sigma-Aldrich Catalog No: B2261) and PI

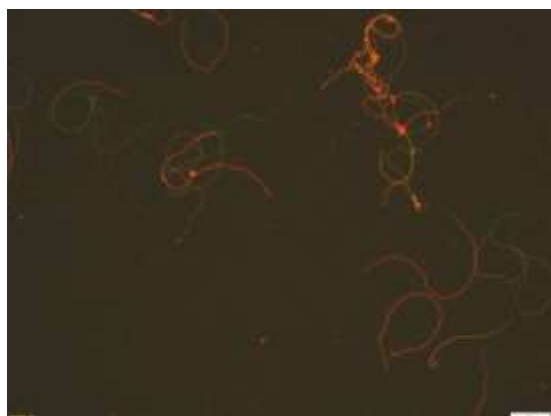
(Sigma-Aldrich Catalog No: B4170) fluorescent dyes were used. The semen was diluted with Kiev buffer to 100-200  $\times 10^6$  spermatozoon/ml. Firstly, 10  $\mu$ l Hoechst 33342 (5  $\mu$ g/ml) was added to 50  $\mu$ l diluted semen and incubated for ten minutes. After, 5  $\mu$ l PI (10  $\mu$ g/ml) and Hancock solution (3  $\mu$ l) were added to the solution before analysis. Afterward, a 5  $\mu$ l sample was taken from the solution and examined using an inverted microscope with fluorescence attachment (Leica DMI 3000b, Germany) and an "A" filter cube on a 40  $\times$  objective lens microscope slide and was then covered with a coverslip. During the evaluation, those with a blue color in the head of the spermatozoa were considered to have intact plasma membrane integrity and those with a red color were considered to have damaged plasma membrane (Figure 1). For each sample, 200 spermatozoa were counted with the help of the Cells Calculator (v. 2.2) program and plasma membrane integrity (%) was determined as a ratio (Morais et al, 2022).



**Figure 1. Assessment of plasma membrane integrity (Red: Dead Spermatozoon, Blue: Live Spermatozoon).**

*Assessment of mitochondrial membrane potential (MMP):* For the assessment of mitochondrial membrane potential, the JC-1 fluorescent dye (M34152, Molecular Probes, Eugene, OR, USA) was used. After the semen was diluted with Kiev buffer to be 100-200  $\times 10^6$ /ml, 5  $\mu$ l of JC-1 (2  $\mu$ M final concentration) was added to 50  $\mu$ l of

semen and incubated at 33°C for thirty minutes. Hancock solution (3 µl) was added to the solution before the analysis. Then, 5 µl sample was taken from the solution and examined using an inverted microscope with fluorescence attachment and a “I3” filter cube on a 40 × objective lens microscope slide and covered with a coverslip. The orange colored spermatozoa were evaluated as high MMP and the green colored spermatozoa were evaluated as low MMP (Figure 2). In this study, 200 spermatozoa were counted with the Cells Calculator program and determined as the rate (%) regarding high MMP.



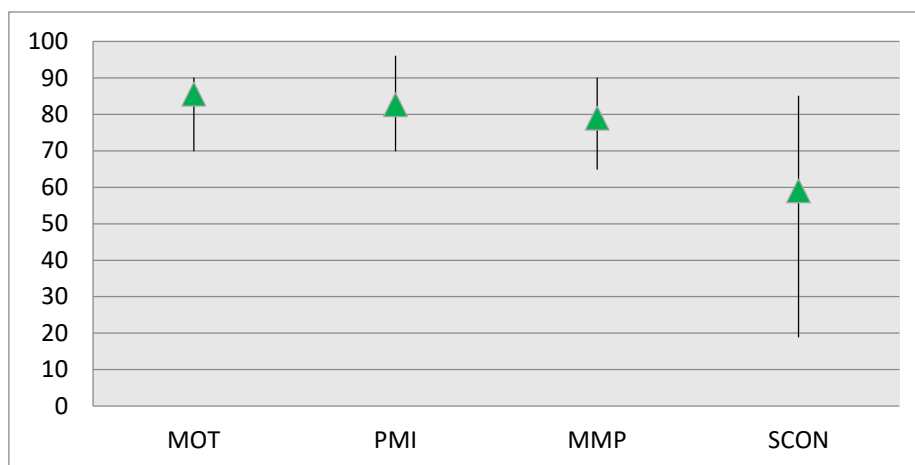
**Figure 2. Assessment of mitochondrial membrane potential (Orange: High mitochondrial membrane potential, Green: Low mitochondrial membrane potential).**

*Statistical analysis:* Statistical calculations of the obtained data were made using the SPSS package program (v. 15.6/2007). Differences between spermatological and morphometric parameters were determined by one-way ANOVA. The relationship between the parameters was determined using two-way correlation analysis.

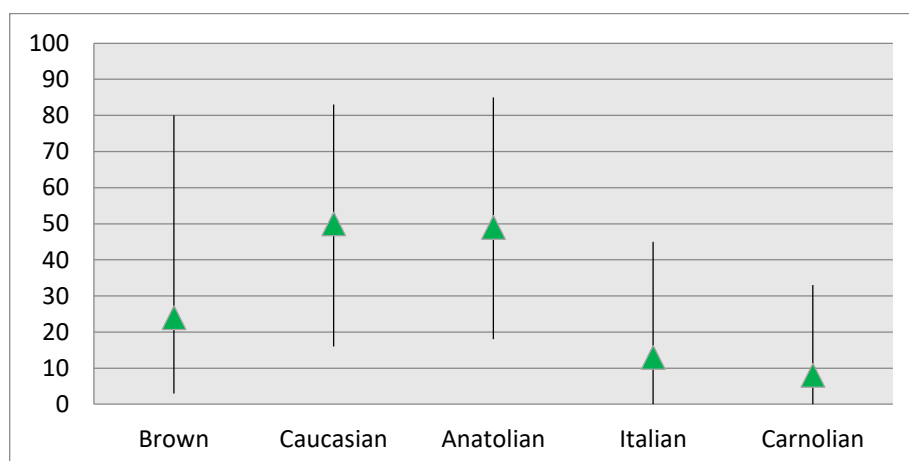
## Results

The findings of the study are shown in figures and tables. The minimum, maximum and mean values of spermatological and morphometric value are shown in Figures 3 and 4. According to the morphometric data, both the Anatolian race and the Caucasian race were the most common in the colonies, while the Carniolan honey bee race was the least common race (Figure 4). While the Anatolian race was the most common with a maximum similarity of 85% among the colonies, the Carniolan race was the least similar with 33% similarity. As shown in Figure 5, although the differences between beekeeping apiaries in terms of motility and PMI were significant ( $P \leq 0.05$ ), no difference was found in terms of high MMP and SCON ( $P > 0.05$ ). Regarding morphometry, only the difference in the similarity rate of the Anatolian race was found significant among the apiaries ( $P \leq 0.05$ ) (Figure 6). Although significant differences were not observed regarding the relationships between the spermatological and morphometric parameters obtained in this study, a low-level positive correlation was determined between motility and plasma membrane integrity, as shown in Table 1 ( $R = +0.35$ ). It was determined that there was no significant relationship between spermatological and morphometric parameters (Table 2) on the one hand, and that there was no significant relationship between wing index values and spermatological parameters (Table 3) on the other.

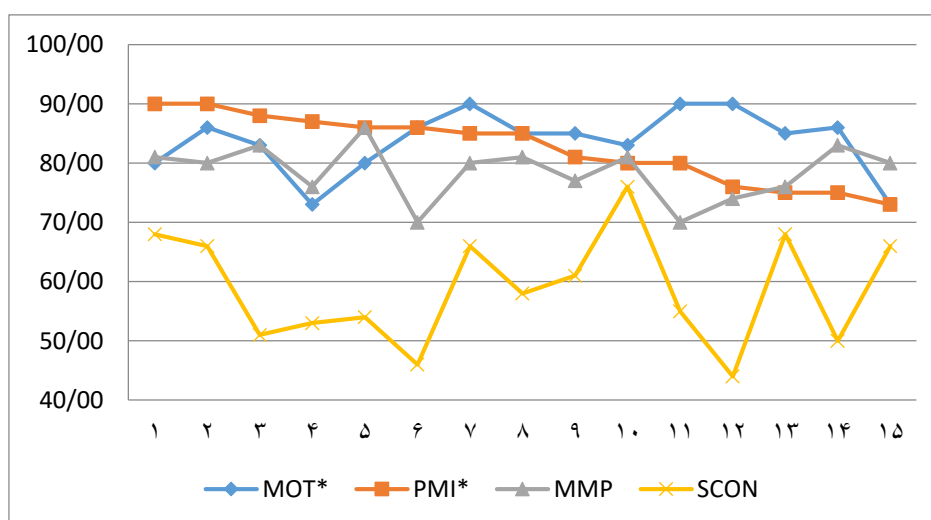




**Figure 3.** Minimum, maximum and mean percent values of spermatological parameters of colonies (The graph bar shows the minimum and maximum values. The mean value is indicated by the green arrowhead. MOT=% Motility, PMI= % Plasma Membrane Integrity, MMP= % High Mitochondrial Membrane Potential, SCON= Sperm Concentration ( $\times 10^8/\text{ml}$ )).



**Figure 4.** Minimum, maximum and mean percent values of morphometric parameters of colonies (The graph bar shows the minimum and maximum values. The mean value is indicated by the green arrowhead).



**Figure 5.** Situation beekeeping apiaries in terms of spermatological parameters (The vertical axis shows the parameter values. The horizontal axis shows the beekeeping apiaries. \*:Indicate statistical differences ( $P \leq 0.05$ ). MOT=% Motility, PMI= % Plasma Membrane Integrity, MMP= % High Mitochondrial Membrane Potential, SCON= Sperm Concentration ( $\times 10^8/\text{ml}$ )).

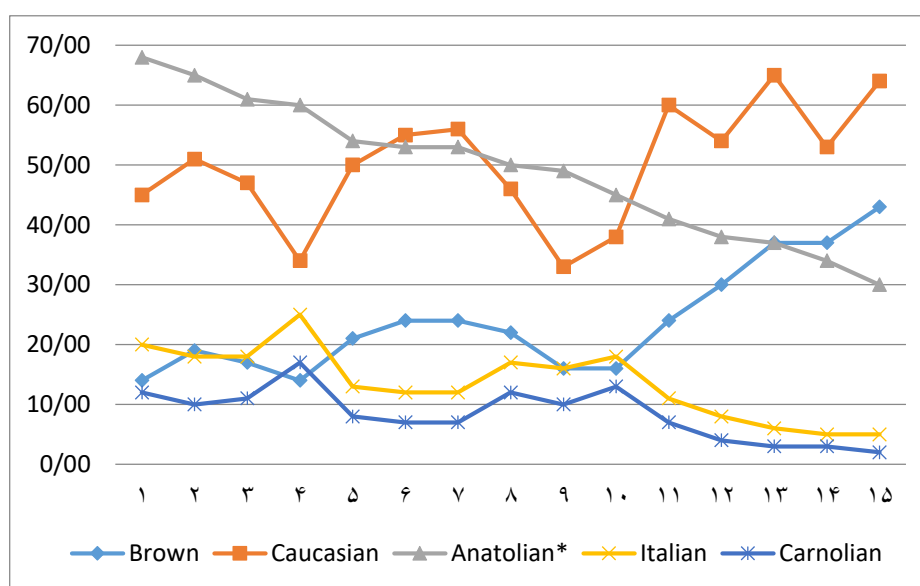


Figure 6. Situation beekeeping apiaries in terms of morphometric parameters (The vertical axis shows the parameter values. The horizontal axis shows the beekeeping apiaries.\*: Indicate statistical differences ( $P \leq 0.05$ ).)

Table 1. Correlative relationship level of spermatological parameters of colonies (R)

n = 45	Motility	PMI	High MMP
PMI	0.35*		
High MMP	- 0.11	0.15	
SCON	- 0.17	0.17	0.12

\*: Indicate statistical differences ( $P \leq 0.05$ ).

Table 2. Importance levels of the relationship between spermatological parameters and morphometric parameters (R)

n=45	Brown	Caucasian	Anatolian	Italian	Carnolian
Motility	-0.039	0.010	-0.095	-0.042	-0.038
PMI	-0.147	-0.014	0.064	0.075	0.090
High MMP	0.034	0.217	-0.044	-0.097	-0.088
SCON	0.235	0.268	-0.195	-0.287	-0.297

\*: Indicate statistical differences ( $P \leq 0.05$ ).

Table 3. Importance levels of the relationship between spermatological parameters and wing index values (R)

n=45	Motility	PMI	High MMP	SCON
Cubital index	-0.166	0.197	0.176	0.162
Dumb-bell index	0.073	0.054	-0.147	-0.259
Discoidal Shift	-0.021	-0.001	-0.172	-0.369

\*: Indicate statistical differences ( $P \leq 0.05$ ).

## Discussion

In this study, samples belonging to 45 different colonies were examined and accordingly mean, 85% motility, 82% PMI, 78% MMP and  $5.9 \times 10^9$ /ml SCON were determined. There are many studies examining the effects of spermatological parameters on reproductive performance. For example, in a study investigating the effects of spermatozoa motility on hatching rate, the rate of hatching from the eggs of bees that were artificially inseminated under suitable conditions using sperm with 50% or more motility was over 70% (Almeida and Espencer Egea Soares, 2002). Therefore, in this study, it is understood that the average motility value of 85% is appropriate in terms of hatching rate. In other studies on drone semen, plasma membrane integrity values in colonies of various races were obtained on average between 81% and 95% (Yániz et al, 2020). The plasma membrane integrity in the present research is appropriate with the values in the aforementioned studies.

In many studies, the drone spermatozoa concentration was between  $3.63 \times 10^6$  and  $11.9 \times 10^6$ /μl spermatozoa. In the present study, the SCON determined as  $5.9 \times 10^9$ /ml is parallel with other studies (Yániz et al, 2020).

Mitochondria have an important role in the energy supply necessary for spermatozoa to perform their physiological functions, thus giving important clues about their vital functions. The drone sperm needs a high MMP value to ensure the continuity of its movement during the migration from the spermatheca to the oviduct during the migration of the spermatheca after mating and during the egg-laying (Ciereszko et al, 2017; Slater et al, 2021). To our knowledge, no study was found on detecting high MMP in sperm with JC-1 fluorescent dye, but in two studies, using Rh 123 (Rhodamine 123) fluorescence dye, high MMP values were between 59% and 93% in different control groups (Alçay et al, 2022; Ciereszko et al,

2017). Since the high MMP value detected at the rate of 78% in this study is compatible with these data, it can be said that mitochondrial activity is at an appropriate level.

According to the morphometric analysis data performed on the worker bee samples of the same colonies, the average race rates were 50% Caucasian, 49% Anatolian, 24% Brown, 13% Italian and 8% Carniolan. This shows that the Anatolian bee race, which is expected to be resident in the Central Anatolia Region, has undergone significant crossing, either consciously or unconsciously. The change of bee race expected to be in the region may cause many problems. These can be counted as inability to adapt to seasonal changes, decrease in resistance to diseases, low wintering ability, incompatibility with vegetation and loss of yield. There is a danger of crossbreeding of bee races in Central Anatolia Region. The presence of the Caucasian race is at a similar rate to the Anatolian race in the region. The presence of many Caucasian queen bee producers in the nearby region, which is adjacent to Central Anatolia, may be the reason why the apiaries bought queen bees from these places. In addition, the propaganda about the honey-gathering and calm temperament of the Caucasian race for many years has also caused beekeepers to buy this race. Similarly, the Brown race may have been preferred in the region to reduce winter losses due to its good wintering ability. It is thought that the presence of Italian and Carniolan races in the region is because they were brought from abroad illegally or the hybrids of this race were favored by the beekeepers. Central Anatolia Region is located in the migration route of beekeepers belonging to the coastal regions, which have spent the winter season and early spring in the coastal areas. It is also possible to say that the race differences in the region are caused by widespread uncontrolled

mating through colonies of different races from different regions due to these migratory beekeeping activities.

When the data of the present study were evaluated, no data with a ratio of “r” value above -0.29 was found between spermatological and morphometric parameters. Based on these results, it is observed that the race changes do not have an effect on spermatological parameters. In studies investigating the relationship between race changes and spermatological parameters, the SCON of bees belonging to the Carniolan race was in the range of  $6.76\text{--}7.08 \times 10^9/\text{ml}$ . In a similar study, Duay et al. (Duay et al, 2002) found the SCON of the

same race as  $7.54 \times 10^9/\text{ml}$ . Koeniger et al. (2005) stated that the differences in SCON are due to environmental effects, individual differences or method differences and that the race difference does not correlate with to this. In the present study, it was observed that there were different levels of randomly-uncontrolled crossbreeding and satisfactory spermatological parameters.

Finally, it was determined that there was no relationship between uncontrolled crossbreeding and spermatological parameters. But confirming these results obtained with classical morphometry with some molecular and genetic analysis may provide more accurate results.

### Conflict of interest

The authors declare that they have no conflict of interest.

### Funding

This work was supported by Scientific Research Projects Coordination Unit of 12 Kırıkkale University. Project number 2020/026.

### References

- Alattal, Y., Alsharhi, M., Alghamdi, A., & Fuchs, S. (2019). Characterization of Socotra (Yemen) honey bees (*Apis mellifera*) using morphometric and genetic markers. *Bulletin of Insectology*, 72(2), 281–285.
- Alçay, S., Çakmak, S., Cakmak, I., Aktar, A., Yılmaz, M., Üstüner, B., Duman, M., Özkan, H., Akkaya, Y., & Sağırkaya, H. (2022). Honey bee drone (*Apis mellifera*) sperm cryopreservation with rainbow trout seminal plasma supplemented extenders. *Journal of the Hellenic Veterinary Medical Society*, 1(73).
- Almeida, R., & Espencer Egea Soares, A. (2002). Usage of green coconut water and different tissue culture media for in vitro honey bee semen storage (*Apis mellifera*; Hymenoptera: Apoidea). *Interciencia*, 27(6), 317–321.
- Ben Abdelkader, F., Çakmak, İ., Çakmak, S. S., Nur, Z., İncebıyık, E., Aktar, A., & Erdost, H. (2021). Toxicity assessment of chronic exposure to common insecticides and bee medications on colony development and drones sperm parameters. *Ecotoxicology*, 30(5), 806–817.
- Ben Abdelkader, F., Kairo, G., Tchamitchian, S., Cousin, M., Senechal, J., Crauser, D., Vermandere, J. P., Alaux, C., Le Conte, Y., Belzunces, L. P., Barbouche, N., & Brunet, J. L. (2014). Semen quality of honey bee drones maintained from emergence to sexual maturity under laboratory, semi-field and field conditions. *Apidologie*, 45(2), 215–223. <https://doi.org/10.1007/s13592-013-0240-7>
- Bratu, I. C., Igna, V., Simiz, E., Dunea, I. B., & Pătruică, S. (2022). The Influence of Body Weight on Semen Parameters in *Apis mellifera* Drones. *Insects*, 13(12), 1141.
- Bouga, M., Alaux, C., Bienkowska, M., Büchler, R., Carreck, N. L., Cauia, E., ... & Wilde, J. (2011). A review of methods for discrimination of honey bee populations as applied to European beekeeping. *Journal of apicultural research*, 50(1), 51–84.

- Cauia, E., Usurelu, D., Magdalena, L. M., Cimponeriu, D., Apostol, P., Siceanu, A., Holban, A., & Gavrila, L. (2008). Preliminary researches regarding the genetic and morphometric characterization of honeybees (*A. mellifera* L.) from Romania. *Scientific Papers Animal Science and Biotechnologies*, 41(2), 278–286.
- Ciereszko, A., Wilde, J., Dietrich, G. J., Siuda, M., Bąk, B., Judycka, S., & Karol, H. (2017). Sperm parameters of honeybee drones exposed to imidacloprid. *Apidologie*, 48(2), 211–222.
- Cobey, S. W., Tarpy, D. R., & Woyke, J. (2013). Standard methods for instrumental insemination of *Apis mellifera* queens. *Journal of Apicultural Research*, 52(4). <https://doi.org/10.3896/IBRA.1.52.4.09>
- Collins, A. M. (2004). Sources of variation in the viability of honey bee, *Apis mellifera* L., semen collected for artificial insemination. *Invertebrate Reproduction & Development*, 45(3), 231–237.
- Collins, A. M., & Pettis, J. S. (2001). Effect of varroa infestation on semen quality. *American Bee Journal*, 141(8), 590.
- Duay, P., De Jong, D., & Engels, W. (2002). Decreased flight performance and sperm production in drones of the honey bee (*Apis mellifera*) slightly infested by *Varroa destructor* mites during pupal development. *Genet. Mol. Res.*, 1(3), 227–232.
- Engel, M.S. (1999). The taxonomy of recent and fossil honey bees (Hymenoptera: Apidae; *Apis*), J. Hymenoptera Res., 8, 165–196.
- Henriques, D., Chávez-Galarza, J., SG Teixeira, J., Ferreira, H., J. Neves, C., Franco, T. M., & Pinto, M. A. (2020). Wing geometric morphometrics of workers and drones and single nucleotide polymorphisms provide similar genetic structure in the Iberian honey bee (*Apis mellifera iberiensis*). *Insects*, 11(2), 89.
- Johnson, R. M., Dahlgren, L., Siegfried, B. D., & Ellis, M. D. (2013). Effect of in-hive miticides on drone honey bee survival and sperm viability. *Journal of Apicultural Research*, 52(2), 88–95.
- Kambur, M., & Kekeçoğlu, M. (2018). The current situation of Turkey honey bee (*Apis mellifera* L.) biodiversity and conservation studies. *Biological Diversity and Conservation*, 11(1), 105–119.
- Koeniger, G., Koeniger, N., Tingek, S., & Phiancharoen, M. (2005). Variance in spermatozoa number among *Apis dorsata* drones and among *Apis mellifera* drones. *Apidologie*, 36(2), 279–284.
- Loeza-Concha, H., Domínguez-Rebolledo, Á., Copas-Medina, K., Vivas-Rodríguez, J., Escalera-Valente, F., & Ramón-Ugalde, J. (2019). Effect of egg yolk on sperm cryopreservation of drone (*Apis mellifera*). *Abanico Veterinario*, 9.
- Modaber, M., Nazemi Rafie, J., & Rajabi-Maham, H. (2019). Population genetic structure of native Iranian population of *Apis mellifera* meda based on intergenic region and COX2 gene of mtDNA. *Insectes Sociaux*, 66(3), 413–424.
- Morais, L. S., Araujo Neto, E. R., Silva, A. M., Marinho, D. E. L., Bezerra, L. G. P., Velarde, J. M. D. S., Silva, A. R., Gramacho, K. P., & Message, D. (2022). Sperm characteristics of Africanized honey bee (*Apis mellifera* L.) drones during dry and wet seasons in the Caatinga biome. *Journal of Apicultural Research*, 1–8.
- Murray, J. F., van der Horst, G., Allsopp, M., & Kotzé, R. C. M. (2022). A new fluorescent method to determine honey bee sperm motility parameters with computer-aided sperm analysis. *Journal of Apicultural Research*, 0(0), 1–9. <https://doi.org/10.1080/00218839.2022.2090729>
- Ostroverkhova, N. V., Konusova, O. L., Kucher, A. N., Kireeva, T. N., Vorotov, A. A., & Belikh, E. A. (2015). Genetic diversity of the locus COI-COI of mitochondrial DNA in honeybee populations (*Apis mellifera* L.) from the Tomsk region. *Russian Journal of Genetics*, 51(1), 80–90.
- Otis G.W. (1996). Distribution of recently recognized species of honeybees (Hymenoptera: Apidae: *Apis*) in Asia, J. of Kansas Entomol. Soc., 69, 311–333.
- Quartuccio, M., Cristarella, S., Scrofani, A., Biondi, V., De Majo, M., Mannarino, C., Cravana, C., Medica, P., & Fazio, E. (2020). The sperm of *Apis mellifera siciliana* and *Apis mellifera ligustica*: A preliminary and comparative note. *Journal of Apicultural Research*, 59(5), 1011–1016.
- Rhodes, J. W., Harden, S., Spooner-Hart, R., Anderson, D. L., & Wheen, G. (2011). Effects of age, season and genetics on semen and sperm production in *Apis mellifera* drones. *Apidologie*, 42(1), 29–38.
- Ruttner, F. (2013). *Biogeography and taxonomy of honeybees*. Springer Science & Business Media.
- Slater, G. P., Smith, N. M. A., & Harpur, B. A. (2021). Prospects in connecting genetic variation to variation in fertility in male bees. *Genes*, 12(8), 1251.

Stoian, R.-O., Păpuc, T., & Petrescu-Mag, I. V. (2020). The influence of temperature on the gonadal maturation of the drone of *Apis mellifera* (Insect: Hymenoptera: Apidae). *Animal Biology & Animal Husbandry*, 12(2), 49–69.

Yániz, J. L., Silvestre, M. A., & Santolaria, P. (2020). Sperm quality assessment in honey bee drones. *Biology*, 9(7), 1–16.

<https://doi.org/10.3390/biology9070174>

Zhao, H., Mashilingi, S. K., Liu, Y., & An, J. (2021). Factors influencing the reproductive ability of male bees: Current knowledge and further directions. *Insects*, 12(6), 529.

Received: 04.01.2023

Accepted: 09.04.2023

## The effect of Eggplant peel extract addition (*Solanum melongena*) on Farahani ram sperm after oxidative stress (freeze-thawing)

Hamidreza Khodadadi<sup>1</sup>, Mahdi Khodaei- Motlagh<sup>2\*</sup>, Mehdi Kazemi-Bonchenari<sup>2</sup>  
and Hamid Reza Momeni<sup>3</sup>

<sup>1</sup> MSc Student of Animal Physiology, Faculty of Agriculture and Natural Resource, Arak University, Iran

<sup>2</sup> Professor, Department of Animal Science, Faculty of Agriculture and Natural Resource, Arak University, Arak, Iran

<sup>3</sup> Professor, Department of Biology, Faculty of Science, Arak University, Arak, Iran

Received: 16.12.2022

Accepted: 08.02.2023

### Abstract

The aim of this study was to evaluate the effect of Eggplant peel extract on post-thawed ram sperm quality in a Tris-based extender. Semen was collected by artificial insemination vagina. Samples were pooled to prevent individual effects. Then ram semen samples were obtained, extended with Tris-based extender and supplemented with 0%, 2%, 4%, 6%, and 8% Eggplant peel extract. Later, samples were frozen by liquid nitrogen in the straw (0.25 ml). After thawing, sperm motility, viability (Nigrosine-eosin staining), membrane integrity with Hypo osmotic (Host) and morphology abnormality (Hancock test) were evaluated. Results showed that the value of 2% (62.4) of the Eggplant extract peel had a significant effect on sperm motility and membrane integrity after thawing. Also, the 2% and 4% of Eggplant peel extract groups had the most significant motility as compared to the control group and, the least motility was regarded as the most concentration of 8% of the Eggplant peel extract as compared to the control group. Thus, adding 2% and 4% of the Eggplant peel extract to Tris-based extender preserved Farahani ram sperm after thawing.

**Keywords:** Eggplant peel, extract, Semen

### Introduction

Sperm preservation is a crucial factor for the success of fertility in livestock (Ros-Santaella and Pintus, 2021). Ruminant sperm is vulnerable to free radicals caused by oxidative stress. The membranes of ruminant sperm cells contain large amounts of unsaturated fatty acids, which make these cells sensitive to the attack of free radicals. Freezing and thawing of sperms is an effective method to curb the production of free radicals in spermatozoa. Sperm motility has been reported to be about 60% 63% (Hiemstra et al, 2005; Saha et al, 2022)

after thawing in cattle, ram and poultry. Various plant products contain antioxidant compounds such as tannins, flavonoids, curcumanoids, coumarins, lignans, terpenoids and phenolics (Jeong et al, 2004). Several studies have shown that during the freeze-thaw process of sperm, the use of natural antioxidants had positive effects on sperm parameters (Zanganeh et al, 2013; Khodaei-Motlagh et al, 2014; DaghighKia et al, 2016). Eggplant has phenolic compounds as free radical scavengers (Cao et al, 1996). Research

\* **Corresponding Author:** Mahdi Khodaei- Motlagh, Professor, Department of Animal Science, Faculty of Agriculture and Natural Resource, Arak University, Arak, Iran  
E-mail: [mmotlagh2002@gmail.com](mailto:mmotlagh2002@gmail.com)



© 2020 by the authors. Licensee SCU, Ahvaz, Iran. This article is an open access article distributed under the terms and conditions of the Creative Commons Attribution-NonCommercial 4.0 International (CC BY-NC 4.0 license) (<http://creativecommons.org/licenses/by-nc/4.0/>).

shows that Eggplant contains about 10 types of superoxide coatings (SOS) (Hanson et al, 2006). Therefore the use of Eggplant extract in rats increased sperm concentration in the epididymis of the treated groups due to the antioxidant and protective potential of Eggplant extract against free radicals (Tiwari et al, 2009). The antioxidant properties of Eggplant extract show its activity in the face of elevated oxidative stress, for boosting sperm production by the secretion of more testosterone (Saalu et al, 2007).

Eggplant peel contains large amounts of antioxidants such as nasunin. This purple pigment belongs to the family of flavonoids and has strong antioxidant properties (Babu and Venkatesh, 2009). In the same line, this study was designed to investigate the effect of Eggplant peel extract on qualitative parameters of Farahani ram sperm after freezing.

## Materials and Methods

### Location, Animals and Semen collection

This research was carried out on the farm of Arak University with geographical characteristics of 341864760 (latitude), 496426590 (longitude) and 168722 (altitude) at breeding season (Autumn).

In this experiment, five fertile rams of Farahani breed (live weight  $60.5 \text{ kg} \pm 0.4 \text{ kg}$ , and 3.5 years old) were used. Semen was obtained twice a week by an artificial vagina ( $42-43^\circ\text{C}$ ). Then, rams were fed with one of three iso-nitrogenous and iso-energetic diets. An oestrus ewe was used to stimulate rams for optimal jumping and ejaculation. After, the semen samples were immediately transferred to the laboratory. Semen was evaluated and samples with volume  $>0.75 \text{ mL}$ ,  $> 80\%$  progressive motility and  $> 3 \times 10^9$  sperm/  $\text{mL}$  (concentration) were selected for examination. Finality, semen samples were pooled to eliminate individual differences between rams.

### Preparation of Eggplant peel extract

For the preparation of the Eggplant peel extract, collected Eggplant peel was dried at room temperature for 15 days. In brief, dried plants of Eggplant peel (50 g) were powdered, soaked in 400 mL of 70% ethanol for 24 hours and the mixture was filtered by Whatman (No.1 paper). Soxhlet system was used for the extraction of Eggplant peel extract. Ethanol was evaporated from the extract on a rotary evaporator at  $50^\circ\text{C}$ . The extract was then maintained at  $4^\circ\text{C}$  until used (Shahmohammadi et al, 2014).

### Extender preparation and cryopreservation

The Tris-based extender was composed of Tris, 3.634 g (hydroxymethyl-aminoethane, Merck 64271, Germany), fructose, 0.5g (Germany) (v/v), glycerol (5%) (w/v), citric acid, 1.99g (Merck Germany) (w/v), egg yolk (15%) (w/v), and penicillin (100,000 units internationally) in 100 ml distilled water used to reach the desired volume (Evans and Maxwell, 1987). Experimental treatments included five extenders supplemented with different levels (0, 2, 4, 6 and 8%) of Eggplant peel extract. The diluted semen was gradually cooled to  $4^\circ\text{C}$  for two hours and was subsequently aspirated into 0.25 mL French straws (IMV, L'Aigle, France) ( $4 \times 10^8$  spermatozoa/mL), sealed with polyvinyl alcohol powder and balanced at  $4^\circ\text{C}$  for one hour. Then, the straws were exposed to liquid nitrogen (LN) vapor (4-5 cm above the LN), for 10 min, plunged into the LN and stored until thawed and then used for the assessment of sperms. The thawing point was  $37^\circ\text{C}$  for duration of 45 seconds, and the frozen samples were capped in a water bath for 30 min for the process evaluation design and dissemination of the results.



## **Semen evaluation**

### **Motility**

The sperm parameters were evaluated at 0 and 1 h after thawing using computer-assisted semen analysis (CASA- using the Hamilton-Thorne motility analyzer). The variables analyzed included total motility (TM) and progressive motility (PM). At least 200 spermatozoa were analyzed for each evaluation (Bucak et al, 2010).

### **Membrane integrity**

Sperm membrane integrity was evaluated using the hypo-osmotic swelling test (HOST). Initially, 30  $\mu$ L of thawed diluted semen was added to 300  $\mu$ L of a 100mOsm hypo-osmotic solution (4.9 g sodium citrate+ 9 g fructose per liter of double-distilled water) in microtubes and incubated at 37 °C for 30 min. Following incubation, 10  $\mu$ L of the mixture was placed on a warmed glass slide (37 °C) under a cover glass and two hundred sperms were counted (CKX41; Olympus, Tokyo, Japan) at  $\times$ 400 magnification and then the percentage of sperms with swollen curved and tails was recorded (Jeyendran et al, 1992 and Garcia-Artiga, 1994).

### **Sperm abnormality**

Hancock solution (62.5 mL formalin (37%), 150 mL sodium saline solution, 150 mL buffer solution, and 500 mL bi-distilled water) were applied to assess spermatozoa with abnormal morphology of semen samples (Rasul et al, 2001) Three drops of each semen were added to eppendorf tubes containing one mL of Hancock solution. A drop of spermatozoa was placed on a slide and evaluated for sperm abnormalities under microscope at 40 $\times$  magnification.

### **Sperm viability**

Sperm viability (live/dead, %) was examined using eosin-nigrosin (nigrosin 10 g, eosin-Y 1.67 g, and sodium citrate 2.9 g, dissolved in 100 mL distilled water) staining method. The sperm suspension smears were prepared by mixing 10  $\mu$ L of sperm sample with 20  $\mu$ L of eosin-nigrosin

stain on a warm slide and immediately spreading the suspension (< 30s). After air drying, viable and nonviable sperms were assessed by counting 200 spermatozoa at the magnification of 400 $\times$  using phase-contrast microscopy (CKX41; Olympus, Tokyo, Japan) (Evans et al, 1987).

### **Statistical analysis**

All the data in this experiment were analyzed in a complete randomized design. All treatments were replicated five times. The normality of all the variables was tested with PROC UNIVARIATE on the residuals obtained from PROC MIXED using different times and its interaction with fixed effects. Repeated-measures ANOVA were performed on all the variables in PROC MIXED. The data were analyzed by MIXED procedure of SAS version SAS version 9.1 (SAS, 2004).  $P < 0.05$  was considered the significance level. The POLYANOVA model (linear, quadratic, and cubic) was employed for data due to having more comprehensive and informative results. The results were expressed in least squares means  $\pm$  standard error of the mean.

## **Results**

The effects of Eggplant peel extract on total and progressive motility parameters of frozen-thawed ram semen are presented in Table 1. Samples cryopreserved in 2 and 4% Eggplant peel extract had higher percent total (62.4% and 58.4%) and progressive (53.4% and 49.2%) motility compared to the other groups ( $P < 0.01$ ).

Table 1 shows the results of different concentrations of Eggplant peel extract supplementation on membrane integrity, viability and abnormality parameters of frozen-thawed ram spermatozoa. The number of viable sperm increased ( $P < 0.01$ ) in the extender containing 2% Eggplant peel extract (57.6%) compared to 6% and 8% extract groups (38.8% and 37.4%, respectively). The highest amount of spermatozoa plasma membrane integrity

(60.4%) was observed in 2% Eggplant peel extract treatments ( $P<0.01$ ).

Increase in the level of Eggplant peel extract resulted in a clear decline in sperm normality ( $P<0.01$ ) and the highest amount of abnormality (17.2%) was observed in 8% Eggplant peel extract treatments ( $P<0.01$ ).

The POLYANOVA model evaluation of the data in the current study showed that adding 2% Eggplant peel extract enhance, sperm quality; however, adding incremental levels of Eggplant peel extract linearly reduced sperm quality in the current experiment.

**Table 1. The effect of different concentrations of Eggplant (*Solanum melongena*) peel extract on post-thaw sperm motility, viability, membrane integrity, progressive and morphology of frozen-thawed Farahani ram spermatozoa**

Treatment (%)	Post-thawing				
	Motility	Viability	Membrane integrity	Progressive	Sperm abnormality
0	57.0±1.58 <sup>a</sup>	52.8±6.72 <sup>a</sup>	44.8±3.03 <sup>b</sup>	49.0±3.16 <sup>a</sup>	29.4±1.67 <sup>a</sup>
2	62.4±5.72 <sup>a</sup>	57.6±2.30 <sup>a</sup>	60.4±3.20 <sup>a</sup>	53.4±4.82 <sup>a</sup>	24.0±2.12 <sup>b</sup>
4	58.4±4.27 <sup>a</sup>	42.2±1.92 <sup>b</sup>	47.0±3.08 <sup>b</sup>	49.2±5.31 <sup>a</sup>	23.4±1.51 <sup>b</sup>
6	40.6±14.79 <sup>b</sup>	38.6±8.14 <sup>b</sup>	36.6±7.89 <sup>c</sup>	29.8±15.05 <sup>b</sup>	19.2±3.56 <sup>c</sup>
8	30.2±7.59 <sup>b</sup>	37.4±1.67 <sup>b</sup>	31.8±1.78 <sup>c</sup>	19.2±5.11 <sup>c</sup>	17.2±3.34 <sup>c</sup>
Statistical comparisons					
Linear	0.01	0.02	0.01	0.01	0.01
Quadratic	0.19	0.45	0.23	0.08	0.12
Cubic	0.65	0.78	0.10	0.14	0.38

<sup>a,b,c</sup> Different letters indicate mean values at each time of storage within post-thawing analysis ( $P < 0.05$ ).

## Discussion

This study was carried out for the first time to evaluate the effect of different concentration of Eggplant peel extract in semen extender containing Tris on post-thawed ram sperm quality. Freezing improved lipid peroxidation due to the curbing of the production of ROS which adversely influences the intercellular organelles (Maxwell and Watson 1996). Therefore, supplementation of extender may mitigate these damaging effects and provide a suitable protection for sperm. The percentage of motility for the groups that used the doses of 2 and 4% Eggplant peel extract in this study was significantly higher than that the control groups. Sperm survival and motility decreased significantly in the post-thawed process. The quality of frozen sperm can be improved by adding antioxidants (Hsieh et al, 2000). A little amount of reactive oxygen species (ROS) is produced by sperm under physiological conditions as required for sperm capacity and acrosomal reaction, but large amounts of ROS are negatively related to sperm

motility and number (Agarwal et al, 2006). In our study, the concentrations of 0% (control), 2% and 4% of Eggplant peel extract preserved sperm motility (57%, 62.4% and 58.4%, respectively) post-thawing. The antioxidant effects of Eggplant peel are not limited to its phenolic and anthocyanin compounds, and due to its vitamin C content, it is also important in reproduction (EunJu et al, 2011; Kadivec et al, 2015). This finding is in agreement with previous studies, which suggested the maintenance of motility during cryopreservation using antioxidants. In earlier studies, it was shown that *Solanum melon* fruits extract has an effect on the mitochondria found in the body of the spermatozoon where energy is synthesized in the form of adenosine triphosphate, which eventually increases sperm motility (Adelakun et al, 2020).

Our results are in line with the findings of Modaresi and Khodadadi, (2014) who found higher production sperm when the Aloe vera extract (contains vitamins C, A

and B) was added to treatments. Also, the use of thistle extract (like Eggplant) in rams increased sperm viability (Kistanova, 2005). Antioxidants in Eggplant peel extract (such as Nasonin) probably affected sperm progressive and improved membrane health and survival in 2% and 4% Eggplant peel extract compared to groups 6 and 8%.

Stresses due to the freeze-thaw process can compromise the health of plasma and acrosomal membranes, motility, fertility and the number of live sperm (Leboeuf et al, 2000). Freezing protection leads to changes in the DNA and cytoskeleton of sperm, which reduces its motility. Eggplant extract has an effect on sperm mitochondria (Duke, 1997). Ascorbic acid in the Eggplant extract is the first antioxidant defense line of plasma sperm and inhibits the oxidation of lipoproteins (Pursel and Graham, 1967).

In the present study, the highest concentration of ascorbic acid (8% Eggplant peel extract) significantly reduced total and progressive motility. It can be inferred that the excessive addition of ascorbic acid, like other antioxidants, to the diluent alters the properties of the plasma membrane, allowing lipoperoxidation to affect the membrane fluidity and the production of free radicals (Naijian et al, 2013). Adding high levels of the extract reduces sperm function by inhibiting the activity of enzymes involved in oxidation and reduction and upsetting the balance between antioxidant capacity and the production of free radicals (Roca et al, 2004).

The integrity of sperm membrane was significantly preserved using 2% of Eggplant peel extract (Table 1). Increased free radicals in semen caused lipid peroxidation and damage to the sperm membrane and its acrosome (Hidiroglou and Knipfel, 1984).

### **Acknowledgments**

This study is a part of MSc thesis research carried out in the Department of Animal sciences, Faculty of Agriculture and Natural Resources, Arak University. Authors impress fully thanks to all co-workers.

The use of Eggplant extract significantly increased the number of rat sperm (Tiwari et al, 2009). Sperm abnormalities were reported to be significant in this study. Free radicals in semen alter sperm motility and morphology (Agarwal et al, 2006).

The freeze-thaw process causes changes in the morphology of the sperm, which in turn cause damage to the acrosome membrane and the mitochondria of the sperm. This causes only a small percentage of sperm to have a healthy membrane and normal mitochondrial activity after cryopreservation, resulting in fewer sperm counts after cryopreservation (Holt and North, 1994). Addition of aqueous extract of rosemary containing polyphenols to goat semen extender improved the parameters of motility, viability, plasma membrane integrity and reduced the number of morphological abnormalities of sperm. Furthermore, it protected goat sperms from free radical damage (Zanganeh et al, 2013).

Many plant extracts contain biochemical compounds such as flavonoids and phenolic compounds that have antioxidant properties and prevent cellular damage caused by free radicals (Sefidkon and Jamzad, 2005). The thawing process can damage the cytoplasm of the cell, the cytoplasmic membrane, and the structure of the DNA, leading to impaired motility, sperm survival, and infertility (Leboeuf et al, 2000). Oxidative stress can be reduced by antioxidants containing phytonutrients such as flavonoids, anthocyanins and phenolic compounds (Babu and Venkatesh, 2009).

The findings of this study showed that the adding of Eggplant peel extract did not change compared to the control treatment in Farahani ram semen. Adding incremental levels of 6 and 8% Eggplant peel extract was shown to have negative effects on sperm quality characters.

## Conflict of interest

The authors declared no conflict of interest.

## Funding

The current research was supported by the Arak University.

## References

- Adelakun, S.A, Ukwenya, V.O., Akingbade GT, Omotoso OD, Aniah JA. 2020. Interventions of aqueous extract of Solanum melongena fruits (garden eggs) on mercury chloride induced testicular toxicity in adult male Wistar rats. *Biomedical Journal*, 43,174-182.
- Agarwal, A., Gupta, S., Sikka, S., 2006. The role of free radicals and antioxidants in reproduction. *Current Opinion in Obstetrics and Gynecology*, 18(3), 325-332.
- Arora, A., Byrem, T.M., Nair, M.G., Strasburg, G.M., 2000. Modulation of liposomal membrane fluidity by flavonoids and isoflavonoids. *Archives of Biochemistry and Biophysics*, 373(1), 102-109.
- Babu, B.N.H., Venkatesh, Y.P. 2009. Clinico-immunological analysis of eggplant (*Solanum melongena*) allergy indicates preponderance of allergens in the peel. *World Allergy Organ Journal*, 2(9), 192-200.
- Bucak, M.N., Sarıözkan, S., Tuncer, P.B., Sakinand, F., Ateşşahin, A., Kulaksız, R., Çevik, M., 2010. The effect of antioxidants on post-thawed Angora goat (*Capra hircus ancyrensis*) sperm parameters, lipid peroxidation and antioxidant activities. *Small Ruminant Research*, 89, 24-30.
- Cao, G., Sofic, E., Prior, R.L., 1996. Antioxidant capacity of tea and common vegetables. *Journal of Agricultural and Food Chemistry*, 44(11), 3426-3431.
- Daghighi Kia, H., Farhadi, H., Ashrafi, R., Mehdipour, M., 2016. Anti-oxidative effects of ethanol extract of *Origanum vulgare* on kinetics, microscopic and oxidative parameters of cryopreserved Holstein bull spermatozoa. *Iranian Journal of Applied Animal Science*, 6(4), 901-907.
- Duke, J., 1997. The ultimate compendium of Natural remedies from the world's foremost Authority on healing and herbs. *The Green Pharmacy Rodale press*, 248, 334, 463, 481.
- Evans G, Maxwell WMC, Salmons S. 1987. Artificial insemination of sheep and goats. Butterworths. No. Ed. 2 pp. xi + 194 pp.
- EunJu J, EunKyung J, YoungHong J, SeungCheol L. 2011. Antioxidant activity of different parts of eggplant. *Journal of Medicinal Plants Research*, 5(18), 4610-4615.
- Garcia-Artiga C. 1994. Test de endosmosis en ovino. In: 7<sup>th</sup> international meeting on animal reproduction. Murcia. Spain. PP: 77-81.
- Hanson PM, Yang RY, Tsou SC, Ledesma D, Engle L, Lee TC. 2006. Diversity in eggplant (*Solanum melongena*) for superoxide scavenging activity, total phenolics, and ascorbic acid. *Journal of Food composition and Analysis*, 19(6-7), 594-600.
- Hidiroglou, M., Knipfel, J., 1984. Zinc in mammalian sperm: a review. *Journal of Dairy Science*, 67(6), 1147-1156.
- Hiemstra, S.J., van der Lende, T., Woelders, H., 2005. The Potential of Cryopreservation and Reproductive Technologies for Animal Genetic Resources Conservation Strategies. Villa Gualino, Turin, Italy.
- Holt, W.V., North, R.D., 1994. Effects of temperature and restoration of osmotic equilibrium during thawing on the induction of plasma membrane damage in cryopreserved ram spermatozoa. *Biology of Reproduction*, 51, 414-424.
- Hsieh, L., 2000. Cryopreservation of human sperm within mouse empty zonapellucida. *Fertility and Sterility Journals*, 79(4), 694-702.
- Jeong, S.Y., Kim, D.R., Kim, K.C., Nam, D.U. and Ahn, Lee S.C., 2004. Effect of seed roasting on the antioxidant activity of defatted sesame meal extracts. *Food Chemical Toxicology*, 69, 377-381.
- Jeyendran, R.S., Van der Ven, H.H., Zaneveld, L.J., 1992. The hypoosmotic swelling test: an update. *Archive of Andrology*, 29(2), 105-116.
- Kadivec, M., Kopjar, M., Žnidarčič, D., Požrl, T., 2015. Potential of eggplant peel as by-product. *Acta alimentaria*, 44(1), 126-131.
- Kistanova, E., Zlater, H., Karcheva, V., Kolev, A., 2005. Effect of plant *Tribule terrestris* extract on reproductive performances of Rams. *Biotechnology in Animal Husbandry*, 21(1-2), 55-63.
- Leboeuf, B., Restall, B., Salamon, S., 2000. Production and storage of goat semen for artificial insemination. *Animal Reproduction Science*, 62(1-3), 113-141.

- Maxwell, W., Watson, P., 199. Recent progress in the preservation of ram semen. *Animal Reproduction Science*, 42(1-4):55-65.
- Modaresi, M., Khodadadi, A., 2014. The Effects of Aloe vera Extract on Reproductive Parameters in Mice. International Conference on Biological, Environment and Food Engineering, Bali (Indonesia).
- Motlagh, M.K., Sharafi, M., Zhandi, M., Mohammadi-Sangcheshmeh, A., Shakeri, M., Soleimani, M., Zeinoaldini, S., 2014. Antioxidant effect of rosemary (*Rosmarinus officinalis* L.) extract in soybean lecithin-based semen extender following freeze-thawing process of ram sperm. *Cryobiology*, 69(2), 217-22.
- Naijian, H.R., Kohram, H., Zare H., Sharafi, M., Bucak, M.N., 2013. Effects of different concentrations of BHT on microscopic and oxidative parameters of Mahabadi goat semen following the freeze-thaw process. *Cryobiology*, 66(2), 151-155.
- Pursel VG, Graham EF. 1967. Phospholipids of bovine spermatozoa and seminal plasma. *Journal of Reproduction and Fertility*, 14, 203-211.
- Rasul, Z., Ahmad, N., Anzar, M., 2001. Changes in motion characteristics, plasma membrane integrity, and acrosome morphology during cryopreservation of buffalo spermatozoa, *Journal of Andrology*, 22. 278e283.
- Roca, J., Gil, MA, Hernandez, M., Parrilla, I., Vazquez, J.M., Martinez, E.A., 2004. Survival and fertility of boar spermatozoa after freeze-thawing in extender supplemented with butylatedhydroxytoluene. *Journal of Andrology*, 25(3), 397-405.
- Ros-Santaella, J.L., Pintus, E., 2021. Plant Extracts as Alternative Additives for Sperm Preservation. *Antioxidants*, 10(5), p.772.
- Saalu, L.C., Oluyemi, K.A., Omotuyi, I.O., 2007. A-Tocopherol (vitamin E) attenuates the testicular toxicity associated with experimental cryptorchidism in rats. *African Journal of Biotechnology*, 6(12), 1373-1377.
- Saha, A., Asaduzzaman, M. and Bari, F.Y., 2022. Cryopreservation Techniques for Ram Sperm. *Veterinary Medicine International*, Article ID 7378379.
- Sapanidou, V.G., Margaritis I., Siahos, N., Arsenopoulos, K., Dragatidou, E., Taitzoglou, I.A., 2014. Antioxidant effect of a polyphenol-rich grape pomace extract on motility, viability and lipid peroxidation of thawed bovine spermatozoa. *Journal of Biological Research Thessaloniki*, 21(1), 19.
- SAS Institute. 2004. SAS ® /STAT Software, Release 9.1. SAS Institute, Inc., Cary, NC. USA.
- Sefidkon F., Jamzad Z., 2005. Chemical composition of the essential oil of three Iranian *Satureja* species (*S. mutica*, *S. macrantha* and *S. intermedia*). *Food Chemistry*, 91(1), 1-4.
- Shahmohammadi, S.H., Khosravi, M., Hajizadeh, A., 2014. The effect of *Salvia officinalis* on malondialdehyde concentration, in the face of oxidative stress induced by injection of streptozotocin (ICV) in male rats. *Medical Science. Journal of Islamic Azad University Tehran*, 23(4), 225-229.
- Tiwari, A., Jadon, R.S., Tiwari, P., Nayak, S., 2009. Phytochemical Investigations of Crown of *Solanum melongena* fruit. *International Journal of Phytomedicine*, 1, 9-11.
- Zanganeh, Z., Zhandi, M., Zare-Shahneh, A., Najafi, A., Nabi, M.M., Mohammadi-Sangcheshmeh, A., 2013. Does rosemary aqueous extract improve buck semen cryopreservation. *Small Ruminant Research*, 114(1), 120-125.

Received: 16.12.2022

Accepted: 08.02.2023

## The identification of the primordial germ cells in the male gonads of pheasant (*Phasianus colchicus*) embryos using histochemical and immunostaining techniques

Farhad Mohammadi Gheshlagh<sup>1</sup>, Azam Hosseini<sup>2</sup> and Abolghasem Nabipour<sup>3\*</sup>

<sup>1</sup> PhD Student of Histology, Faculty of Veterinary Medicine, Ferdowsi University of Mashhad, Mashhad, Iran

<sup>2</sup> PhD Graduated of Histology, Faculty of Veterinary Medicine, Ferdowsi University of Mashhad, Mashhad, Iran

<sup>3</sup> Professor, Department of Basic Sciences, Faculty of Veterinary Medicine, Ferdowsi University of Mashhad, Mashhad, Iran

Received: 05.09.2022

Accepted: 22.11.2022

### Abstract

The purpose of this research was to look for primordial germ cells in male gonads at various stages of the pheasant embryos. Primordial germ cells are cells that differentiate into sperm or oocyte and are important for the transmission of genetic information across generations. In this study, embryos were extracted in embryonic days 8-24. The primordial germ cells were recognized in paraffin and resin tissue sections on days 8 to 10 of embryogenesis owing to the specific properties of these cells, which included a large size, large nucleus and nucleolus, and little cytoplasm. The primordial germ cells in the testes were identified using histochemical and immunostaining techniques. Periodic Acid-Schiff method, immunohistochemistry using stage-specific embryonic antigen-1, alkaline phosphatase and toluidine blue staining were used to identify primordial germ cells. Germ cells were detected only in semithin sections at older ages (10-24 days). Moreover, the response of these cells was negative, at all ages, to alkaline phosphatase, Periodic Acid-Schiff staining and stage-specific embryonic antigen-1 reaction. The findings of this study revealed that primordial germ cells in the testicular tissue of pheasant embryos of all ages tested responded adversely to histochemical and immunohistochemical techniques. Also, this study showed that routine staining of hematoxylin and eosin and using semithin sections are suitable for the histological diagnosis of these cells.

**Key words:** Primordial germ cells, Immunohistochemistry, Alkaline phosphatase, Pheasant, Male gonads

### Introduction

In the fields of growth biology and stem cell biology, bird embryos have become a popular model (Stern, 2005). Among birds, regarding pheasant, meat contains low fat and cholesterol and high content of fatty acids is essential; hence, it is considered a valuable bird in terms of economy (Adamski and Kuźniacka, 2006). Their reproductive organs have distinct features. Female gonads and accessory embryonic

oviducts grow asymmetrically, while male gonads develop symmetrically (Smith and Sinclair, 2004). Pheasant embryonic gonadal development is comparable to that of other bird species. The process of generating embryonic gonads is known as "gonadogenesis" (Clinton and Haines, 2001). Gonadogenesis in vertebrates starts with the migration of primordial germ cells (PGCs) (Y Nakamura et al, 2007). PGCs

\* **Corresponding Author:** Abolghasem Nabipour, Professor, Department of Basic Sciences, Faculty of Veterinary Medicine, Ferdowsi University of Mashhad, Mashhad, Iran  
E-mail: [nabipour@um.ac.ir](mailto:nabipour@um.ac.ir)



emerge from the extraembryonic area (on the first day of pregnancy) and travel to the genital ridges, where they settle down (Y Nakamura et al, 2007). PGCs in mammals are produced from the endodermal cells of the hindgut's yolk sac (Bendel–Stenzel et al, 1998). Avian PGCs, on the other hand, start in the central zone of the blastodisc (Y Nakamura et al, 2007) and move anteriorly to the extraembryonic area known as the "germinal crescent" (Y Nakamura et al, 2007). PGCs penetrate blood vessels and extravasate from the endothelium of capillaries towards the genital ridges by amoeboid movement, (Y Nakamura et al, 2007) employing pseudopodia or filopodia-like processes (Gomperts et al, 1994). In the developing gonads, established PGCs with contributions from the coelomic epithelium and mesonephroi give birth to a variety of cell types (Carlon, 1985). PGCs and surrounding somatic cells induce the formation of bipotential (indifferent or undifferentiated) gonads in developing gonads (Carlon, 1985). Finally, sexually differentiated gonads seem to develop and generate functional gametes as adult gonads (Clinton and Haines, 2001). Genetic information is passed down via the generations through PGCs which are considered the immortal cells (Kim and Han, 2018). Therefore, the study and identification of PGCs to preserve genetic resources to be used in basic biological research are considered an important goal (Yoshiaki Nakamura et al, 2013). Another importance of PGCs is due to the chance of obtaining male germ cells from transferring female ones to male embryo (Tagami et al, 1997). Considering the signals from their condition, PGCs are differentiated into gametes of each sex (Wylie, 1999). PGCs with large size and large spherical nuclei are identified using histochemical markers, including Periodic Acid Schiff (PAS), resulting in glycogen or immunohistochemical staining in the cell surface antigen (Ginsburg and Eyal-Giladi, 1986). One of the main markers to

distinguish the pluripotent embryonic stem and associated cells is alkaline phosphatase (Štefková et al, 2015). As a cell surface glycoprotein, stage-specific embryonic antigen-1 (SSEA-1) can be utilized as another marker to detect PGCs in mammals and chickens (Yön Ertuğ and Akbulut, 2015). Therefore, to study PGCs, staining and special methods are needed to distinguish them from other embryonic cells.

## **Materials and Methods**

### **Ethics**

Ethical approval for this research was confirmed by the Ethics Committee of Ferdowsi University of Mashhad (IR.UM.REC.1399.136). All experiments were done based on relevant guidelines and regulations.

### **Separation of embryos and testes**

Fertile pheasant (*Phasianus colchicus*) eggs were provided from a commercial farm. The eggs were incubated at a temperature of 37 °C and a relative humidity of 60%. An incubator rotated the eggs every 60 minutes to prevent the embryo from adhering to the eggshell. In the same vein, the goal of this research was to find out what traits PGCs have on embryonic days (ED) 8, 13, 17, and 24 (day of hatching). At each ED, after separating the embryo from the yolk, it was washed with a fixator and dissected under a stereomicroscope and the testes were removed. The removed testes were then fixed in 4% paraformaldehyde (PFA) for 24 hours. Other samples of testes were fixed in a Gender solution for 8 hours and then washed with 80% ethanol. The removed tissues were later dehydrated in ethanol (70%, 80%, 90%, and 100%) and purified xylene. They, then, were fixed in paraffin (Merck, Germany) and cut by a rotating microtome (Leica RM 2145; Germany) (cross-sections, 5 µm). Also, samples were taken to prepare semithin resin sections (size approx.1mm) and fixed in 2%

glutaraldehyde in 1M buffer cacodylate to embed epoxy resin. After histochemical and immunohistochemical staining, the micrographs were taken with a BX51 light microscope (Olympus; Japan) equipped with a camera (DP12, Olympus, Japan).

#### **Immunohistochemical staining**

The paraffin was removed from the tissue slices using xylene and rehydrated in an ethanol series that had previously been graded. It was then rinsed in phosphate buffered saline (PBS). To limit endogenous peroxidase activity, sections were treated with 0.3 percent H<sub>2</sub>O<sub>2</sub> in PBS at room temperature for 15 minutes. They were then rinsed in PBS before being blocked in 10 percent bovine serum albumin (BSA/PBS) to reduce non-specific antibody binding. The slides were then treated at 4°C overnight with the primary antibody, stage-specific embryonic antigen-1 (SSEA-1) (1:300; R&D; USA). The secondary antibody, donkey anti-mouse immunoglobulin M (IgM), was incubated for 1 hour at room temperature with HRP (1:500, Jackson ImmunoResearch Inc. USA). The slides were cleaned three times with PBS before being incubated in a dark, humid environment for 5 minutes with diaminobenzidine (DAB). Later, the sections were counterstained with hematoxylin. Ultimately dehydrated, cleaned with xylene, and mounted with Entellan (Merck, Germany). To incubate the samples as a negative control, only a secondary antibody was included (by omitting the primary antibody).

#### **Alkaline phosphatase staining**

To eliminate all the paraffin from the tissue samples, the solvent xylene was utilized. The segments were then rehydrated using the ethanol series. The alkaline phosphatase (ALP)-treated sections were substrate at room temperature for 30 minutes in a dark and humid chamber. Deionized water was used to clean the slides. Eventually, the sections were

dehydrated and mounted with Entellan. Alkaline phosphatase substrate consisted of 33 µl stock 5% Bromo-4-Chloro-3-indolyl-phosphate (BCIP) (Thermo Scientific, USA) in 100% Dimethylformamide (DMF), 66 µl stock 5% Nitro-blue tetrazolium chloride (NBT) (Thermo scientific; USA) in 70% DMF (Merck; Germany), and 10 ml of buffer substrate. The buffer substrate consisted of a PH of 9.5, with 10 mM NaCl (Merck; Germany), 5 mM Magnesium chloride (MgCl<sub>2</sub>) (Merck; Germany) and 100 mM (hydroxymethyl) aminomethane (TRIS) (Sigma Aldrich-TM, USA).

#### **Histological assessment**

For the histological observation, paraffin samples were stained using hematoxylin and eosin (H&E) and PAS (Merk, Germany) to detect the glycogen granules in the cytoplasm of PGCs (Suvarna, Layton, and Bancroft, 2018).

Also, samples were used to make semithin resin sections (1µm thickness) that were fixed in 2% glutaraldehyde in 1 M buffer cacodylate before being embedded in epoxy resin.

The glutaraldehyde-fixed specimens were refixed in a 1 M cacodylate buffer with 1% osmium tetroxide solution. Before being soaked in epoxy resin (TAAB Laboratories Equipment Ltd, UK) and cut into 1-µm sections, the samples were dehydrated using the progressive lowering temperature (PLT) process.

The lumen of the tubules and the cells around the lumen were next examined using toluidine blue staining (Kuo, 2008).

#### **Results**

In 8-24-day-old embryos, dirty-white testes were seen on the ventral surface of mesonephros kidneys. The testes inclined and were tightly spaced along the body's median plane from the cranial border to the midportion of the kidneys (Figure 1f). In 8-day-old embryo, PGCs were easily detected by examining the slides of paraffin and resin

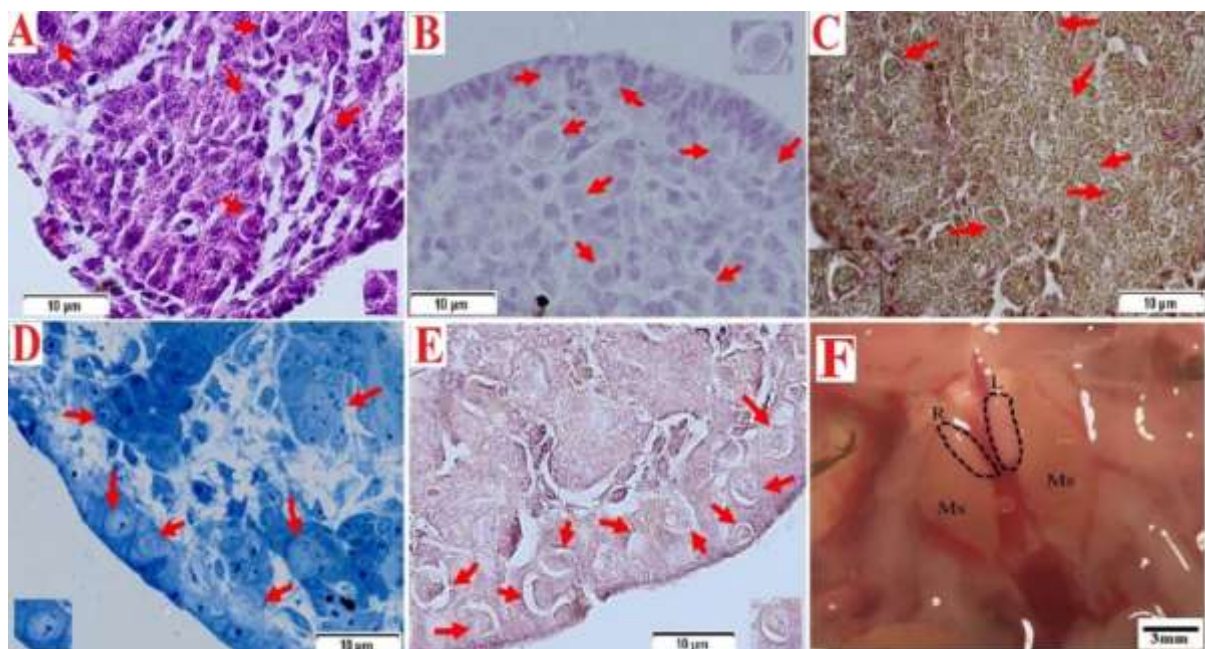


sections stained by H&E and toluidine blue due to their shape (Figures 1A and 1D). Germ cells can be distinguished from other cells with larger cells and nucleus and clearer cytoplasm. At this stage, the interaction with PAS was negative or very weak (Figure 1C). The histological samples of the rectum of rabbit were used as a positive control for PAS stain (Figure 5E). SSEA-1 and alkaline phosphatase reactions were negative (Figure 1B and 1E). The histological samples of chick liver at one-day age were used as a negative control for the ALP enzyme, by exposing the sample to a temperature of 60 °C for an hour without staining the nucleus (Figure 5C). The liver from the same stage was used as a positive control for the ALP enzyme (Figure 5D).

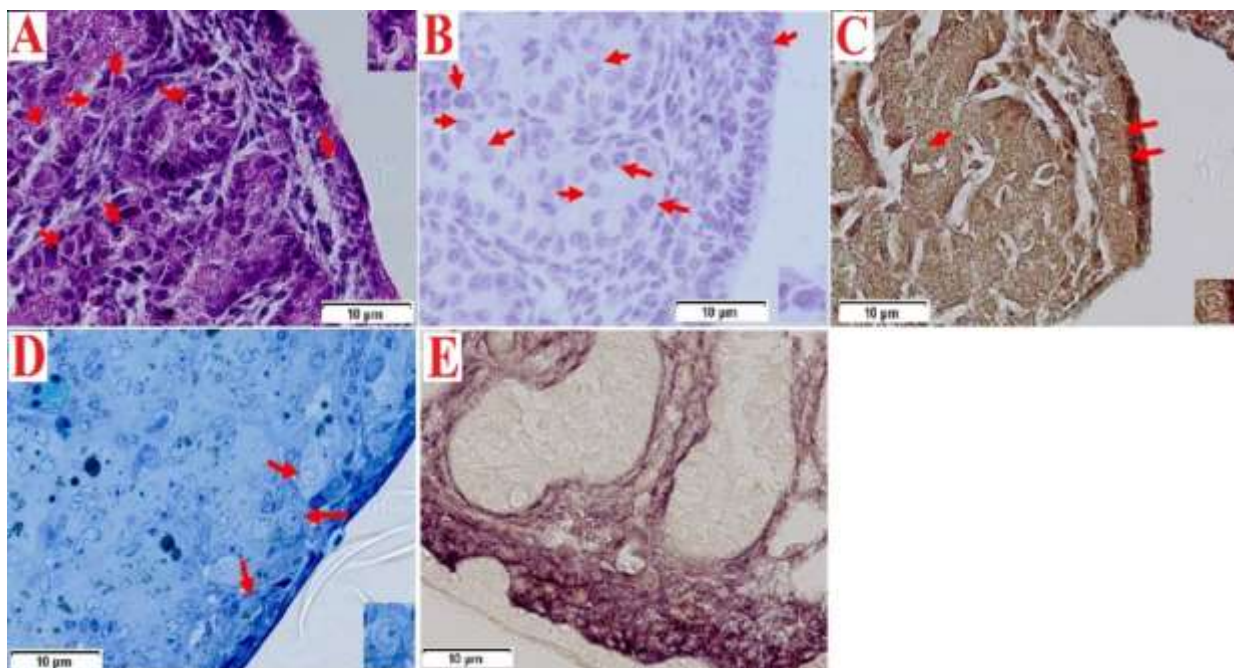
In 13 and 17 days old, in anti-SSEA-1 antibody-stained slides, in all phases, PGCs were negative (Figures 2B and 3B). Primordial germ cells could be differentiated from other cells in the gonads with their specific morphology even in

slides which did not have positive staining with SSEA-1 antibody. The nucleus of these cells was round and very large, occupying most of the cytoplasmic space. The samples of gonad from chick embryo at stage 28 Hamburger and Hamilton (H&H) were used as a positive control for SSEA-1 antibody; germ cells in this stage positively reacted with SSEA1 at the end of staining (Figure 5B). The same stage was used as a negative control (Figure 5A), by omitting the primary antibody, and the research specimens were only incubated using the secondary antibody.

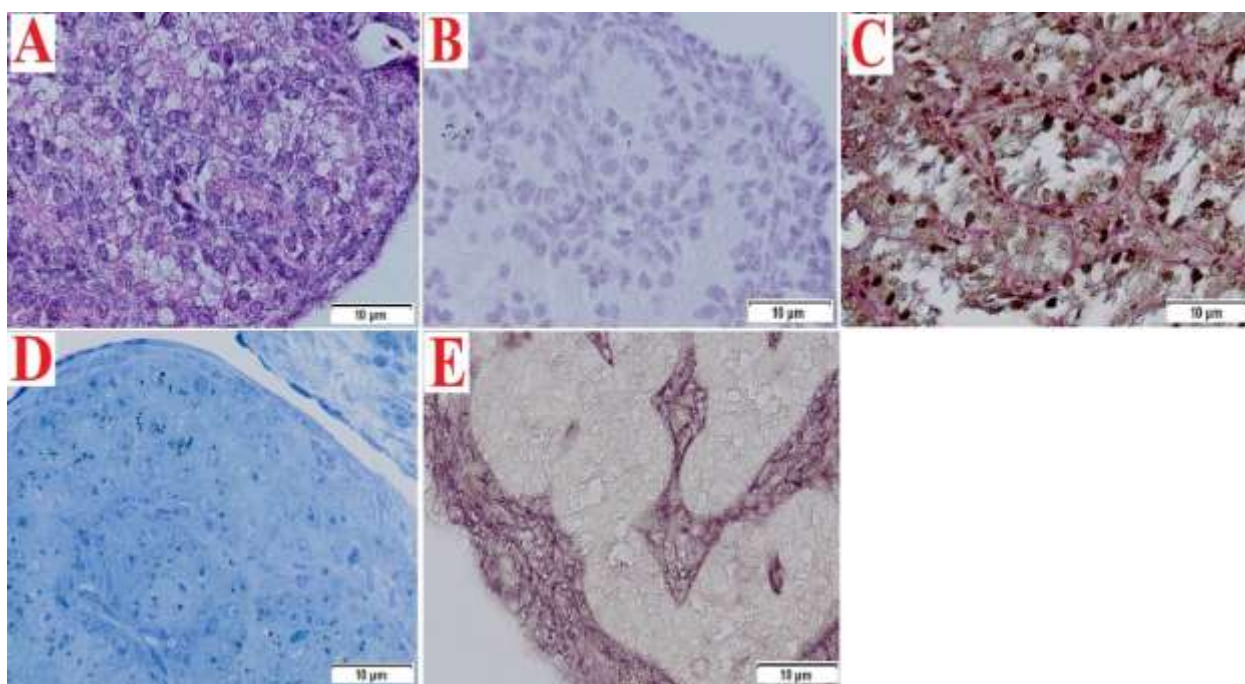
In the embryonic days 13 and 17, PGCs negatively reacted with the alkaline phosphatase enzyme (Figure 2E and 3E). In all the three embryonic stages, the primordial germ cells showed a negative reaction to PAS stain (Figures 2C, 3C and 4B). At 24 days of age, the primordial germ cells were differentiated into spermatogonia progenitor cells, Leydig and Sertoli progenitor cells (Figure 4).



**Figure 1.** Identifying the pheasant PGCs in the testes tissue at the 8-day-old embryo. The PGCs (red arrows) were identified by A) H&E, B) SSEA-1 antibody, C) PAS stain, D) Toluidine blue stain and E) Alkaline phosphatase enzyme stain. F) Ventral view of pheasant embryo testes. Testes (dashed lines) are located in the ventral surface of mesonephros kidneys (Ms). Note that they are inclined toward the median plane of the body and are located close to each other. R: right, L: left.

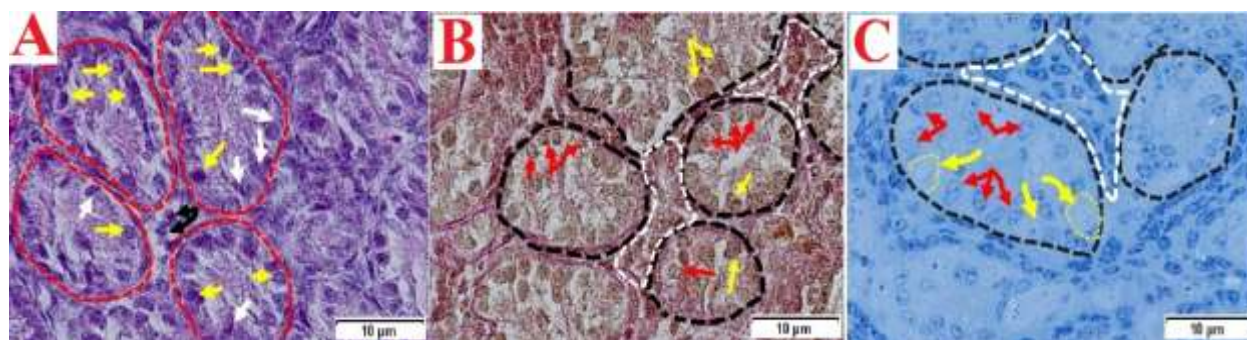


**Figure 2.** Identifying the pheasant PGCs in the testes tissue at the 13-day-old embryo. The PGCs (red arrows) were identified by A) H&E, B) SSEA-1 antibody, C) PAS stain, D) Toluidine blue stain and E) Alkaline phosphatase enzyme stain (PGCs did not differentiate from other cells in this color).

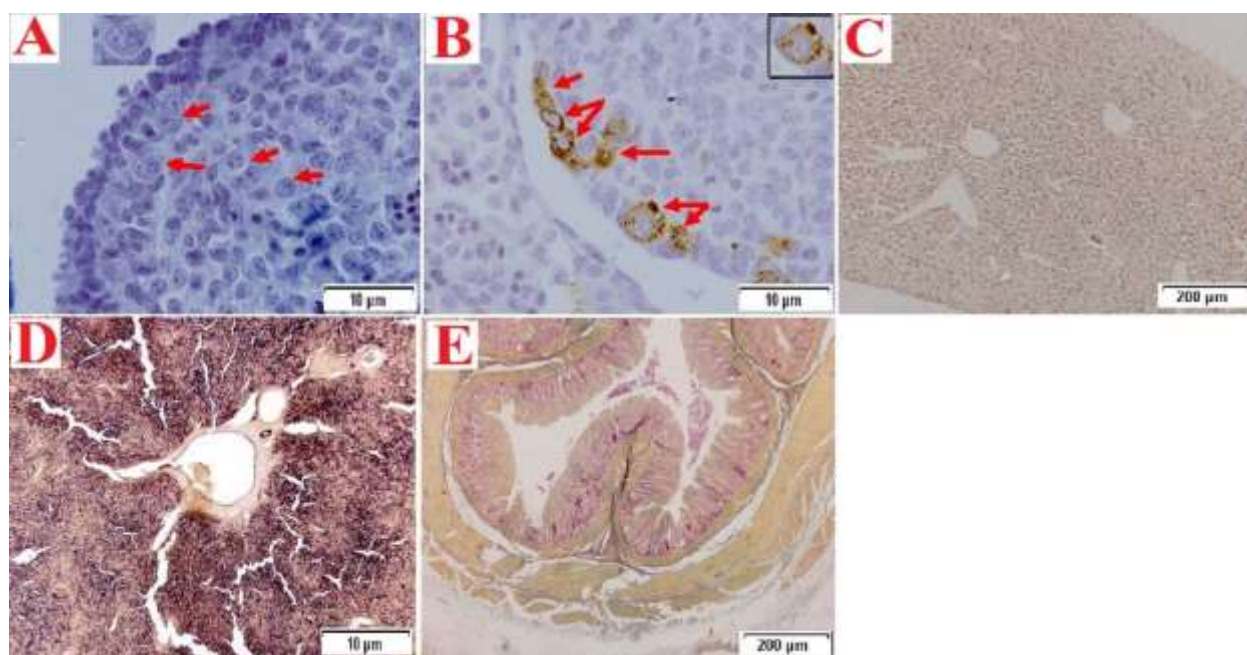


**Figure 3.** Pheasant embryo testes at 17 days. A) H&E stain, B) SSEA-1 antibody stain, C) PAS stain, D) Toluidine blue stain and E) Alkaline phosphatase enzyme stain. Primordial germ cells were not observed in any of the slides.





**Figure 4.** Pheasant embryo testes at 24 days. **A)** H&E stain. Lumen of primary seminiferous tubules marked by broken lines. Spermatogonia progenitor cells marked by yellow arrows. Sertoli progenitor cells marked by white arrows. Leydig progenitor cells marked by black arrows. **B)** PAS stain. Lumen of primary seminiferous tubules marked by broken lines. Spermatogonia progenitor cells marked by red arrows. Sertoli progenitor cells marked by yellow arrows. Leydig progenitor cells marked by marked by white broken lines. **C)** Toluidine blue stain. Lumen of primary seminiferous tubules marked by broken lines. Spermatogonia progenitor cells marked by red arrows. Sertoli progenitor cells marked by yellow arrows. Leydig progenitor cells marked by white broken lines. Primordial germ cells were not observed in any of the slides.



**Figure 5.** **A)** SSEA-1 negative control of chick embryo. PGCs (red arrows). **B)** SSEA-1 positive control of chick embryo. The samples of gonad from chick embryo at stage 28 Hamburger and Hamilton (H&H) were used as a positive control for SSEA-1 antibody, germ cells in this stage reacted positively with SSEA1 at the end of staining. PGCs (red arrows). **C)** Chick liver in one-day age were used as a negative control for the ALP enzyme. **D)** Chick liver in one-day age were used as a positive control for the ALP enzyme. **E)** Rabbit rectum were used as a positive control for PAS stain.

## Discussion

We could not use H&H phases owing to variation in embryonic development between Pheasant and fowl (Hamburger and Hamilton, 1992). The results obtained in the first research phase revealed that the emergence of germ cells in the testes of 8-day-old pheasant embryos could be easily

observed by staining with H&E and toluidine blue.

Studying PGCs needs special stains or antibodies to detect these cells, and PAS is a histochemical marker to differentiate PGCs from adjacent somatic cells (Chojnacka-Puchta, et al, 2012;

Macdonald, Glover, Taylor, Sang, and McGrew, 2010). Fujimoto et al. (1976) claimed that PGCs contained abundant glycogen by PAS reaction (Fujimoto et al, 1976). England and Matsumura (1993) confirmed that PGCs in chick are detected in the germinal crescent using PAS stain (England and Matsumura, 1993). Furthermore, we made the decision to use PAS staining to recognize the pheasant PGCs and then confirm it with specific antibody. Our study proved that PAS staining is a suitable technique to detect PGCs in pheasant embryos in paraffin sections of the testes only up to 8 days of age. We further supposed PAS-positive content of PGCs to have a dramatic downward trend from day 8 to day 13 so that on days 13, 17, and 24 of the embryos, no positive dye reaction was observed in the germ cells.

Hassanzadeh et al. (2019) claimed that PAS stain is an appropriate technique to recognize PGCs in paraffin sections in the gonad of ostrich embryo. The results of our study are not consistent with this study. Jung et al. (2005) identified the chick germ cells using PAS and anti-SSEA-1 staining. According to the observations of Fujimoto et al. (1976) PGCs are PAS positive, and somatic cells are negative because germ cells have high glycogen which contradicts this study's results because of the low glycogen content in the cytoplasm of germ cells in the pheasant testes. These PAS-colored cells were very weak or negative. This study is contradictory to the study in 2013 (Naeemipour and Bassami, 2013). Since PGCs are migratory cells, the migration of cells may lead to a change in the cellular components, including carbohydrates, and this may be one of the reasons why the cells do not show a positive reaction with PAS (Yoshinaga et al, 1992).

SSEA-1 is a cell surface antigen utilized as a marker for stem cell differentiation (Jung et al. 2005). Park and Han identified PGCs in chicken embryos using SSEA-1 and EMA-1 (Park and Han, 2000).

There are many controversies surrounding SSEA1 marker, some reports consider SSEA1 as a PGCs marker; however, the others consider it as a pluripotency marker (Ghasemi et al, 2015). Fox et al. (1981) reported that PGCs in mouse embryos are easily detected by monoclonal antibodies, including SSEA-1. However, SSEA-1 pheasant embryo was negative in PGCs at all ages.

The pheasant PGCs were SSEA-1 negative for all stages. The present results disagree with Yu et al. (2019) who claimed that for SSEA-1, the purified PGCs of Chinese Meiling chicken was positive.

SSEA-1 was not observed in neither of the cleavage stages of bovine embryo nor in tissue sections of the genital ridge (Chojnacka-Puchta et al. 2012). In Turkey embryo, primordial germ cells migrating towards the genital ridge did not express SSEA-1 epitope (D'Costa and Petite, 2004). Results of this study are in line with those mentioned above; PGCs in pheasants are unable to express SSEA-1 epitopes and by helping this method, PGCs were not identified. It indicated the possibility that the epitope was lost or masked in some way. It may suggest that pheasant PGC has different characteristics than other birds PGC (Wade et al, 2014).

Nonoyama et al. (2021) claimed that embryonic stem cells, pluripotent and undifferentiated stem cells in the human umbilical cord, have a positive reaction to the ALP enzyme and the expression of this enzyme in these cells indicates the existence of differentiation in the cells.

This results also showed that the primordial germ cells in the testes of pheasant embryos were ALP negative, which is consistent with the results of research in turkey embryos (Hosseini et al, 2020) and studies in chickens (Jung et al. 2005). However, the results contradict with Swarts (1982) and Naeimipour and Basami's (2013) study on chickens which may be because of the changes in the

metabolic activity of PGCs or changes in ALP enzyme synthesis.

In conclusion, the results showed that PGCs negatively reacted in all stages of study using the alkaline phosphatase and SSEA1 which is probably due to the

differences in the amount of glycogen granule stores in the cytoplasm of primary germ cells or lack of carbohydrates at the cell surface. PGC pheasants' failure to detect SSEA-1 expression may be due to the lack of SSEA-1 expression in pheasants.

### Acknowledgments

The authors thank the Research Council of the Ferdowsi University of Mashhad for financial support.

### Funding

This study was supported by the Research Council of the Ferdowsi University of Mashhad (grant number 3.53979).

### Conflict of interest

The authors declare that they have no conflict of interest.

### References

- Adamski, M., & Kuźniacka, J. (2006). The effect of age and sex on slaughter traits of pheasants (*Phasianus colchicus* L.). *Animal Science Papers and Reports*, 24(Supplement 2), 11-18 .
- Bendel-Stenzel, M., Anderson, R., Heasman, J., & Wylie, C. (1998). *The origin and migration of primordial germ cells in the mouse*. Paper presented at the Seminars in cell & developmental biology.
- Carlson, N. (1985). Origin of the somatic components of chick embryonic gonads. *Archives d'anatomie microscopique et de morphologie experimentale*, 74, 52-59 .
- Chojnacka-Puchta, L., Kasperczyk, K., Plucienniczak, G., Sawicka, D., & Bednarczyk, M. (2012). Primordial germ cells (PGCs) as a tool for creating transgenic chickens. *Polish Journal of Veterinary Sciences*, 15 .(1)
- Clinton, M & ,Haines, L. C. (2001). An overview of factors influencing sex determination and gonadal development in birds. *Genes and Mechanisms in Vertebrate Sex Determination*, 97-115 .
- D'Costa, S., & Petitte, J. N. (2004). Characterization of stage-specific embryonic antigen-1 (SSEA-1) expression during early development of the turkey embryo. *International Journal of Developmental Biology*, 43(4), 349-356 .
- England, M. A., & Matsumura, G. (1993). Primordial germ cells in the primitive streak stages chick embryo as studied by scanning electron microscopy. *Journal of anatomy*, 183(Pt 1), 67 .
- Fox, N., Damjanov, I., Martinez-Hernandez, A., Knowles, B. B., & Solter, D. (1981). Immunohistochemical localization of the early embryonic antigen (SSEA-1) in postimplantation mouse embryos and fetal and adult tissues. *Developmental biology*, 83(2), 391-398 .
- Fujimoto, T., Ninomiya, T., & Ukeshima, A. (1976). Observations of the primordial germ cells in blood samples from the chick embryo. *Developmental biology*, 49(1), 278-282 .
- Fujimoto, T., Ukeshima, A., & Kiyofuji, R. (1976). The origin, migration and morphology of the primordial germ cells in the chick embryo. *The Anatomical Record*, 185(2), 139-153 .
- GHAsemi, H. H., Sobhani, A., & NAZM, B. M. (2015). Multipotent SSEA1 positive cells population differentiation into primordial germ cells and subsequently progress into oocyte-like cells .
- Ginsburg, M., & Eyal-Giladi, H. (1986). Temporal and spatial aspects of the gradual migration of primordial germ cells from the epiblast into the germinal crescent in the avian embryo .
- Gomperts, M., Garcia-Castro, M., Wylie, C., & Heasman, J. (1994). Interactions between primordial germ cells play a role in their migration in mouse embryos. *Development*, 120(1), 135-141. doi:10.1242/dev.120.1.135
- Hamburger, V., & Hamilton, H. L. (1992). A series of normal stages in the development of the chick embryo. *Developmental dynamics*, 195(4), 231-272 .

- Hassanzadeh, B., Nabipour, A., & Dehghani, H. (2019). Ostrich (*Struthio camelus*) primordial germ cells in embryonic blood and presumptive gonad: characterization by PAS and immunohistochemistry. *Iranian Journal of Veterinary Research*, 20(4), 299 .
- Hosseini, A., Nabipour, A., & Dehghani, H. (2020). Characterizing Primordial Germ Cells in the Turkey (*Meleagris Gallopavo*) Embryo. *Anatomical Sciences Journal*, 17(2), 63-72 .
- Jung, J. G., Kim, D. K., Park, T. S., Lee, S. D., Lim, J. M., & Han, J. Y. (2005). Development of novel markers for the characterization of chicken primordial germ cells. *Stem Cells*, 23(5), 6-11 .
- Kim, Y. M., & Han, J. Y. (2018). The early development of germ cells in chicken. *International Journal of Developmental Biology*, 62(1-2-3), 145-152 .
- Kuo, J. (2008). *Electron microscopy: methods and protocols* (Vol. 369): Springer Science & Business Media.
- Macdonald, J., Glover, J. D., Taylor, L., Sang, H. M., & McGrew, M. J. (2010). Characterisation and germline transmission of cultured avian primordial germ cells. *PLoS One*, 5(11), e15518. doi:10.1371/journal.pone.0015518
- Naeemipour, M., & Bassami, M. (2013). Isolation, culture and characterization of chicken primordial germ cells. *Journal of Cell and Molecular Research*, 5(2), 48-53 .
- Nakamura, Y., Kagami, H., & Tagami, T. (2013). Development, differentiation and manipulation of chicken germ cells. *Development, growth & differentiation*, 55(1), 20-40 .
- Nakamura, Y., Yamamoto, Y., Usui, F., Mushika, T., Ono, T., Setioko, A., . . . Tagami, T. (2007). Migration and proliferation of primordial germ cells in the early chicken embryo. *Poultry science*, 86(1), 1-11 .
- Nonoyama, S., Karakida, T., Chiba-Ohkuma, R., Yamamoto, R., Ujiie, Y., Nagano, T., . . . Gomi, K. (2021). Development and Characterization of Alkaline Phosphatase-Positive Human Umbilical Cord Perivascular Cells. *Cells*, 10(11), 3011 .
- Park, T. S., & Han, J. Y. (2000). Derivation and characterization of pluripotent embryonic germ cells in chicken. *Molecular Reproduction and Development: Incorporating Gamete Research*, 56(4), 475-482 .
- Smith, C. A., & Sinclair, A. H. (2004). Sex determination: insights from the chicken. *Bioessays*, 26(2), 120-132 .
- Štefková, K., Procházková, J., & Pacherník, J. (2015). Alkaline phosphatase in stem cells. *Stem cells international*, 2015 .
- Stern, C. D. (2005). The chick: a great model system becomes even greater. *Developmental cell*, 8(1), 9-17 .
- Suvarna, K. S., Layton, C., & Bancroft, J. D. (2018). *Bancroft's theory and practice of histological techniques E-Book*: Elsevier health sciences.
- Swartz, W. J. (1982). Acid and alkaline phosphatase activity in migrating primordial germ cells of the early chick embryo. *The Anatomical Record*, 202(3), 379-385 .
- Tagami, T., Matsubara, Y., Hanada, H., & Naito, M. (1997). Differentiation of female chicken primordial germ cells into spermatozoa in male gonads. *Development, growth & differentiation*, 39(3), 267-271 .
- Wade, A. J., French, N. A., & Ireland, G. W. (2014). The potential for archiving and reconstituting valuable strains of turkey (*Meleagris gallopavo*) using primordial germ cells. *Poultry science*, 93(4), 799-809 .
- Wylie, C. (1999). Germ cells. *Cell*, 96(2), 165-174 .
- Yön Ertuğ, N. D., & Akbulut, C. (2015). Identification of Primordial Germ Cells: Cytological, Histological and Immunohistochemical Aspects .
- Yoshinaga, K., Fujimoto, T., Nakamura, M., & Terakura, H. (1992). (Selective lectin-binding sites of primordial germ cells in chick and quail embryos. *The Anatomical Record*, 233(4), 625-632 .
- Yu, F., Zhu, Z., Chen, X., Huang, J., Jia, R., & Pan, J. (2019). Isolation, characterization and germline chimera preparation of primordial germ cells from the Chinese Meiling chicken. *Poultry science*, 98(2), 566-572.

Received: 05.09.2022

Accepted: 22.11.2022

## The effects of Chaste-berry fruits on hypothalamic-pituitary-ovarian markers gene expression and immune response of laying hens: Phytoestrogens in Chaste-berry are ER $\beta$ -selective

Mahmood Nazari<sup>1\*</sup>, Mohamad Reza Ghorbani<sup>2</sup>, Mohamad Taghi Beighi Nassiri<sup>3</sup>, Neda Fathimoghdam<sup>4</sup>, Razieh Sabahi<sup>5</sup> and Saiedeh Taghva Mosavi<sup>5</sup>

<sup>1</sup> Associate Professor, Department of Animal Science, Faculty of Animal Science and Food Technology, Agricultural Sciences and Natural Resources University of Khuzestan, Mollasani, Iran

<sup>2</sup> Associate Professor, Department of Animal Science, Shirvan Faculty of Agriculture, University of Bojnord, Bojnord, Iran

<sup>3</sup> Professor, Department of Animal Science, Faculty of Animal Science and Food Technology, Agricultural Sciences and Natural Resources University of Khuzestan, Mollasani, Iran

<sup>4</sup> MSc graduate of animal nutrition, Department of Animal Science, Faculty of Animal Science and Food Technology, Agricultural Sciences and Natural Resources University of Khuzestan, Mollasani, Iran

<sup>5</sup> MSc graduate of animal genetic and breeding, Department of Animal Science, Faculty of Animal Science and Food Technology, Agricultural Sciences and Natural Resources University of Khuzestan, Mollasani, Iran

Received: 02.08.2022

Accepted: 30.01.2023

### Abstract

Estrogen consumption in women can increase the risk of breast cancer. Estrogen stimulates the growth of cancer cells through the estrogen receptor alpha (ER $\alpha$ ). One of the strategies that has recently been considered is the use of phytoestrogens. Previous studies have shown that Chaste-berry contains high levels of phytoestrogens. Scientists disagree on whether the phytoestrogens in Chaste-berry are used to treat many diseases in women, which are ER $\alpha$  or ER $\beta$  selective. In the present study, laying hens were used as a model to find the answer because only alpha estrogen receptor is expressed in the oviduct. In this study, the effect of Chaste-berry fruit powder on performance, egg quality, immune response, and the expression of GnRH, LH, ovalbumin (OVAL), and ovomucoid (OVM) genes in laying hens were evaluated. A total of 90 leghorns (Hy-Line, W-36) laying hens (at 72 to 80 weeks old) were used in a completely randomized design with three treatments and five replicates (n=6). The treatments were various levels of Chaste-berry fruit powder including zero, 1, and 2% levels of Chaste-berry fruit powder per kg of diet. Our results showed that performance parameters, egg quality factors, and immune responses were not significantly affected by various levels of Chaste-berry fruit powder. Moreover, the results indicated that the various levels of Chaste-berry did not have a significant effect on LH, OVAL, and OVM gene expression. However, GnRH gene expression was significantly increased in treatment 3 (a diet containing 2% Chaste-berry) compared to the control and 1% Chaste-berry groups. Moreover, the addition of 1% Chaste-berry fruit powder to the diet had no significant effect on GnRH gene expression. Therefore, Chaste-berry supplementation is not recommended in laying hens. Furthermore, our data reinforce this theory that phytoestrogens in Chaste-berry fruits are ER $\beta$ -selective.

**Key words:** Chaste-berry, Estrogen receptor, Phytoestrogen, Cancer

---

\* **Corresponding Author:** Mahmood Nazari, Associate Professor, Department of Animal Science, Faculty of Animal Science and Food Technology, Agricultural Sciences and Natural Resources University of Khuzestan, Mollasani, Iran  
E-mail: [M.nazari@Asnrkh.ac.ir](mailto:M.nazari@Asnrkh.ac.ir)



© 2020 by the authors. Licensee SCU, Ahvaz, Iran. This article is an open access article distributed under the terms and conditions of the Creative Commons Attribution-NonCommercial 4.0 International (CC BY-NC 4.0 license) (<http://creativecommons.org/licenses/by-nc/4.0/>).



## Introduction

Some types of breast cancer are affected by hormones such as estrogens. Studies have shown that estrogens are important for stimulating the growth of breast cancers. It has been indicated that estrogens are carcinogenic in breast cancer. Estrogens are considered to play a key role in promoting the proliferation of breast epithelium. Estrogens action is mediated by two receptors: estrogen receptors alpha ( $ER\alpha$ ) and beta ( $ER\beta$ ). Now it is recognized that  $ER$ -alpha plays a role in breast cancer cell proliferation. Estrogen by binding to the estrogen alpha receptor increases the proliferation of cancer cells in breast cells (Ali and Coombes, 2000). One solution that has recently been considered is the use of phytoestrogens that bind to the estrogen receptor beta. Phytoestrogens are considered less dangerous than chemical estrogens. Chaste-berry (Vitex) is a multifunctional herb belonging to the Verbenaceae family with phytoestrogenic properties. Also, Vitex is known for its antifungal, anti-androgenic, antibacterial, anticancer, antiseptic, and various biological activities such as antimicrobial and antioxidant properties (Zamani et al, 2012). Vitex is a native plant of the middle Asian, southern European, and Mediterranean countries (Mari et al, 2015). This plant has numerous uses in traditional medicine and is traditionally used to treat many diseases in women, including infertility, premenstrual syndrome, hyperprolactinemia, abnormal menstrual cycles, endometriosis, relief of menopausal symptoms, and insufficient breast milk (Katiraei et al, 2015; Rani and Sharma, 2013). Previous studies showed that Vitex fruits increase the estrogen level and the progesterone levels in mice (Ahangarpour et al, 2016) and decrease LH without affecting FSH in rats (Ibrahim et al, 2008).

Some researchers have claimed that the phytoestrogens in Vitex fruits bind only to the estrogen receptor beta (Wuttke et al, 2003; Jarry et al, 2003), while others have

shown that Vitex fruits contain phytoestrogens that can also bind to the estrogen receptors alpha and beta (Liu et al, 2001; Liu et al, 2004). The researchers indicated that the reason for this discrepancy was probably due to the origin and extraction of the drug and the treatment of the extractions. The mentioned experiments were all performed in Vitro conditions and were not confirmed in Vivo conditions. Examining the effect of Vitex on organs that produce only one of these receptors ( $ER\alpha$  or  $ER\beta$ ) can help to understand which type of estrogen receptor bind to phytoestrogens in Vitex.

The chicken was used as an experimental animal model for human genetics and disease because of its advantages since early in the last century (Dodgson and Romanov, 2004). Several human diseases such as cancer, Atherosclerosis, and nonalcoholic fatty liver disease (NAFLD) were investigated by using poultry (Anderson et al, 2014; Anderson et al, 2013; Davis et al, 2016; Johnson and Giles, 2006). It has been well documented that in all parts of the laying hen oviduct only the estrogen receptor alpha ( $ER\alpha$ ) is produced (Stadnicka et al, 2018). Therefore, laying hens can be a good model for this experiment. In the same line, the purpose of this study was to evaluate the effect of Vitex fruits on performance, egg quality, immune response, and genes expression of hypothalamic GnRH, luteinizing hormone (LH) from the anterior pituitary, and oviduct markers (ovalbumin (OVAL) and ovomucoid (OVM)) of laying hens to determine if phytoestrogens in Vitex can affect oviduct estrogen receptor alpha.

## Materials and methods

### Plant material

Vitex fruits were prepared by a local producer. The parts of the plant suitable for consumption were dried in dark and powdered by an electric mill. The chemical composition of Vitex powder was

determined by the Association of Official Analytical Chemists methods (AOAC, 2000). The results showed that Crude protein (CP), ether extract (EE), crude fiber (CF), and crude ash were 10.5%, 5.6%, 56.0% and 12.6% of dry matter, respectively.

#### Birds and sample collection

All procedures involving experimental animals and poultry welfare were performed in accordance with FASS guidelines (FASS, 2020). In short, a total of 90 Leghorn (Hy-Line, W-36) laying hens in the second cycle of production were used in a completely randomized design with sampling (equal number of samples per experimental unit) with three treatments and five replicates ( $n = 6$ ) for eight weeks according to the following model equations:

$$Y_{ijk} = \mu + T_i + e_{ijk} + \delta_{ijk}$$

In the above equations,  $Y_{ijk}$  is the dependent variable,  $\mu$ ; population mean,  $T_i$ ; the effect of the  $i^{\text{th}}$  treatment,  $e_{ijk}$ ; the random error, and  $\delta_{ijk}$  is the sampling error effect.

Treatments were various levels of Vitex including zero (control; T1), 1.00% (T2), 2.00% (T3). The laying hens received a corn-soybean meal-based diet supplemented diet (corn and soybean-based diet with 15.05 % crude protein and 2802 kcal/ kg metabolizable energy) in a mash form and formalized according to the Hy-Line W-36 (2016) nutrient requirements (Table 1). Diet and water were prepared ad-libitum during the experiment. The birds were exposed to 16-hour light and 8-hour darkness (in 24 hours) throughout the experimental periods.

Egg weight (EW, gr), egg production (EP, %) and egg mass (EM, gr/hen/day) were registered daily. Feed intake (FI, gr) was measured weekly and feed conversion ratio (FCR, grams of feed: grams of egg

mass) was calculated weekly. Two eggs were randomly collected from each replicate and egg quality (Haugh unit, shell strength, shell percentage and shell thickness) was determined weekly.

At the end of the experiment, one bird was sacrificed by cervical dislocation from each replicate, and their magnum, hypothalamus, and hypophysis were immediately separated. The tissues were washed with phosphate buffered saline (PBS) and transferred to the genetic laboratory with liquid nitrogen and stored at  $-70^{\circ}\text{C}$  until total RNA extraction.

#### Real-time quantitative PCR

Total RNA was extracted from magnum tissue using Invitrogen TRIzol<sup>®</sup> Reagent. The quality and integrity of the extracted RNA were assessed using 1% denaturing gel electrophoresis and a NanoDrop TM 2000C spectrophotometer (A260/A280). In the following, cDNA was synthesized using the Sinnaclon First Strand cDNA Synthesis Kit (Sinnaclon, Cat. No: RT5201). Eventually, the expression of OVAL, OVM, and Beta-actin genes was quantified by real-time quantitative PCR (RT-qPCR) technique. The primer information for these genes is listed in Table 2 .

In this study, cDNA was amplified by the polymerase chain reaction (PCR) technique. DNA products were quantitated using a Step One Plus real-time PCR (Applied Biosystems). The real-time qPCR cycling programs were as follows: A denaturation step (5 min at  $95^{\circ}\text{C}$ ) was followed by an amplification step with 40 cycles of 15s at  $95^{\circ}\text{C}$ , 45s at  $60^{\circ}\text{C}$ , and 30 s at  $72^{\circ}\text{C}$ . A melting curve was plotted to investigate the formation of a non-specific product. The melting curves were produced by gradually increasing the reaction temperature from  $55$  to  $95^{\circ}\text{C}$  (at a  $0.1^{\circ}\text{C/s}$  incremental increase).

**Table 1. Composition and calculated analyses of the basal diet T1, T2 and T3**

Ingredients (%)	T1 (control)	T2 (1.00% Vitex)	T3 (2.00% Vitex)
Corn	60.19	59.00	57.60
Soybean meal	22.30	22.30	22.40
Vitex powder	0	1	2
Vegetable oil	3.05	3.34	3.74
Di-calcium phosphate	1.6	1.6	1.6
Oyster shell	6.5	6.5	6.5
Limestone	5.15	5.15	5.15
Sodium bicarbonate	0.23	0.23	0.23
Salt	0.23	0.23	0.23
L-lysine hydrochloride	0.01	0.01	0.01
DL-Methionine	0.14	0.14	0.14
Vitamin premix1	0.25	0.25	0.25
Mineral premix2	0.25	0.25	0.25
<i>Calculated analysis</i>			
Metabolizable energy (kcal kg <sup>-1</sup> )	2802	2798	2798
Crude protein (%)	15.05	15.03	15.01
Calcium (%)	4.85	4.84	4.84
Available phosphorus (%)	0.41	0.41	0.41
L- Lysine (%)	0.77	0.77	0.77
Methionine + Cystine (%)	0.64	0.64	0.64

<sup>1</sup>Vitamin premix provided the following per kilogram of diet: vitamin A: 8,000 IU; vitamin D3: 33000 IU; vitamin E: 20.00 mg; vitamin K3: 2.20 mg; vitamin B1: 1.50 mg; vitamin B2: 4.00 mg; vitamin B3: 8.00 mg; vitamin B5: 35.00 mg; vitamin B6: 2.50 mg; vitamin B9: 0.50 mg; vitamin B12: 10 µg; choline chloride: 468.70 mg.

<sup>2</sup> Mineral premix provided the following per kilogram of diet: Mn: 80.00 mg; Fe: 75.00 mg; Zn: 64.00; Cu:6.00 mg; I: 0.87 mg; Se: 0.30 mg.

In this method, the Beta-actin gene, as a reference gene, was used to normalize the data. The  $2^{-\Delta\Delta CT}$  method was applied for quantitative real-time PCR data analysis (Pfaffl et al., 2002). This method is a convenient way to analyze the relative changes in gene expression from real-time quantitative PCR experiments. The efficiency corrected calculation models is:

$$ratio = \frac{(E_{target})^{\Delta CT_{target (control-sample)}}}{(E_{ref})^{\Delta CT_{ref (control-sample)}}}$$

In this model,  $E_{target}$  and  $E_{ref}$  are efficiency of target and reference gene respectively. PCR efficiency per amplicon was calculated using the LinRegPCR program. The program calculates PCR efficiency for each amplicon by linear regression on the Log (fluorescence) per cycle number data for each sample (Ramakers et al, 2003).

### Antibody response to challenge with sheep red blood cells (SRBC)

To determine immune response, at 6 and 8 weeks of experiment, 0.5 mL of 20% sheep red blood cells (SRBC) was injected to the breast muscle of 2 hens per replicate. Then blood samples were taken from brachial vein 7 days after each injection. Blood samples were collected in EDTA vials stored at -20 °C. Antibody titer against SRBC was determined by the hemagglutination assay described by Nelson (1995).

### Statistical analysis

The data were statistically analyzed by one-way analysis of variance (ANOVA), General Linear Model procedure, using SAS 9.1 software (SAS, 2005). Significant differences between treatments were detected using Duncan's multiple range test at the  $P < 0.05$  level of significance.

**Table 2. The sequence and characteristics of primers used for RT-PCR and real time quantitative PCR**

Gene	Forward (F) and reverse (R) primers (5'→ 3')	Annealing temperature (°C)	Amplicon size (bp)	Reference
GnRH	F:5'-ATTTTCCAGCGGGAAGAGTTG-3' R:5'-TGGGTTTGTGATGGTGTGTG-3'	62	350	Sabahi et al. 2020
LH	F:5'-GTTGGTGCTGATGACCCTTT-3' R:5'-TGGTGGTCACAGCCATACAT-3'	62	194	Sabahi et al. 2020
Ovalbumin	F: CGTTCAGCCTTGCCAGTAGA R: AGTATTCTGGCAGGATTGGGT	60	60	Mosavi et al. 2022
Ovomucoid	F: TATGCCAACACGACAAGCGA R: CCCCTGCTCTACTTTGTGG	60	133	Mosavi et al. 2022
Beta-actin	F: TGCTGTGTTCCCATCTATCG R: TTGGGACAATACCGTGTTCAT	60	150	Rabieh et al. 2020

## Results

### Egg production and quality

The effect of dietary Vitex fruits on egg production traits of laying hens is presented in Table 3. Performance parameters such as FI, EP, EM, EW and FCR were not significantly affected by various levels of Vitex fruit powder ( $P>0.05$ ). The effect of dietary Vitex fruits on egg quality parameters of laying hens is illustrated in Table 4. The data indicate that egg quality parameters such as haugh unit, shell strength, shell percentage, shell thickness,

albumen weights percentage, and yolk weights percentage were not affected significantly by Vitex supplementation ( $P>0.05$ ).

### Immune response

Effects of dietary Vitex fruits on immune parameters of laying hens are summarized in Table 5. Primary and Secondary AntiSRBC antibody levels were unaffected by dietary Vitex fruits treatment.

**Table 3. The effect of dietary Vitex fruits on egg production and quality traits of laying hens on the second cycle of production (at 72 to 80 weeks old)**

Treatments	Egg weight (g)	Egg mass (g)	Egg production (%)	Feed intake (g)	FCR (g/g)
T1 (Control)	64.39	53.22	82.55	107.98	2.04
T2 (1.00% Vitex)	64.90	53.67	82.80	107.41	2.01
T3 (2.00% Vitex)	64.84	51.05	79.50	111.62	2.23
Standard errors of means (SEM)	0.22	1.40	1.83	2.28	0.11
<i>p</i> -value	0.96	0.70	0.79	0.48	0.25

No significant differences were observed among treatments ( $p > 0.05$ ).

**Table 4. The effect of dietary Vitex fruits on egg quality traits of laying hens on the second cycle of production (at 72 to 80 weeks old)**

Treatments	Shell Strength (kg/cm <sup>2</sup> )	Shell thickness (mm/100)	Haugh unit	Shell (%)	Yolk weight (%)	Albumen weight (%)
T1 (Control)	1.49	39.66	85.07	10.37	28.45	61.18
T2 (1.00% Vitex)	1.47	39.65	86.35	10.50	27.79	61.71
T3 (2.00% Vitex)	1.3	39.62	86.21	10.44	27.61	61.91
Standard errors of means (SEM)	0.05	0.17	0.69	0.08	0.36	0.30
<i>p</i> -value	0.14	0.96	0.77	0.98	0.60	0.83

No significant differences were observed among treatments ( $p>0.05$ ).

**Table 5. The effect of dietary *Vitex* fruit powder on immunity response of laying hens**

Treatments	Groups			SEM	P-value
	(Control)	(1.00% Vitex)	(2.00% Vitex)		
Primary AntiSRBC antibody level (log2)	4.00	5.33	4.60	0.21	0.34
Secondary AntiSRBC antibody level (log2)	4.50	5.50	5.25	0.19	0.23

No significant differences were observed among treatments ( $p>0.05$ ).

### Total RNA quality assessment

RNA quality includes two factors: RNA purity and RNA integrity. A common technique for assessing the quality of RNA is optical density (OD) measurement. A 260/A280 ratio between 1.8 and 2.1 is usually considered an acceptable indicator of good RNA quality. Isolating total RNA using the TRIzol reagent resulted in a high-quality product. The 260 / 280 absorbance ratios showed that all RNAs were of high quality (between 1.85 and 2.05). The RNA integrity was evaluated by the sharpness of rRNA bands visualized on a denaturing agarose gel. For all of the RNA samples tested, two strong bands (28S and 18S) without degradation were observed (Figure 1).

### Oviduct markers amplification

To determine whether GnRH, LH, OVAL, OVM, and Beta-actin mRNA are expressed in the oviduct of laying hens, total RNA was isolated from magnum cells and analyzed using real-time qPCR. Agarose gel electrophoresis confirmed the expression of Beta-actin mRNA (Figure 2A), OVM (Figure 2B), OVAL (Figure

2C), GnRH (Figure 2D) and LH (Figure 2E) of laying hens. The GnRH, LH, OVAL, OVM, and Beta-actin appeared as a single band on 2% (w/v) agarose gels. Electrophoresis of the PCR products showed the 350, 194, 60, 133, and 150-bp fragments for GnRH, LH, OVAL, OVM, and Beta-actin, respectively.

### Validation of real-time qPCR

Conventional PCR amplification and real-time PCR melting curve for OVAL, OVM, and Beta-actin genes were given. Melting peaks analysis on the PCR products for all primers confirmed minimal primer-dimers and primer specificity as shown by single peak melting curves for individual genes (results not presented). To determine the linearity of the reaction and the PCR efficiency of amplicons, the LinRegPCR program is used to calculate linear regression on the Log (fluorescence) per cycle number data for each sample (Ramakers et al., 2003). The mean PCR efficiency and coefficient of determination ( $R^2$ ) calculated 99%, 0.9938 for Beta-actin, 102%, 0.9998 for OVAL, and 103%, 0.9990 for OVM.

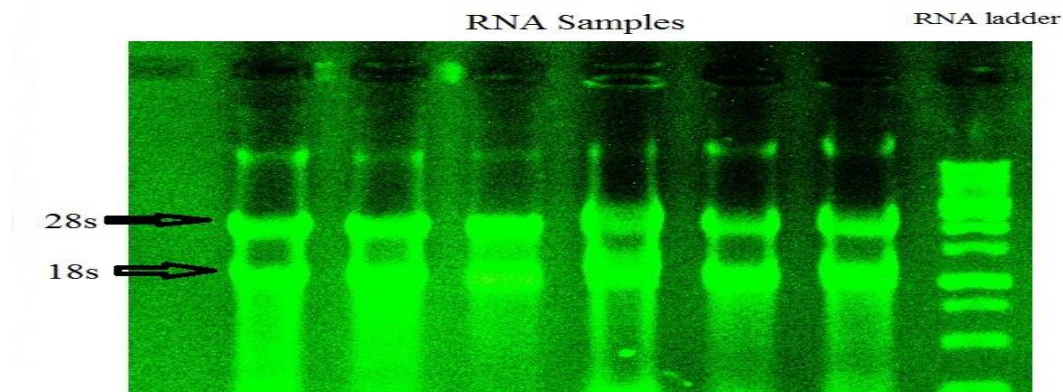


Fig. 1 Agarose gel electrophoresis and RNA integrity analysis of total RNA samples extracted from magnum cell of laying hens isolated by the TRIzol reagent.

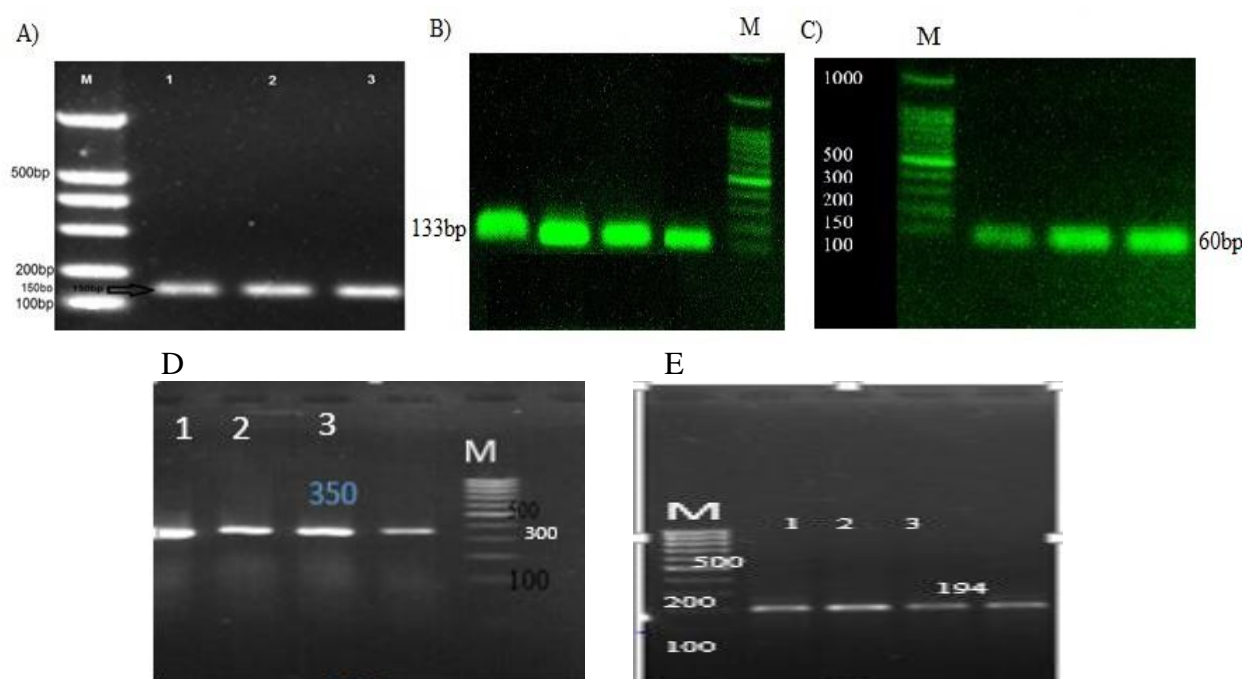


Fig. 2 A sample of electrophoresis of PCR products for (A) Beta actin (B) Ovomuroid (C) Ovalbumin (D) GnRH (E) LH of laying hens on the 2% Agarose gel. M: size marker 100bp

### Gene expression analysis

Results of real-time quantitative PCR for GnRH, LH, OVAL and OVM mRNA expression are summarized in Table 6. The amount of mRNAs was normalized to the amount of Beta-actin mRNA. There were no significant changes in OVAL and OVM mRNA concentrations compared to the control. The results showed that the various levels of Vitex did not have a significant effect on OVAL and OVM genes

expression ( $P>0.05$ ). The ANOVA results revealed that GnRH gene expression was significantly increased in treatment 3 (diet containing 2% Vitex) compared to the control and 1% Vitex groups ( $P<0.01$ ). While, addition of 1% Vitex fruit powder to diet had no significant effect on GnRH gene expression ( $P>0.05$ ). Furthermore, addition of 1 or 2% Vitex fruit powder had no significant effect on LH gene expression ( $P>0.05$ ).

**Table 6. The effects of dietary *Vitex* fruit powder on genes expression of laying hens**

Target genes	Groups			SEM	P-value
	(Control)	(1.00% Vitex)	(2.00% Vitex)		
GnRH	1.000 <sup>b</sup>	1.396 <sup>b</sup>	5.206 <sup>a</sup>	0.85	0.017
LH	1.000	1.1000	1.273	0.15	0.162
Ovalbumin	1.000	1.401	1.465	0.090	0.497
Ovomucoid	1.000	1.360	1.580	0.239	0.587

The amount of mRNAs was normalized to the amount Beta actin mRNA. Different letters superscripts (a, b) among treatments differ significantly ( $p \leq 0.05$ ), according to analysis of variance (ANOVA) using a general linear model (GLM).

## Discussion

Vitex is traditionally used to treat many diseases in women (Katirae et al, 2015; Rani and Sharma, 2013). Previous studies reported that the fruits of Vitex contain high amounts of phytoestrogens. As a result, consumption of Vitex fruits increased estrogen and progesterone levels (Ahangarpour et al, 2016). Due to their structural similarity with estradiol, phytoestrogens play an estrogenic and/or anti-estrogenic role. The structural similarities between phytoestrogens and estrogens cause them to act as an antagonist of estrogen (Yildiz, 2005).

Estrogens are produced by the theca cells of the ovarian follicles in birds. Estrogens regulate reproductive functions, reproductive behavior, synthesis of egg yolk proteins, and egg white proteins in birds (Hrabia et al, 2008). Estrogens are responsible for the growth of the follicle and yolk (Dougherty and Sanders, 2005). Moreover, estrogen stabilizes the mRNA of the ovalbumin gene in laying hens (Arao et al, 1994). Studies indicated that estrogen plays a role in the transcriptional and post-transcriptional regulations of ovalbumin (Palmiter, 1972; McKnight and Palmiter, 1979; Schweizer et al, 1985; Kato et al, 1992). Tubular glands induced by estrogen synthesize large numbers of egg-white proteins, such as ovalbumin, ovomucoid,

lysozyme, and conalbumin (Ohler et al, 1968). Two oviduct markers OVAL and OVM, which are known as molecular signatures of oviduct cells, are expressed only in the oviducts of laying hens (Stadnicka et al, 2018). Moreover, research has shown that estrogen plays an important role in regulating Gonadotropin-releasing hormone (GnRH). GnRH is a key regulatory molecule of the hypothalamus–pituitary gonadal axis which induces transcription of luteinizing hormone (LH) and follicle stimulating hormone (FSH) from the anterior pituitary (Lv et al. 2018).

Egg quality and egg production rapidly decrease at the end of the laying cycle. Because the levels of ovarian steroid hormones decrease in aged birds, egg quality and egg production rapidly decrease at the end of the laying cycle (Liu et al, 2018). It was hypothesized that supplementation of Vitex fruits containing phytoestrogens could increase estrogen at the end of the laying hen production period, thus overcoming the decline in production. In this study, Vitex fruits powder was added to the laying hen diet at three levels of 0, 1, and 2% in the late phase of the second production cycle.

RT-qPCR results indicated that the various Vitex levels did not significantly affect the expression of LH, OVAL, and OVM genes. Egg quality and egg production confirmed the RT-qPCR results. The results revealed that egg production and egg quality (egg weight, egg mass, albumen, and yolk weights percentage) were not significantly affected by various levels of Vitex powder. Consistent with the results, Karacollokcu et al. (2016) reported



that supplementing *Myrtus* and *Vitex* volatile oil (alone or combined) in the laying hen diet did not affect the performance and internal and external quality traits of the eggs during the peak of the egg production period.

It should be noted that *Vitex* fruit powder supplementation up to 2% significantly increased the expression of hypothalamic GnRH gene compared to the control group and 1% *Vitex* ( $P < 0.01$ ). While the addition of 1% *Vitex* fruit powder to the diet has no significant effect on GnRH gene expression ( $P > 0.05$ ). It seems that adding *Vitex* to the poultry diet cannot be effective. Perhaps the reason must be sought in how the active phytoestrogens in the *Vitex* and estrogen receptors ( $ER\alpha$  and  $ER\beta$ ) interact. *Vitex* consists of compounds such as vitexin, apigenin, and pendolitin, which are the most active phytoestrogen in *Vitex* fruits and mostly affect estrogen receptor beta ( $ER\beta$ ) (Wuttke et al, 2003; Jarry et al, 2003). It also contains small amounts of linoleic acid ( $0.0056 \mu\mu\text{g}$  in 90 g of a defatted methanol extract), which can bind to alpha and beta estrogen receptors and stimulate  $ER\beta$  mRNA expression (Liu et al, 2004). Of course, these results are all obtained in vitro conditions. The results of our experiments revealed that this small amount of linoleic

acid (compared to other phytoestrogens in *Vitex* fruits) could not be effective. The *Vitex* supplementation in laying hens diet could increase GnRH gene expression in the hypothalamus where both  $ER\alpha$  and  $ER\beta$  are present but in the oviduct which only expresses the  $ER\alpha$  (Stadnicka et al, 2018), phytoestrogens were not effective. The results of this research reinforce this theory that the phytoestrogens in *Vitex* fruits are  $ER\beta$ -selective.

In the current study, considering the phytoestrogenic properties of Chaste-berry (*Vitex*), the effects of Chaste-berry fruits on laying hens were investigated. According to our results, supplementation of Chaste-berry fruits at levels 1 and 2 in the diet of laying hens had no effect on performance, and immune response. Therefore, Chaste-berry supplementation is not recommended in laying hens. RT-qPCR results indicated that the various *Vitex* levels did not significantly affect the expression of LH, OVAL, and OVM genes. However, *Vitex* fruit powder supplementation up to 2% significantly increased the expression of hypothalamic GnRH gene compared to the control group and 1% *Vitex*. Also, our results confirmed that phytoestrogens in *Vitex* fruits are  $ER\beta$ -selective.

### Acknowledgments

We acknowledge the Research deputy of Agricultural Sciences and the Natural Resources University of Khuzestan for financial support.

### Conflict of interest

The authors confirm that there are no known conflicts of interest associated with this publication and there has been no significant financial support for this work that could have influenced its outcome.

### Funding

This research was financially supported by the Agricultural Sciences and Natural Resources University of Khuzestan, Mollasani, Iran.

## References

- Ahangarpour, A., Najimi, S.A., Farbood, Y. (2016). Effects of *Vitex agnus-castus* fruit on sex hormones and antioxidant indices in a D-galactose-induced aging female mouse model. *J Chinese Med Ass*, 79(11), 589-596.
- Ali, S., Coombes, R.C. (2000). Estrogen receptor alpha in human breast cancer: occurrence and significance. *J Mam Gland Biol Neo*, 5(3), 271-81.
- Anderson, J.L., Ashwell, C.M., Smith, S.C., Shine, R., Smith, E.C., et al. (2013). Atherosclerosis-susceptible and atherosclerosis-resistant pigeon aortic cells express different genes in vivo. *Poultry Science*, 92(10), 2668-2680.
- Anderson, J.L., Keeley, M.C., Smith, S.C., Smith, E.C. (2014). Rosiglitazone modulates pigeon atherosclerotic lipid accumulation and gene expression in vitro. *Poultry Science*, 93(6), 1368-1374.
- AOAC. (2000). Official Methods of Analysis. Vol. I. 18th Edition. Association of Official Analytical Chemists, Arlington, VA, USA.
- Arao, Y., Miyatake, N., Ninomiya, Y., Hasegawa, T., Masushige, S., Kato, S. (1994). Estrogen stabilization of the mRNA of chicken ovalbumin gene in the cultured organ from estrogen induced-chick oviduct. *Bioscience, Biotechnology, and Biochemistry*, 58(2), 261-264.
- Davis, J.E., Cain, J., Small, C., Hales, D.B. (2016). Therapeutic effect of flax-based diets on fatty liver in aged laying hens. *Poultry Science*, 95(11), 2624-2632.
- Dodgson, J.B. Romanov, M.N. (2004). Use of chicken models for the analysis of human disease. *Curr Protoc Hum Genet*. Chapter 15: Unit 15.5.
- Dougherty, D.C. Sanders, M.M. (2005). Estrogen action: revitalization of the chick oviduct model. *Trends in Endocrinology & Metabolism*, 16, 414-419.
- FASS. (2020). Guide for the care and use of agricultural animals in agricultural research and teaching. 4th ed. <http://creativecommons.org/licenses/by-nc-nd/4.0/>.
- Hrabia, A., Wilk, M., Rzas, J. (2008). Expression of alpha and beta estrogen receptors in the chicken ovary. *Folia Biologica (Krakow)*, 56, 187-91.
- Ibrahim, N., Shalaby, A., Farag, R., Elbaroty, G., Nofal, S., Hassan, E. (2008). Gynecological efficacy and chemical investigation of *Vitex* fruits growing in Egypt. *Natural Prod Res*, 22(6), 537-46.
- Jarry, H., Spengler, B., Porzel, A., Schmidt, J., Wuttke, W., Christoffel, V. (2003). Evidence for estrogen receptor beta-selective activity of *Vitex* and isolated flavones. *Planta Med*, 69(10), 945-7.
- Johnson, P.A., Giles, J.R. (2006). Use of genetic strains of chickens in studies of ovarian cancer. *Poultry Science*, 85(2), 246-250.
- Karacolokcu, M.Z., Guclu, B.K., Kara, K., Tugrulay, S. (2016). Effect of some essential oil supplementation to laying hen diet on performance and egg quality. *Acta Vet Eurasia*, 42, 31-37.
- Katirae, F., Mahmoudi, R., Tahapour, K., Hamidian, G., Emami, S.J., (2015). Biological properties of *Vitex agnus-castus* essential oil (phytochemical component, antioxidant and antifungal activity). *Biotech and Health Science*, 2, 267-97.
- Kato, S., Tora, L., Yamauchi, J., Masushige, S., Bellard, M., Chambon, P. A. 1992. A far upstream estrogen response element of the ovalbumin gene contains several half-palindromic 5'-TGACC-3' motifs acting synergistically. *Cell*, 68(4), 731-742.
- Liu, J., Burdette, J.E., Sun, Y., Deng, S., Schlecht, S.M., Zheng, W. et al. (2004). Isolation of linoleic acid as an estrogenic compound from the fruits of *Vitex agnus-castus* L. (chaste-berry). *Phytomedicine*, 11(1), 18-23.
- Liu, J., Burdette, J.E., Xu, H., Gu, C., van Breemen, R.B., Bhat, K.P., Booth, N., Constantinou, A.I., Pezzuto, J.M., Fong, H.H., Farnsworth, N.R., Bolton, J.L. (2001). Evaluation of estrogenic activity of plant extracts for the potential treatment of menopausal symptoms. *Journal of Agricultural Food Chemistry*, 49(5), 2472-9.
- Liu, Z., Sun, C., Yan, Y., Li, G., Shi, F., Wu, G., Liu, A., Yang, N. (2018). Genetic variations for egg quality of chickens at late laying period revealed by genome-wide association study. *Scientific Rep*, 8, 10832.
- Lv, Z., Xing, K., Li, G., Liu, D. and Guo, Y. (2018). Dietary genistein alleviates lipid metabolism disorder and inflammatory response in laying hens with fatty liver syndrome. *Frontiers in physiology*, 9, 1493.
- Mari, A., Montoro, P., D'Urso, G., Macchia, M., Pizza, C., Piacente, S. (2015). Metabolic profiling of *Vitex agnus-castus* leaves, fruits and sprouts: analysis by LC/ESI/(QqQ)MS and (HR) LC/ESI/(Orbitrap)/ MSn. *Journal Pharma and Biomed Anal*, 102, 215-21.

- McKnight, G.S., Palmiter, R.D. (1979). Transcriptional Regulation of the Ovalbumin and Conalbumin Genes by Steroid Hormones in Chick Oviduct. *J Bio Chem*, 254(18), 9050-9058.
- Mosavi, S.T., Beigi Nassiri, M.T., Roshanfekr, H.R., Nazari, M. (2022). The effect of Vitex agnuse castus fruits powder on oviduct markers gene expression of laying hens. *Research On Animal Production*, 13(38), 138-146.
- Nelson, N.A., Lakshmanan, N., Lamont, S.J. (1995). Sheep red blood cell and Brucella abortus antibody responses in chickens selected for multi trait immunocompetence. *Poultry Science*, 74(10), 1603-9.
- Ohler, P.O., Grimley, P.M., O'Malley, B.W. (1968). Protein synthesis: differential stimulation of cell-specific proteins in epithelial cells of chick oviduct. *Science*, 160, 86-87.
- Palmiter, R.D. (1972). Regulation of protein synthesis in chick oviduct. I. Independent regulation of ovalbumin, conalbumin, ovomucoid, and lysozyme induction. *Journal Bio Chem*, 247(20), 6450-6461.
- Pfaffl, M.W., Horgan, G.W. Dempfle, L. (2002). Relative expression software tool (REST) for group-wise comparison and statistical analysis of relative expression results in real- time PCR. *Nucleic Acids Research*, 30(9), 36.
- Rabieh, M., Rooshanfekr, H., Nazari, M., Ghorbani, M.R. (2020). Gene expression of antioxidant enzymes fed wild pistachio (*Pistachio atlantica*), purslane (*portulaca oleracea*) extract and vitamin E under in broiler chickens under heat stress condition. *Iranian Veterinary Journal*, 17(2), 51-60 (In Persian).
- Ramakers, C., Ruijter, J.M., Deprez, R.H., Moorman, A.F. (2003). Assumption-free analysis of quantitative real-time PCR data. *Neuro Lett*, 13(339), 62-66.
- Rani, A., Sharma, A. (2013). The genus Vitex: a review. *Pharm Rev*. 7(14): 188-98.
- SAS Institute. (2005). SAS Users Guide: Statistics. Version 9.1. SAS Institute Inc., Cary, NC.
- Sabahi, R., Nazari, M., Beigi Nassiri, M. T., ghorbani, M. R. (2020). The Effect of Vitex Agnuse Castus fruit powder on hypothalamic GnRH gene expression in laying hens. *Research On Animal Production*, 11 (30), 92-100.
- Schweizer, G., Cadepond-Vincent, F., Baulieu, E.E. (1985). Nuclear Synthesis of Egg White Protein Messenger Ribonucleic Acids in Chick Oviduct: Effects of the Anti-Estrogen Tamoxifen on Estrogen-, Progesterone-, and Dexamethasone-Induced Synthesis. *Biochemistry*, 24(7), 1742-1749.
- Stadnicka, K., Sławińska, A., Dunisławska, A. et al. (2018). Molecular signatures of epithelial oviduct cells of a laying hen (*Gallus gallus domesticus*) and quail (*Coturnix japonica*). *BMC Developmental Biology*, 18, 9. <https://doi.org/10.1186/s12861-018-0168-2>
- Wuttke, W., Jarry, H., Christoffel, V., Spengler, B., Seidlova-Wuttke, D. (2003). Chaste tree (*Vitex agnus-castus*)— Pharmacology and clinical indications. *Phytomedicine*, 10, 348-57.
- Yildiz, F. (2005). Phytoestrogens in Functional Foods. Taylor & Francis. Ltd. Pp. 3-5, 210-211.
- Zamani, M., Neghab, N., Torabian, S. (2012). Therapeutic Effect of *Vitex Agnus Castus* in Patients with Premenstrual Syndrome. *Acta Medica Iranica*, 50(2), 101-106.

Received: 02.08.2022

Accepted: 30.01.2023

## Effects of *Froriepia subpinnata* extract on serum biochemicals and histopathological changes of liver in rats treated with trichloroacetic acid

Seyede Hamide Taheri Otaghsara<sup>1</sup>, Gasemali Garoosi<sup>2</sup>, Hossein Najafzadehvarzi<sup>3\*</sup> and Sohrab Kazemi<sup>4</sup>

<sup>1</sup> Student of Biotechnology, Imam Khomeiny International University (IKIU), Gazvin, Iran

<sup>2</sup> Associate Professor, Department of Biotechnology, Imam Khomeiny International University (IKIU), Gazvin, Iran

<sup>3</sup> Cellular and Molecular Biology Research Center, Health Research Institute, Babol University of Medical Sciences, Babol, Iran and Professor of Department of Pharmacology, Faculty of Medicine, Babol University of Medical Sciences, Babol, Iran

<sup>4</sup> Associate Professor, Cellular and Molecular Biology Research Center, Health Research Institute, Babol University of Medical Sciences

Received: 13.08.2022

Accepted: 18.12.2022

### Abstract

Hepatocellular carcinoma is one of the challenges in health system in occurrence of which oxidative stress plays an important role. Considering *Froriepia subpinnata* (Anarijeh=FS) antioxidant effects, this study aimed to investigate its effect on preventing the occurrence of liver toxicity induced by Trichloroacetic acid (TCA) in animal model. FS hydroalcoholic extract was prepared from the aerial parts by maceration method. Forty-eight rats were divided into 8 groups as: control animals, treated with TCA (500 mg/kg) TCA+FS treated groups (100, 200, 400 mg/ kg), FS treated group 400 mg/kg, and doxorubicin (DOX) treated group (at 2.5 mg/ kg) and TCA + DOX treated group. After 28 days, blood was collected and serum was isolated. then Malondialdehyde (MDA), Glutathione peroxidase (GPx), Total Antioxidant Capacity (TAC), alanine aminotransferase (ALT), aspartate aminotransferase (AST), Alkaline phosphatase (ALP), tumor necrosis factor-alpha (TNF-alpha) were measured followed by liver tissue examination of histopathologically by light microscope. TCA significantly increased the amount of MDA and FS, at different concentrations, (100, 200, and 400mg/kg) decreased it compared to other groups ( $P \leq 0.05$ ). The amount of TNF $\alpha$  was decreased by TCA but DOX increased considerably and FS treatment did not change the effect of TCA on TNF $\alpha$  level. Serum level of GPX, TAC, ALT, AST and ALP did not change by either TCA or FS treatment. TCA damaged liver tissue and caused hepatocyte degeneration, sinusoidal stenosis and vacuolization of cytoplasm. FS protected liver tissue in a dose dependent manner and at the dose of 400 mg/kg had better effect on reducing tissue damages. FS has a protective effect against histopathological changes induced by TCA in rat's liver tissue.

**Key words:** *Froriepia subpinnata*, Trichloroacetic acid, Oxidative stress, Hepatotoxicity

### Introduction

Hepatocellular carcinoma (HCC) is responsible for 5.5% of all cancer cases globally and the second leading cause of

cancer-related deaths worldwide (Seyfizadeh et al. 2019; Tupal et al. 2020). More than 90% of HCCs arise in the context

\* **Corresponding Author:** Hossein Najafzadehvarzi, Cellular and Molecular Biology Research Center, Health Research Institute, Babol University of Medical Sciences, Babol, Iran and Professor of Department of Pharmacology, Faculty of Medicine, Babol University of Medical Sciences, Babol, Iran  
E-mail: [h.najafzadeh@mubabol.ac.ir](mailto:h.najafzadeh@mubabol.ac.ir)



© 2020 by the authors. Licensee SCU, Ahvaz, Iran. This article is an open access article distributed under the terms and conditions of the Creative Commons Attribution-NonCommercial 4.0 International (CC BY-NC 4.0 license) (<http://creativecommons.org/licenses/by-nc/4.0/>).

of hepatic inflammation. Chronic liver inflammation leads to oxidative/nitrosative stress and lipid peroxidation (LPO), generating excess reactive oxygen species (ROS) and reactive nitrogen species (RNS) (Campos et al. 2020). Oxidative stress lead to damage of the liver which causes release of liver enzymes such as alanine aminotransferase, aspartate aminotransferase, and alkaline phosphatase into the plasma (Chen et al. 2020). On the other hand, one of the most important indicators of oxidative stress is malondialdehyde (Cherian et al. 2019). Moreover, ROS and RNS, as by-products of metabolism, are continuously produced in biological systems and cause damage to DNA, proteins and lipids. Recent studies indicate the role of ROS in enzymatic reactions, message transduction, and activation of nuclear transcription factors (Kruk et al. 2019). Mitochondrial electron transfer chain, nicotinamide adenine dinucleotide phosphate (NADPH) oxidase in phagocytic cell membranes, endoplasmic reticulum cytochrome P450 monooxygenase, xanthine oxidase, Fenton and Haber-Weiss reaction are responsible for ROS production in cell systems (Snezhkina et al. 2019). ROS modifies the function of proteins by regulating oxidation-reducing proteins, gene expression, redox-sensitive binding proteins, redox-sensitive enzymes, and regulating protein turnover (Zhang et al. 2016). Cancer cells produce more ROS than normal cells due to hypoxia, mutations in nuclear and mitochondrial genes, activation of oncogenes, and loss of tumor suppressor genes (Schumacker, 2006). In cancer cells, low to moderate levels of ROS are essential for cell development, differentiation, and survival, but at high levels it leads to cell death (Weinberg et al. 2010). Recent evidence suggests the role of ROS as a messenger in tumor cell invasion, angiogenesis and metastasis. Therefore, trying to reduce the ROS and NOS can be an adjunctive therapeutic strategy in the

treatment of liver cancer. On the other hand, synthetic antioxidants had side effects and attempts are being made to use natural antioxidants for this purpose (Wang et al. 2010).

Trichloroacetic acid (TCA) is produced in the liver by metabolizing trichlorethylene, which is one of the most widely used organic solvents in the industry and is considered the 16th most toxic substance in the list of toxic substances in the United States (Yoo et al. 2015). TCA is commonly used in many educational and research laboratories and have various toxic effects on organs causing tumors (Mather et al. 1990). TCA side effects and toxicity probably caused through oxidative stress parameters, for example, in a study by Alzergy and Elgharbawy (2017), it was shown that TCA causes serious damage to liver tissue via oxidative stress, and *Juniperus phoenicea* L. with antioxidant properties could be effective in reducing this toxicity. Plants containing chemicals such as flavonoids, tannins, phenolic acids, terpenoids are the source of potentially natural antioxidants. These compounds could have anti-inflammatory and anti-cancer activity (Huang et al. 2009). In the recent years, many studies have been conducted on herbal antioxidant sources which decrease the lipid peroxidation process and production of ROS (Devasagayam et al. 2004).

*Froriepia subpinnata* (FS) belongs to Apiaceae also called the Umbelliferae family (Parsley family) with approximately 400 genera. Moreover, FS genera is *Froriepia* including three species: *Froriepia subpinnata*, *Froriepia nuda* and *Froriepia gracillima*, among which *F. subpinnata* is the only species growing naturally in northern Iran (Bahrami et al. 2021). It is an edible biennial plant which grows up to 150 cm with anti-flatulence, antiseptic, antispasmodic, anti-cancer, antifungal, antimicrobial and diuretic properties (Mozaffarian, 2007). In spite of the wide uses of *FS* in traditional medicine, there are

only a few documents on chemicals and biological activities of this beneficial plant (Bahrami et al. 2021; Mohammadzadeh et al. 2018; Morteza-Semnani et al. 2009; Rustaiyan et al. 2001). Considering the importance of the toxic effects of TCA and its effect on various parameters including inflammatory factors and oxidative stress indicators, in this experimental study the role of hydroalcoholic extract of *FS* aerial organs against possible changes in oxidative stress indicators, tissue necrosis factor (TNF) and biochemical factors related to liver function was investigated in the serum of rats exposed to TCA.

## Materials and Methods

### Animals and environmental conditions

In this study, forty eight adult male Wistar Rats were purchased from laboratory animal center, Babol University of Medical Sciences, Iran. All of the rats were kept in the same environmental and nutritional conditions. The temperature of the storage room was 22-25° C also 12 hours of light and 12 hours of darkness were applied. Rats had free access to normal feed (pellet) and water, moreover, similar conditions were considered for them.

### Preparation of hydroalcoholic extract

To prepare the hydroalcoholic extract of *FS*, first, the aerial parts of *FS* were collected from forest of north of Iran – Mazandaran –Babol in spring and dried in the shade and then grinded to powder. Later, the extract was prepared by digestion with ethanol (80%). After evaporation of the solvent by evaporator apparatus, the dry matter was determined, and the obtained extract was stored in the refrigerator at 4 ° C for long-term storage.

### Experimental groups and dose selection

Rats were divided into 8 groups of six. Group 1 consisted of control animals, group 2 was treated with TCA (Scharlau- Spain) at a dose of 500 mg/kg orally for 5 consecutive days (TCA group), groups 3,

4,5 ,were first, treated with 500 mg/kg TCA orally for 5 consecutive days, and then given the hydroalcoholic extract of *FS* at the doses of 100, 200 and 400 mg/kg orally for 28 days, receptively (TCA + *FS*100, TCA + *FS*200, TCA + *FS*400). Group 6 was treated only with 400 mg/kg *FS* extract per day for 28 days (*FS* 400). Group 7 was treated with doxorubicin at a dose of 2.5 mg/kg intraperitoneally once a week for 4 weeks (DOX). Finally group 8 was first treated with 500 mg/kg of TCA for 5 consecutive days, and then with 2.5 mg/kg intraperitoneally doxorubicin once a week for 4 weeks (TCA + DOX). After 28 days, the rats were anesthetized and blood samples were taken from their eyes. The rats were scarified and their liver samples were taken for histopathological examination.

### Serum biochemistry

The method provided by Koroluk et al. (1988) was used for catalase measurement. The reaction of MDA to thiobarbituric acid produces a red colored complex that color intensity can be measured by spectrophotometry and has a direct relationship with the amount of MDA and ultimately with the oxidative stress (Placer et al. 1966). Enzyme activities, including ALT, AST, ALP, and TNF $\alpha$  were determined using commercial assay kits (Karmania pars gene, Iran), Gpx and total antioxidant capacity (TAC) were determined using commercial assay kits (Navand lab kit, Iran).

### Histopathological examination

For histopathological examination, first a slice of the liver was fixed in formalin solution for 2 weeks, then was set in paraffin, sectioned to 5  $\mu$ m thickness, deparaffinized, and rehydrated using standard techniques. The extent histological change was assessed with hematoxylin and eosin and recorded with a light microscope.

### Statistical analyses

Mean $\pm$  SEM was used for data expression. One-way analysis of variance followed by the LSD multiple comparison tests was used for results comparison. The data were analyzed with SPSS ver. 19. P-value  $\leq 0.05$  was considered statistically significant.

### Ethical consideration

All experiments complied with the ethical guidelines for the care and use of laboratory animals. Also the protocol of study was approved by Imam Khomeini International University of Qazvin University.

### Results

#### Results of biochemical factors

In ALT, difference was observed among control, TCA and TCA+DOX groups. Also, a significant decrease in liver AST was observed in the TCA group compared to the

control group ( $P \leq 0.05$ ). A significant decrease liver AST was observed in the TCA grouped compared to 100 and 400 mg/kg FS treated groups ( $P \leq 0.05$ ). Hepatic ALP showed significant increase in the TCA group treated with different concentrations of FS (100, 200, and 400 mg / kg) in comparison with control, TCA and TCA+DOX groups ( $P \leq 0.05$ ). More details are shown in table 1.

#### Results of inflammatory and oxidative stress factors

TNF- $\alpha$  showed a significant decrease in all groups except the DOX treated group compared to the control group. On the other hand, there was no significant difference between the FS treated groups (100, 200, and 400 mg/kg) with the TCA and TCA + DOX groups. Also, there was no significant difference in the catalase and total antioxidant capacity levels between groups. More details are shown in table 2.

**Table1: Mean  $\pm$ SEM of serum enzyme activity related to liver toxicity. Different letters show statistical differences between groups ( $p \leq 0.05$ )**

Group/ Variable	ALT( U/L)	AST( U/L)	ALP( IU/L)
Control	37.4 $\pm$ 3.57 <sup>a</sup>	130.83 $\pm$ 20.25 <sup>ac</sup>	259.23 $\pm$ 32.10 <sup>a</sup>
TCA	38.75 $\pm$ 2.06 <sup>ac</sup>	110.25 $\pm$ 6.29 <sup>b</sup>	272 $\pm$ 19.81 <sup>a</sup>
TCA+ A100	66.33 $\pm$ 4.93 <sup>d</sup>	129.5 $\pm$ 6.75 <sup>ac</sup>	697 $\pm$ 36.09 <sup>b</sup>
TCA+ A200	51 $\pm$ 2.44 <sup>bf</sup>	123 $\pm$ 4.58 <sup>abc</sup>	594.33 $\pm$ 90.23 <sup>c</sup>
TCA+ A400	57.33 $\pm$ 8.32 <sup>b</sup>	137 $\pm$ 6.55 <sup>c</sup>	417 $\pm$ 35.56 <sup>d</sup>
A400	46.25 $\pm$ 2.36 <sup>ef</sup>	117.33 $\pm$ 5.5 <sup>ab</sup>	303.5 $\pm$ 49.26 <sup>a</sup>
DOX	44.25 $\pm$ 4.57 <sup>ce</sup>	126.66 $\pm$ 11.7 <sup>ac</sup>	468.5 $\pm$ 75.67 <sup>d</sup>
TCA+ DOX	37.25 $\pm$ 6.07 <sup>a</sup>	120.33 $\pm$ 4.04 <sup>ab</sup>	313.66 $\pm$ 80.25 <sup>a</sup>

**Table2: Inflammatory and oxidative stress factors (mean  $\pm$ SEM). Different letters show statistical differences between groups ( $p \leq 0.05$ )**

Group/ Variable	TNF (pg/ml)	GPX (nmol/min/ml)	TAC(micromollar)	Catalase (nmol/min/ml)
Control	31.02 $\pm$ 6.6 <sup>a</sup>	5580 $\pm$ 1985 <sup>a</sup>	1.49 $\pm$ 0.35 <sup>a</sup>	0.14 $\pm$ 0.02 <sup>ab</sup>
TCA	15.30 $\pm$ 1.36 <sup>b</sup>	4875 $\pm$ 175.11 <sup>ab</sup>	1.43 $\pm$ 0.17 <sup>a</sup>	0.14 $\pm$ 0.01 <sup>ab</sup>
TCA+ A100	20.07 $\pm$ 5.73 <sup>b</sup>	4715 $\pm$ 644.43 <sup>ac</sup>	1.48 $\pm$ 0.12 <sup>a</sup>	0.13 $\pm$ 0.02 <sup>ab</sup>
TCA+ A200	15.78 $\pm$ 1.79 <sup>b</sup>	2828.33 $\pm$ 830.32 <sup>d</sup>	1.35 $\pm$ 0.09 <sup>a</sup>	0.12 $\pm$ 0.03 <sup>ab</sup>
TCA+ A400	13.64 $\pm$ 1.42 <sup>b</sup>	10405 $\pm$ 1969.59 <sup>e</sup>	1.41 $\pm$ 0.17 <sup>a</sup>	0.11 $\pm$ 0.02 <sup>ab</sup>
A400	15.19 $\pm$ 1.25 <sup>b</sup>	10121.66 $\pm$ 716.26 <sup>e</sup>	1.49 $\pm$ 0.23 <sup>a</sup>	0.15 $\pm$ 0.03 <sup>a</sup>
DOX	67.65 $\pm$ 21.78 <sup>c</sup>	3852.5 $\pm$ 497.75 <sup>cbd</sup>	1.41 $\pm$ 0.05 <sup>a</sup>	0.12 $\pm$ 0.007 <sup>ab</sup>
TCA+ DOX	14.23 $\pm$ 1.84 <sup>b</sup>	4138.33 $\pm$ 323.31 <sup>abd</sup>	1.53 $\pm$ 0.13 <sup>a</sup>	0.11 $\pm$ 0.03 <sup>b</sup>



A significant decrease in MDA was seen in the TCA groups with different concentrations of FS (100, 200, and 400mg/kg) compared to the control, TCA, TCA+DOX, and DOX groups (Figure1).

Regarding glutathione peroxidase, a significant difference was seen between glutathione peroxidase of other groups ( $P \leq 0.05$ ).

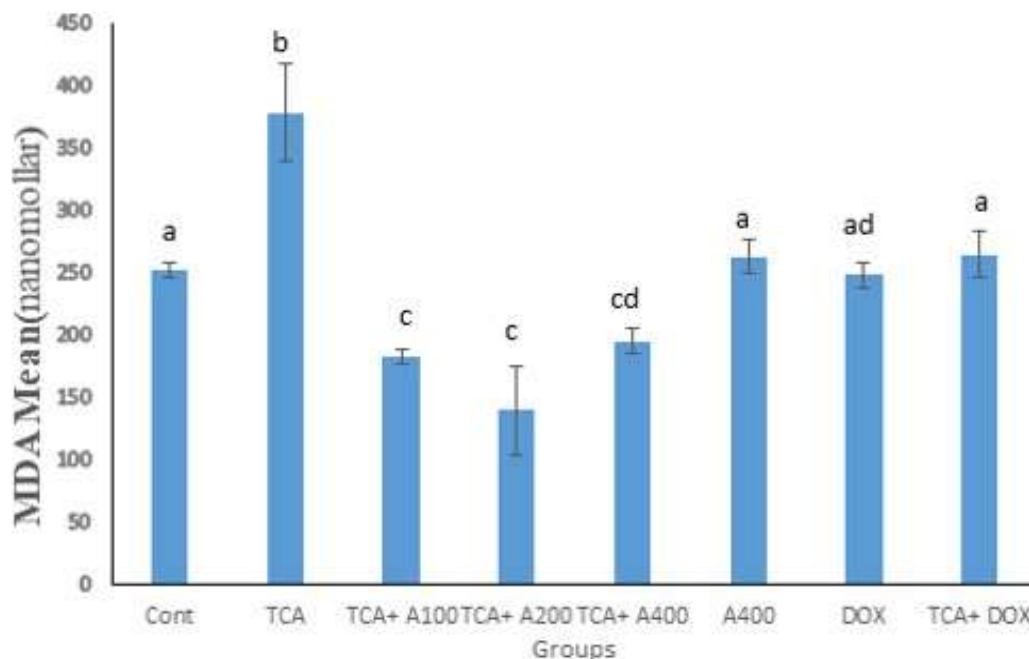
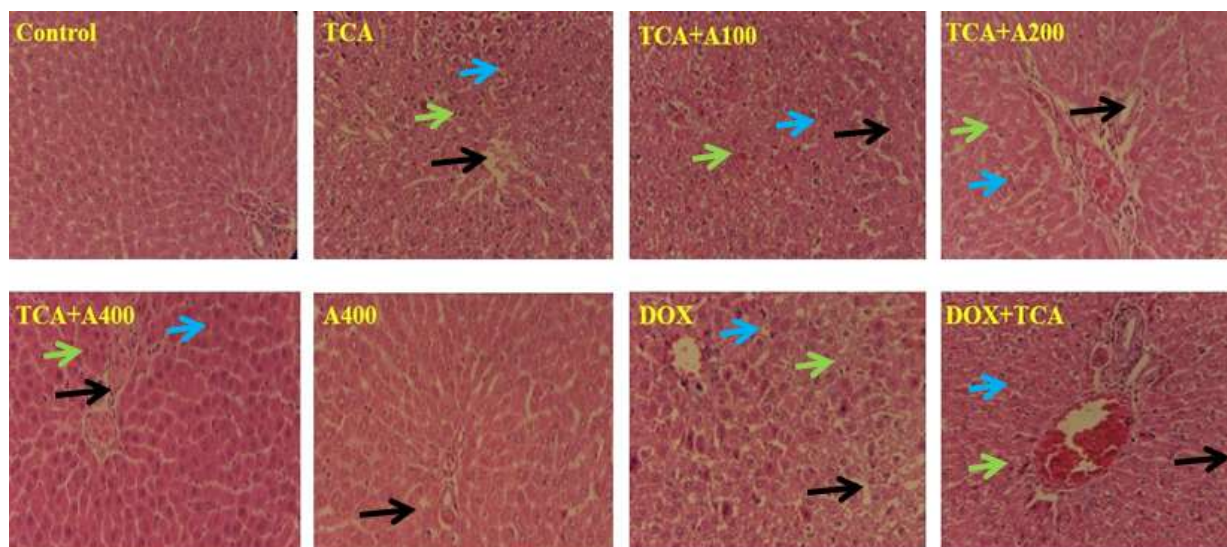


Figure1: Mean  $\pm$ SEM of MDA. Different letters show statistical differences between groups ( $P \leq 0.05$ )

### Histopathological results

Histological investigation showed that in TCA, DOX and TCA+DOX treatment causes loss of the radial arrangement of hepatocyte cords, hepatocyte degeneration, resulting in sinusoidal stenosis and vacuolization of cytoplasm. Also, the results showed that the FS at 100 mg/kg concentration has no significant effects on the TCA caused changes, although the FS with 100 mg/kg was able to partially neutralize the effects of TCA through the

reduction of necrotic, hypertrophied hepatocyte and congestion in portal vessels. It seems that the dose of 400 mg/kg of FS had significant effects in reducing the impression of TCA, because in the group treated with this dose, the radial arrangement of the hepatocyte cords is completely clear, the hepatocytes and Kupffer cells are of normal size, and there is effect congestion in portal vessels. More details are shown in figure 2.



**Figure2:** Liver tissue morphology in the studied groups. H & E (× 10). (black arrow: vacuolization, green arrow: degeneration, blue arrow: sinusoidal stenosis)

## Discussion

In the present study, TCA treatment (500 mg/kg), for 5 days, led to liver tissue damage and cell necrosis, focal hypertrophy of hepatocytes, narrowing of sinusoids and cytoplasmic vacuolation of hepatocytes in animal model. Moreover, an increase in serum MDA and decrease in serum TNF $\alpha$  in TCA treatment group compared to the control group were observed, but no effect on antioxidant factors such as the activity of glutathione peroxidase, catalase, total antioxidant levels and liver enzyme (ALT&ALP) was reported. Also in DOX treated rats increase of TNF was reported.

TCA is a chemical carcinogen that may cause experimental hepatocellular carcinoma (Caldwell and Keshava, 2006). Exposure to TCA for a short period causes pre-neoplastic lesions in the form of dysplastic tissue changes, vascular congestion, ballooning of liver cells and liver cell foci with extensive vacuolation (Abdel-Hamid et al. 2011; Alzergy et al. 2018). Previous studies have suggested increased oxidative stress and inflammation (Abdel-Hamid et al. 2011), hypo-methylation (Tao et al. 2004) as mechanisms were involved in the carcinogenic and metastatic effects of TCA. Our results show that TCA significantly

increased MDA compared to the control group. Lipid peroxidation, determined by the MDA index, is a key marker for oxidative stress estimation patients with liver cancer (Lorente et al. 2016). The oxidative effect of TCA can be considered by the increase of MDA along with the decrease of GSH level (as a non-enzymatic antioxidant) and the decrease of CAT and SOD activities.

In our study, the antioxidant factors including catalase, glutathione peroxidase enzymes and total antioxidant capacity in TCA treatment group have no significant difference compared to the control group. Although the dose of TCA used in the present study was similar to many previous studies, the observations were different from other studies. TCA causes inflammation and oxidative stress and is used to induce liver carcinoma in animal models (Fouad et al. 2013) through potential mechanisms including DNA hypo-methylation, peroxisome development, oncogene activation, and inhibition of intercellular communication (Hari Babu et al. 2012).

In addition, TCA significantly reduced TNF $\alpha$  compared to the control group. This may be related to long time (28 days) TCA

administration while the TNF $\alpha$  increases in acute phase of inflammation. However, doxorubicin significantly increased the TNF $\alpha$ . TNF $\alpha$  is an inflammatory factor that increases in the acute phase of inflammation. Fouad et al. (2013) investigated the possible anticancer effect of carnosine compared to doxorubicin in hepatocellular carcinoma (HCC) induced by TCA (500 mg/kg per day, for 5 days) in rats. After induction of HCC, rats were treated with carnosine (10 mg/kg/day, i.p.), or doxorubicin (2.5 mg/kg, i.p., once weekly) for 2 weeks. Carnosine significantly reduced serum ALT and hepatic lipid peroxidation, nitric oxide and TNF- $\alpha$  and significantly improved the total antioxidant status in TCA-treated Rats. The effects of doxorubicin on oxidative and inflammatory stress were lower than carnosine. However, carnosine and doxorubicin significantly induced apoptosis biomarkers, Bax, cytosolic cytochrome C and caspase-3. Furthermore, carnosine and doxorubicin reduced histopathological dysplastic changes and alpha-fetoprotein expression in the liver of Rats with HCC. Fouad et al. (2013) concluded that carnosine has protective effect on TCA-induced HCC in rats through antioxidant, anti-nitrative and anti-inflammatory and induction of apoptosis mechanisms. Moreover, Ibrahim et al. (2021) investigated the effect of Diacerein (DIA), an interleukin (IL)-1 $\beta$  inhibitor, on TCA-induced preneoplastic changes in animal model. In this study, animals were treated with 1 mg/kg TCA orally for 5 days. Serum liver enzymes, oxidative stress parameters, inflammatory interleukin-1 $\beta$  (IL-1 $\beta$ ), and angiogenesis marker (VEGF & HIF-1 $\alpha$ ) were evaluated along with histopathological changes and caspase-3 expression. The results showed that at the histological level, DIA improves the liver precancerous lesions through the modulation of the IL-1 $\beta$ -HIF-1 $\alpha$ -VEGF pathway (Ibrahim et al. 2021). In the current study, no significant change in the activity of liver damage

related enzymes (ALT, AST, ALP) with TCA treatment was observed, which is contrary to the results of many studies. In the study of Sweeney et al. (2009) results showed significant decrease in body weight of TCA-treated mice compared to control mice. Weight loss may be attributed to the cytotoxic effect of TCA, damage liver tissue. But we did not record rat's weight change at the end of our study. Liver damage caused by chemicals, led to secretion of ALT, AST, ALP to blood circulation system due to the change in the permeability of the liver cells membrane (Mabrouk et al. 2016).

Ni et al. (1996) reported that the biotransformation of TCA by cytochrome P450 led to production of dichloroacetic acid free radical which causes oxidative DNA damage and lipid peroxidation, so TCA induces hepatic oxidative stress. ALT activity usually increases in TCA hepatotoxicity. ALT is the most specific and sensitive biomarker for liver damage because it is mostly found in liver tissue and is located in hepatocyte cytosol. Although ALT isoenzymes are expressed in variety of tissues, elevated serum ALT activity is considered the "gold standard" clinical marker for liver injury (Davis, 1992; Wedemeyer et al. 2010). On the other hand, the significant increase in ALP enzyme activity as a marker for TCA-treated rats may be due to the obstruction of the bile duct, resulting in failure to excrete the enzyme (Wiwanitkit, 2001). Liver activity changes via TCA treatment. Mokhamer et al. (2022) reported that TCA treatment (500 mg/kg/day for 5 days) significantly increased the activity of ALT, AST, and ALP, as well as total serum bilirubin levels, while the activity of the antioxidant enzymes SOD and catalase, as well as the level of glutathione decreased. Total bilirubin is a sensitive biomarker for liver cell damage. Decreased biliary secretion of conjugated bilirubin compared to increased bilirubin caused by hemolysis leads to an increase in serum bilirubin. In liver tumors,

hemolysis and liver dysfunction lead to hyper-bilirubinemia (Gowda et al. 2009).

Sweeney et al. (2009) reported a significant increase in serum total bilirubin levels via TCA treatment, which may be due to jaundice caused by hepatocellular damage or ductal obstruction in HCC. In the current study, TCA treatment caused liver damage, so that different degrees of necrosis, degeneration and focal hypertrophy of hepatocytes were observed, which seems to be the initiation of cell tumorigenesis. The result of the present study is consistent with the results of those researchers that showed TCA treatment led to disordered liver structure with thick fibrous tissue septa and lymphocyte infiltration, as well as dilation and congestion of liver sinusoids with large vesicular nuclei. Oxidative stress, cytochrome P450 dysfunction, inflammation and mitochondrial dysfunction are considered as the main mechanisms explaining liver damage (Zhang et al. 2018). Fouad et al. (2013) investigation showed that TCA caused significant liver damage, which was observed in the form of vacuolization, irregular dysplasia of liver cells, polymorphic hyper-chromatic nucleus with more than one nucleus, increased nucleus-to-cytoplasmic ratio, and dense nucleus. In the study of Hari Babu et al. (2012) the

histo-pathological changes caused by TCA included vacuolation of hepatocytes, irregular dysplasia, polymorphous hyper-chromatic nucleus with more than one nucleus. Increased *FS* extract treatment reduces the tissue damage caused by TCA in a dose-dependent manner. In addition, it significantly reduced MDA as the oxidative stress index, which is probably related to the antioxidant properties of *FS*. Although studies related to the pharmacological properties of *FS* are limited, few studies confirm the anti-inflammatory and antioxidant properties of this plant. Bahrami et al. (2021) analyzed the chemical composition of the hexane extract of the aerial parts of *FS* by GC/MS and reported 21 compounds (80.60%) of the total including phytosterols and hydrocarbons. Also, a significant amount of flavonoids in the methanolic extract of *FS* ( $27.235 \pm 0.048 \mu\text{g/ml}$ ) was estimated by  $\text{AlCl}_3$  colorimetric method. Two flavonoids, rutin and catechin, were identified in the methanol extract of *FS* by HPLC (Abu-Odeh and Talib, 2021). So, *FS* has a variety of useful natural compounds that make it a promising plant for agricultural and medicinal purposes.

*FS* has a protective effect against histopathological changes induced by TCA in rat's liver tissue.

### Acknowledgments

The authors wish to thank the Research Deputy of Imam Khomeiny International Gazvin University and Research and Technology Deputy of Babol University of Medical Sciences for the funding and approval. Also we appreciate Dr. Aliakbar Rajabzadeh (department of Anatomy) from Babol University of Medical Sciences and Iran National Science Foundation for cooperation. Also we thank the Biotechnology Development Council of the Islamic Republic of Iran for supporting by grant no: 970902.

### Conflict of interest

Authors have no conflict of interest.

### Funding

This study was supported by Research Deputy of Imam Khomeiny International Gazvin University.

## References

- Abdel-Hamid, N., Fawzy, M., & El-Moselhy, M. (2011). Evaluation of hepatoprotective and anticancer properties of aqueous olive leaf extract in chemically induced hepatocellular carcinoma in rats. *Am J Med Med Sci*, 1(1), 15-22.
- Abu-Odeh, A. M., & Talib, W. H. (2021). Middle East medicinal plants in the treatment of diabetes: a review. *Molecules*, 26(3), 742.
- Alzergy, A., Haman, M. R., Shushni, M. A., & Almagtoub, F. A. (2018). Phyto-pharmaceuticals and biological study on graviola (*Annona muricata* L.) fruit and dietary supplement of graviola sold on the Libyan market as a cancer cure against TCA induce hepatotoxicity in mice. *Cancer Biol Ther*, 8(2), 1-23.
- Alzergy, A. A., & Elgharbawy, S. M. (2017). Hepatoprotective effects of *Juniperus phoenicea* L. on trichloroacetic acid induced toxicity in mice: Histological, Ultrastructure and Biochemical Studies. *J. Am. Sci.* 2017, 13 (12), 41, 61.
- Bahrami, A., Jamzad, M., & Sedaghat, S. (2021). Phytochemicals and Biological Activities of *Foriopia subpinnata* (Ledeb.) Baill. Extracts. *Journal of Medicinal plants and By-product*, 10(1), 109-115.
- Caldwell, J. C., & Keshava, N. (2006). Key issues in the modes of action and effects of trichloroethylene metabolites for liver and kidney tumorigenesis. *Environmental Health Perspectives*, 114(9), 1457-1463.
- Campos, G., Schmidt-Heck, W., De Smedt, J., Widera, A., Ghallab, A., Pütter, L., . . . Marchan, R. (2020). Inflammation-associated suppression of metabolic gene networks in acute and chronic liver disease. *Archives of Toxicology*, 94(1), 205-217.
- Chen, Z., Tian, R., She, Z., Cai, J., & Li, H. (2020). Role of oxidative stress in the pathogenesis of nonalcoholic fatty liver disease. *Free Radical Biology and Medicine*, 152, 116-141.
- Cherian, D. A., Peter, T., Narayanan, A., Madhavan, S. S., Achammada, S., & Vynat, G. P. (2019). Malondialdehyde as a marker of oxidative stress in periodontitis patients. *Journal of pharmacy & bioallied sciences*, 11(Suppl 2), S297.
- Davis, M. E. (1992). Dichloroacetic acid and trichloroacetic acid increase chloroform toxicity. *Journal of Toxicology and Environmental Health, Part A Current Issues*, 37(1), 139-148.
- Devasagayam, T., Tilak, J., Boloor, K., Sane, K. S., Ghaskadbi, S. S., & Lele, R. (2004). Free radicals and antioxidants in human health: current status and future prospects. *Japi*, 52(794804), 4.
- Fouad, A. A., Al-Mulhim, A. S., & Jresat, I. (2013). Therapeutic effect of coenzyme Q10 against experimentally-induced hepatocellular carcinoma in rats. *Environmental toxicology and pharmacology*, 35(1), 100-108.
- Gowda, S., Desai, P. B., Hull, V. V., Avinash, A. K., Vernekar, S. N., & Kulkarni, S. S. (2009). A review on laboratory liver function tests. *The Pan african medical journal*, 3.
- Hari Babu, L., Perumal, S., & Balasubramanian, M. P. (2012). Myrtenal attenuates diethylnitrosamine-induced hepatocellular carcinoma in rats by stabilizing intrinsic antioxidants and modulating apoptotic and anti-apoptotic cascades. *Cellular oncology*, 35(4), 269-283.
- Huang, W.-Y., Cai, Y.-Z., & Zhang, Y. (2009). Natural phenolic compounds from medicinal herbs and dietary plants: potential use for cancer prevention. *Nutrition and Cancer*, 62(1), 1-20.
- Ibrahim, Y. F., Refaie, M. M., Kamel, M. Y., Ahmed, S. M., Moussa, R. A., Bayoumi, A. M., & Ibrahim, M. A. (2021). Molecular mechanisms underlying the effect of diacerein on trichloroacetic acid-induced hepatic pre-neoplastic lesions in rats. *Human & Experimental Toxicology*, 40(12\_suppl), S788-S803.
- Koroliuk, M., Ivanova, L., Maïorova, I., & Tokarev, V. (1988). A method of determining catalase activity. *Laboratornoe delo*(1), 16-19.
- Kruk, J., Aboul-Enein, H. Y., Kładna, A., & Bowser, J. E. (2019). Oxidative stress in biological systems and its relation with pathophysiological functions: the effect of physical activity on cellular redox homeostasis. *Free radical research*, 53(5), 497-521.
- Lorente, L., Rodriguez, S. T., Sanz, P., Abreu-González, P., Díaz, D., Moreno, A. M., . . . Barrera, M. A. (2016). Association between pre-transplant serum malondialdehyde levels and survival one year after liver transplantation for hepatocellular carcinoma. *International journal of molecular sciences*, 17(4), 500.
- Mabrouk, A., Bel Hadj Salah, I., Chaieb, W., & Ben Cheikh, H. (2016). Protective effect of thymoquinone against lead-induced hepatic toxicity in rats. *Environmental Science and Pollution Research*, 23(12), 12206-12215.

- Mather, G. G., Exon, J. H., & Koller, L. D. (1990). Subchronic 90 day toxicity of dichloroacetic and trichloroacetic acid in rats. *Toxicology*, 64(1), 71-80.
- Mohammadzadeh, M., Mahmoudi, R., & Ghajarbeygi, P. (2018). Evaluation of chemical composition and antibacterial properties of *Froriepia subpinnta* essential oils from guilan region: Before and after flowering. *Journal of Essential Oil Bearing Plants*, 21(4), 1119-1127.
- Mokhamer, E.-H. M., Zidan, A.-A. A., & Abdel-Aziz, K. K. (2022). Attenuation of trichloroacetic acid-induced hepatocellular carcinoma by *Artemisia judaica* ethanolic extract in male rats. *The Journal of Basic and Applied Zoology*, 83(1), 1-10.
- Morteza-Semnani, K., Saeedi, M., & Akbarzadeh, M. (2009). The Essential Oil Composition of *Froriepia subpinnata* (Ledeb.) Baill. *Journal of Essential Oil Research*, 21(2), 127-128.
- Mozaffarian, V. (2007). Umbelliferae-In: Assadi M., Khatamsaz M. & Maassoumi AA (ed.), *Flora of Iran 54. Tehran: Research Institute of Forests and Rangelands [in Farsi]*.
- Ni, Y.-C., Wong, T.-Y., Lloyd, R. V., Heinze, T. M., Shelton, S., Casciano, D., . . . Fu, P. P. (1996). Mouse liver microsomal metabolism of chloral hydrate, trichloroacetic acid, and trichloroethanol leading to induction of lipid peroxidation via a free radical mechanism. *Drug metabolism and disposition*, 24(1), 81-90.
- Placer, Z. A., Cushman, L. L., & Johnson, B. C. (1966). Estimation of product of lipid peroxidation (malonyl dialdehyde) in biochemical systems. *Analytical biochemistry*, 16(2), 359-364.
- Rustaiyan, A., Mojab, R., Kazemie-Piersara, M., Bigdeli, M., Masoudi, S., & Yari, M. (2001). Essential oil of *Froriepia subpinnata* (ledeb.) baill. from Iran. *Journal of Essential Oil Research*, 13(6), 405-406.
- Schumacker, P. T. (2006). Reactive oxygen species in cancer cells: live by the sword, die by the sword. *Cancer cell*, 10(3), 175-176.
- Seyfizadeh, N., Tazehkand, M., Palideh, A., Maroufi, N., Hassanzadeh, D., Rahmati-Yamchi, M., . . . Borzoueisileh, S. (2019). Is arbutin an effective antioxidant for the discount of oxidative and nitrosative stress in Hep-G2 cells exposed to tert-butyl hydroperoxide? *Bratislavske lekarske listy*, 120(8), 569-575.
- Snezhkina, A. V., Kudryavtseva, A. V., Kardymon, O. L., Savvateeva, M. V., Melnikova, N. V., Krasnov, G. S., & Dmitriev, A. A. (2019). ROS generation and antioxidant defense systems in normal and malignant cells. *Oxidative medicine and cellular longevity*, 2019.
- Sweeney, L. M., Kirman, C. R., Gargas, M. L., & Dugard, P. H. (2009). Contribution of trichloroacetic acid to liver tumors observed in perchloroethylene (perc)-exposed mice. *Toxicology*, 260(1-3), 77-83.
- Tao, L., Li, Y., Kramer, P. M., Wang, W., & Pereira, M. A. (2004). Hypomethylation of DNA and the insulin-like growth factor-II gene in dichloroacetic and trichloroacetic acid-promoted mouse liver tumors. *Toxicology*, 196(1-2), 127-136.
- Tupal, A., Sabzichi, M., Bazzaz, R., Fathi Maroufi, N., Mohammadi, M., Pirouzpanah, S. M., & Ramezani, F. (2020). Application of  $\alpha$ -tocotrienol-loaded biocompatible precirrol in attenuation of doxorubicin dose-dependent behavior in HUH-7 hepatocarcinoma cell line. *Nutrition and Cancer*, 72(4), 653-661.
- Wang, Z., Li, Y., & Sarkar, F. H. (2010). Signaling mechanism (s) of reactive oxygen species in epithelial-mesenchymal transition reminiscent of cancer stem cells in tumor progression. *Current stem cell research & therapy*, 5(1), 74-80.
- Wedemeyer, H., Hofmann, W., Lueth, S., Malinski, P., Thimme, R., Tacke, F., & Wiegand, J. (2010). ALT screening for chronic liver diseases: scrutinizing the evidence. *Zeitschrift fur Gastroenterologie*, 48(1), 46-55.
- Weinberg, F., Hamanaka, R., Wheaton, W. W., Weinberg, S., Joseph, J., Lopez, M., . . . Chandel, N. S. (2010). Mitochondrial metabolism and ROS generation are essential for Kras-mediated tumorigenicity. *Proceedings of the National Academy of Sciences*, 107(19), 8788-8793.
- Wiwanitkit, V. (2001). High serum alkaline phosphatase levels, a study in 181 Thai adult hospitalized patients. *BMC family practice*, 2(1), 1-4.
- Yoo, H. S., Bradford, B. U., Kosyk, O., Uehara, T., Shymonyak, S., Collins, L. B., . . . Rusyn, I. (2015). Comparative analysis of the relationship between trichloroethylene metabolism and tissue-specific toxicity among inbred mouse strains: kidney effects. *Journal of Toxicology and Environmental Health, Part A*, 78(1), 32-49.



Zhang, C., Wang, N., Xu, Y., Tan, H.-Y., Li, S., & Feng, Y. (2018). Molecular mechanisms involved in oxidative stress-associated liver injury induced by Chinese herbal medicine: An experimental evidence-based literature review and network pharmacology study. *International journal of molecular sciences*, 19(9), 2745.

Zhang, J., Wang, X., Vikash, V., Ye, Q., Wu, D., Liu, Y., & Dong, W. (2016). ROS and ROS-mediated cellular signaling. *Oxidative medicine and cellular longevity*, 2016.

Received: 13.08.2022

Accepted: 18.12.2022

## The study of fat, Protein, and production levels of milk in Holstein dairy cows treated with arginine

Ali Tirgari<sup>1</sup>, Majid Mohammadsadegh<sup>2\*</sup>, Morteza Gorjidoz<sup>3</sup>, Ali Afshar Bahrabad<sup>4</sup>  
and Nima Farzaneh<sup>5</sup>

<sup>1</sup> DVM Graduated, Faculty of Veterinary Medicine, Garmsar Branch, Islamic Azad University, Garmsar, Iran

<sup>2</sup> Associate Professor, Department of Clinical Sciences, Faculty of Veterinary Medicine, Garmsar Branch, Islamic Azad University, Garmsar, Iran

<sup>3</sup> Assistant Professor, Department of Clinical Sciences, Faculty of Veterinary Medicine, Garmsar Branch, Islamic Azad University, Garmsar, Iran

<sup>4</sup> DVSc Graduate, Department of Theriogenology, Faculty of Veterinary Medicine, Ferdowsi University of Mashhad, Mashhad, Iran

<sup>5</sup> Professor, Department of Clinical Sciences, Faculty of Veterinary Medicine, Ferdowsi University of Mashhad, Mashhad, Iran

Received: 27.10.2022

Accepted: 30.11.2022

### Abstract

In this study, 73 non-pregnant and clinically healthy and lactating Holstein cows without any clinical signs, and with a mean parity of  $3.2 \pm 1.4$ , days in milk at the beginning of study  $110 \pm 20$  days, body condition score (BCS) of about  $3.2 \pm 0.3$ , and milk production rate of  $48 \pm 10$  kg were selected and randomly placed in two treatment and control groups. In the treatment group ( $n=36$ ), arginine ( $155 \mu\text{mol} / \text{kg}$  body weight) was injected once every 8 hours a day for 6 days, and in the control group ( $n=37$ ) saline solution ( $0.11 \text{ ml/kg}$  body weight, once every 8 hours a day) was injected for 6 days. The results showed that there was no difference between the treatment and the control group in terms of milk production ( $38.5$  and  $36$  kg,  $P=0.3$ ), fat ( $3.7$  and  $3.8\%$ ,  $P=0.8$ ) and protein ( $3.1$  and  $3.1\%$ ,  $P=0.5$ ) levels. It was concluded from this study that the use of arginine after the peak of milk production could not increase the fat, protein, and production levels of milk.

**Keywords:** Arginine, Amino Acid, Holstein Cow, Milk Production, Milk Fat and protein

### Introduction

Many hormonal and non-hormonal products have been used to increase the milk production levels before or after the peak of milk production in dairy cows. Abomasal infusions of protein increased milk production via the changes in plasma concentrations of galactopoietic hormones (Clark, 1975). Growth hormone increased milk protein concentration and milk

production levels (Burton et al, 1994) in mild and/or late-lactation in ewes (Chiofalo et al, 1999; Sallam et al, 2005) goats (Disenhaus et al, 1995) and cattle (Hayashi et al, 2009). Thyroid hormones or iodinated casein (thyroprotein) have been used to increase milk production (Squires, 2003), but any net benefit has not been encountered.

\* **Corresponding Author:** Majid Mohammadsadegh, Associate Professor, Department of Clinical Sciences, Faculty of Veterinary Medicine, Garmsar Branch, Islamic Azad University, Garmsar, Iran  
E-mail: [Majid.Mohammadsadegh@iau.ac.ir](mailto:Majid.Mohammadsadegh@iau.ac.ir)



© 2020 by the authors. Licensee SCU, Ahvaz, Iran. This article is an open access article distributed under the terms and conditions of the Creative Commons Attribution-NonCommercial 4.0 International (CC BY-NC 4.0 license) (<http://creativecommons.org/licenses/by-nc/4.0/>).

Arginine is a conditionally essential amino acid that enhances casein synthesis in bovine mammary epithelial cells, so it should be able to enhance milk production (Wang et al, 2014). On the other hand, intravenous injection of arginine increases plasma concentrations of somatotropin (bST), nitric oxide (NO) (Mephram, 1982; Moncada and Higgs, 1993), insulin, prolactin, and placental lactogen in plasma of ruminants (Hertelendy et al, 1968; Chew et al, 1984; Hertelendy et al, 1969; Hertelendy et al, 1970; McAtee, 1971; McAtee and Trenkle, 1971; Davis, 1972). On the other hand, growth hormone or bovine somatotropin (bST) promotes some degrees of insulin resistance, lipolysis and  $\beta$ -hydroxy butyric acid (BHBA), non esterified fat acid (NEFA), oxidative stress (Zheng et al, 2018) and reduced glucose consumption (Azarbayejani and Mohammadsadegh, 2021; Oliveira et al, 2016), and total antioxidant capacity (TAC) (Zheng et al, 2018). The last findings probably show the reason for the decrease in milk in some studies following the use of arginine.

This article aimed to study the quantitative and qualitative change in the milk of Holstein cows after 6 days of intravenous injection of arginine at 110 days after calving.

## Materials and method

### Farms and animals' selection

Two dairy herds with about 3000 milking cows (HF=100%) and the same management around Varamin city in Tehran province were selected. The study was conducted from December 2018 (cold month in the region) to May 2019 (temperate month in the region) during 7 months. The cattle corral pen was a free stall, and the diet was adjusted by TMR twice a day based on the National Research council (NRC 2001). The average annual milk was 41 kg, and the animals were milked three times a day. To provide the required livestock in the study, 73 non-

pregnant and clinically healthy and lactating Holstein cows without any clinical signs, and with a mean parity of  $3.2 \pm 1.4$ , days in milk at the beginning of the study  $110 \pm 20$  days, BCS of about  $3.2 \pm 0.3$  and milk production rate of  $48 \pm 10$  kg were selected and randomly divided into two experimental and control groups.

Since the effect of arginine injection on the milk production before (Ding et al. 2019) and during the peak of lactation (Chew et al. 1984) was previously investigated, its effect after the peak of lactation and in the period carried out in this article was planned.

### Animal groups and treatments

In the experimental group (n=36 cows), arginine (Arginine HCl, Merk co. Germany) was intravenously injected into jugular vein ( $155 \mu\text{mol} / \text{kg}$  body weight, equivalent to  $0.032 \text{ gr/kg}$ ) once every 8 hours a day for 6 days based on Lassala et al. 2009; however, in the control group (n=37 cows) saline solution (daily  $0.11 \text{ ml/kg}$  body weight, every 8 hours) was injected once every 8 hours a day for 6 days as a placebo.

### Blood and milk samplings

Milk samples were taken before and after 8 hours of the last arginine injection.

Before and after the arginine injection period, and daily milk production was estimated from all animals and milk samples were prepared and sent to the laboratory to measure the amount of fat and protein.

Blood samples were taken from the Coccidia vein and were prepared in 9 ml vacuum silicone tubes. Then the samples were placed in the environmental condition for one hour and then, using a centrifuge at a speed of 3000 rpm for 10 minutes, and their serum was isolated and placed at  $-70^\circ\text{C}$ . A refrigerator was used to carry the sample to the laboratory with a temperature of  $-4^\circ\text{C}$  so that the samples would not be

frozen and heat stress would not damage the samples.

#### Laboratory tests

Nitric oxide (ELISA 96 NATRIX diagnostic kit of Navand Salamat co., IRAN; with product code 15042NS), total antioxidant capacity (ELISA 96 diagnostic kit NAXIFER test of Navand Salamat co., IRAN; with product code 15012NS), Non esterified fatty acid (ELISA 96 RANBUT test kit by RANDOX English co., IRAN; with product code RX MONZA FA - 115), and beta-hydroxybutyric acid (ELISA 96 RANBUT test kit by RANDOX English co., IRAN; with product code RX MONAZA RB - 1007) were measured in serum samples in the laboratory.

#### Definition of research variables

In this study, arginine treatment was considered as an independent variable, the level of fat, protein, and production of milk as the dependent variable, and parity, days in milk, and BCS as confounding variables. Since the use of arginine could also increase the serum concentration of NEFA, bHBA, TAC, and NO, recent variables were also considered as under monitoring dependent variables.

#### Statistical analysis of data

In comparing statistical analysis of quantitative data such as fat, protein and the levels of milk production, serum concentrations of nitric oxide, total antioxidant capacity, NEFA and bHBA, first Shapiro-Wilk test and Kolmogorov-Smirnov test were used to check the normality of the distribution. Quantitative normal data were compared with the Student T-test and abnormal data were compared with Wilcoxon-rank-Sign and Mann-Whitney-U test. The 95% statistical confidence interval and the probability of type 1 error or significance level was considered 0.05. IBM SPSS version 24 (2018) and MEDICAL version 13 (2015) Software were used in data analysis.

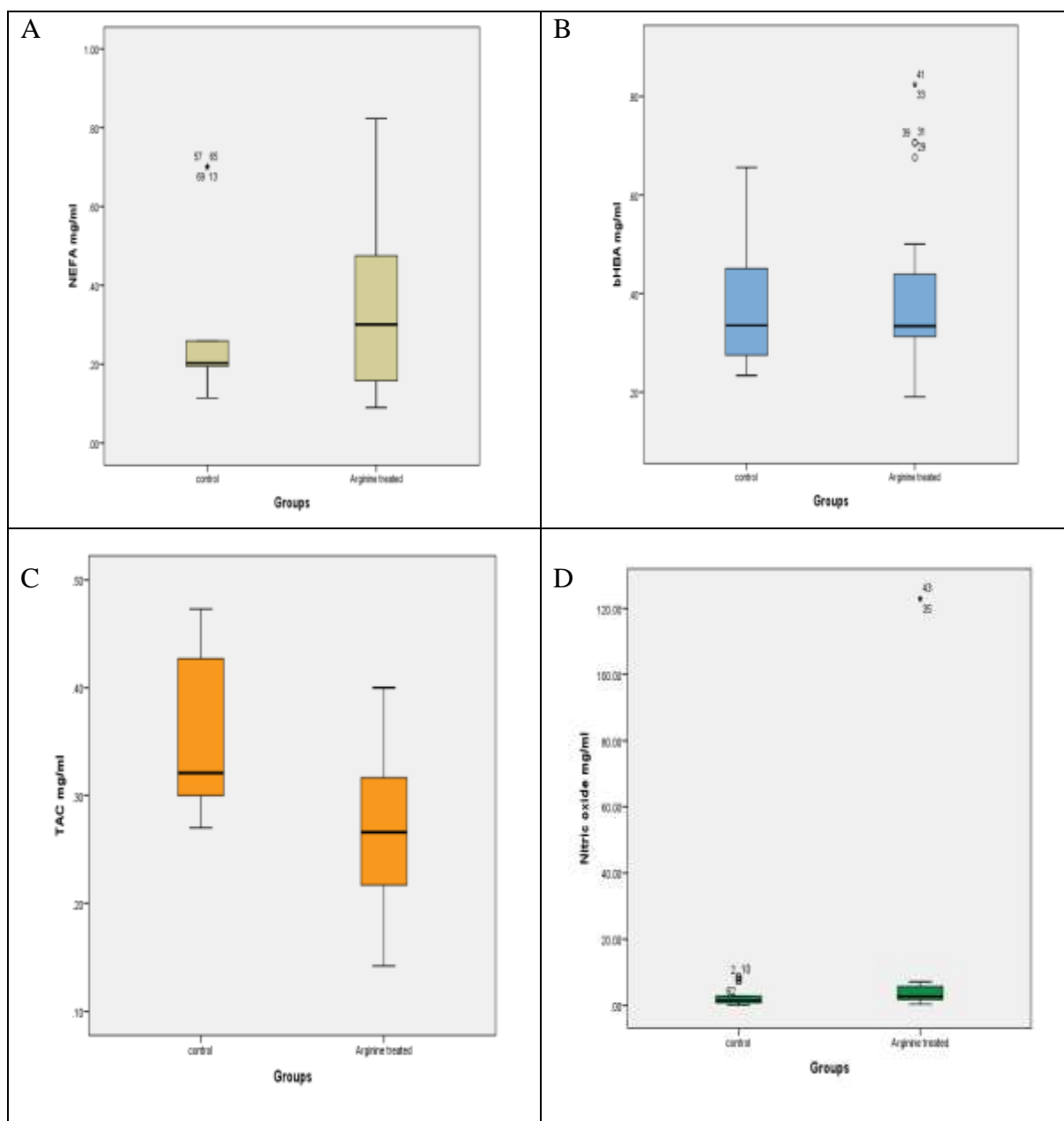
#### Results

Shapiro-Wilk and Kolmogorov-Smirnov tests showed that none of the measurable research data had a normal distribution. The median milk production after the study was 38.5 kg in the experimental, and 36 kg in the control group ( $P = 0.3$ ) (Table 3-1). The median milk production before the study ( $P=0.70$ ) and also the difference in milk production ( $P=0.80$ ) before and after injection in the two groups were not significantly different (Table 3-1). The median milk fat content after the study was 3.8% in the control group and 3.7% in the experimental group ( $P = 0.8$ ) (Table 3-1). The median milk protein after the study in the control group was 13. and in the experimental group was 3.1% ( $P = 0.5$ ) (Table 3-1). The median bHBA was 0.32 mg in the control, and 0.33 mg /ml in the experimental group ( $P = 0.2$ ) (Table 2-3). The median NEFA was 0.2 mg in the control and 0.3 mg / ml in the experimental group ( $p = 0.13$ ). The median NO was 1.3 in the control, and 2.4 mg /ml in the experimental group ( $p = 0.1$ ). The median TAC was 0.32 in the control and 0.27 mg /ml in the experimental group ( $p = 0.001$ ).

In comparison to confounder variables, the median age in the control was 1690 and in the experimental group was 1676 days ( $P = 0.37$ ). The median parity in control was 3 and in the experimental group was 2.5 ( $P = 0.16$ ). The median BCS in both groups was 3.2 ( $P = 0.8$ ). The median interval between parturition and the beginning of the study was 221 days in the control and 211 days in the experimental group ( $P = 0.1$ ). The median milk production before the start of the study was 44.7 kg in the control group and 40.7 kg in the experimental group ( $P = 0.7$ ). The median amount of peak milk production before the start of the study in the control was 49.2 kg and in the experimental group it was 47.5 kg ( $P = 0.9$ ). The median milk somatic cell count in the control was 48,000, and in the experimental group 95,000 ( $P = 0.00$ ); however, both were at the normal range.

**Table 1. Comparison of milk, fat, and protein production before and after the study between the control and experimental groups**

Data	Groups								P=
	control				Arginine treated				
	Mean	SD	Median	95% CI	Mean	SD	Median	95% CI	
Milk (kg)after study	36.5	10.9	36	31.1 - 40.7	36.5	37.9	5.6	38.5	0.3
Milk fat (%)	3.6	0.5	3.8	3.4 - 3.8	3.6	1	3.7	3.6 - 3.9	0.8
Milk pro (%)	3.1	0.2	3.1	3.0 - 3.2	3.1	0.3	3.1	3.7 - 3.2	0.5
Milk (kg) before study	42.1	5.2	44.7	38.20- 46.	41.7	8	40.8	38.4 - 44.2	0.7
Milk difference	-4.16	3.3	-4.7	-6.6 - -2.9	-5.3	6.8	-3.7	-5.5 - -1.6	0.8



**Figure 1. Comparison of NEFA (A), bHBA (B),TAC (C), and Nitric Oxide (D) levels at the end of the study between the control and experimental (arginine treated) groups.**

## Discussion

The main hypothesis of the present study was that the use of arginine increases milk production while no significant increase was observed in our results. The lack of milk increase in the present article is consistent with the results of some research. Twelve days infusion of 25 g/day L-arginine in goats could not increase milk production and concentrations of bST in plasma (Gow et al, 1979).

The lack of milk increase in the present paper conflicts with the results of some studies. It is reported that daily injections of 0.1/kg body weight L-arginine into the jugular vein of 8 cows during a 4 to 5-min period for about 7 d just before parturition caused plasma concentrations of prepartum bST, prolactin, and insulin, and postpartum milk production to increase (Chew et al, 1984). On the other hand, infusion of Arg via the jugular vein from 20 days after calving for one week in 6 Holstein cows had a positive effect on the synthesis of milk protein (Ding et al, 2019). One of the possible reasons for not increasing milk with Arginine consumption in the present study could be the low amount of medication used. We used about 19.2 g per injection in Holstein cows with about 600 kg, but Chew (1984) used about 60 grams per day of arginine and observed an increase in milk production. Nevertheless, Vicini et al, (1988) could not increase milk production of cows by infusion or intravenous injection of L-arginine. They concluded that the lack of changes in milk production and milk composition suggest that acute increases in somatotropin with concomitant increases in insulin are not sufficient to stimulate the synthesis of milk and milk components by cows during established lactation. In most trials, the intravenous injection of arginine was for a short time, usually about 5 min, and produced a brief increase in plasma hormone concentrations (Hertelendy et al, 1968; Chew et al, 1984; Hertelendy et al, 1969; Hertelendy et al, 1970; McAtee,

1971; McAtee and Trenkle, 1971; Davis, 1972). Repeated injections or perfusion of the drug into the serum may have better results in milk production. Interestingly, similar to the present study, Vicini et al, (1988) used L-arginine after the peak of milk lactation; similarly, they did not observe an increase in milk production. Increasing the duration of arginine injection increases the possibility of increasing milk production. The reason for our limited use of arginine was the fear of its potential dangers such as insulin resistance, ketosis and increased BHAB and NEFA.

Another hypothesis of the study was that if the injection of arginine increases milk production, it may reduce the concentration of fat and protein in milk, but none of the desired changes were observed.

The confounding variables were compared because their differences could affect milk or fat and milk protein production apart from the arginine effect. The similarity of confounding variables such as age, parity, SCC, and the intervals between parturition to the beginning of the study between the two groups showed that the amount of milk or fat and milk protein production is not affected and only the independent variable (use of arginine) can affect them.

Since arginine causes an increase in NO nitric oxide (Moncada and Higgs, 1993; Mephram, 1982), changes in arginine could be due to an increase of NO serum concentration; so, it was evaluated but no change was observed between groups.

On the other hand, increasing the absorption, excretion, and catabolism of fatty acids may also provide a possibility of altering the release of reactive oxygen species (ROS) (Seifert et al. 2010), so serum concentration of TAC was used to measure the release of reactive oxygen species (ROS). In our findings, TAC decreased, which could be a sign of the consumption of effective factors in active oxygen control. According to the findings

of Zheng et al, (2013), the use of 1.5% L-arginine supplementation caused oxidative stress in weaned piglets. The findings of Zheng et al, (2018) on low-birth-weight piglets showed that the use of 1% L-arginine oral supplement in a route separate

from the nitric oxide pathway increased the antioxidant capacity.

It was concluded, from this study, that the injection of arginine in Holstein cows did not change fat, protein, and milk production.

## Acknowledgments

The authors would like to thank the manager and the staff of Saffary dairy farms for their supports in the implementation of the present research.

## Conflict of interest

The authors declare that they have no conflict of interest.

## Funding

The research was funded by the first author, Dr. Ali Tirgari because he used its results to produce a DVM thesis.

## References

- Azarbayejani, R., & Mohammadsadegh, M. (2021). Glucose, insulin, and cortisol concentrations and glucose tolerance test in Holstein cows with inactive ovaries. *Tropical Animal Health and Production*, 53(1), 41. doi.org/10.1007/s11250-020-02448-7
- Burton, J. L., McBride, B. W., Block, E., Glimm, D. R., & Kennelly, J. J. (1994). A review of bovine growth hormone. *Canadian Journal of Animal Science*, 74(2), 167-201. doi: 10.4141/cjas94-027.
- Chiofalo, V., Baldi, A., Savoini, G., Polidori, F., Dell'Orto, V., & Politis, I. (1999). Response of dairy ewes in late lactation to recombinant bovine somatotropin. *Small Ruminant Research*, 34(2), 119-125. doi: 10.1016/S0921-4488(99)00061-9.
- Chew, B. P., Eisenman, J. R., & Tanaka, T. S. (1984). Arginine infusion stimulates prolactin, growth hormone, insulin, and subsequent lactation in pregnant dairy cows. *Journal of Dairy Science*, 67(11), 2507-2518.
- Clark, J. H. (1975). Lactational responses to postpartum administration of proteins and amino acids. *Journal of Dairy Science*, 58(8), 1178-1197.
- Davis, S. L. (1972). Plasma levels of prolactin, growth hormone, and insulin in sheep following the infusion of arginine, leucine and phenylalanine. *Endocrinology*, 91(2), 549-555.
- Ding, L., Shen, Y., Wang, Y., Zhou, G., Zhang, X., Wang, M., ... & Zhang, J. (2019). Jugular arginine supplementation increases lactation performance and nitrogen utilization efficiency in lactating dairy cows. *Journal of animal science and biotechnology*, 10(1), 1-10. https://doi.org/10.1186/s40104-018-0311-8
- Disenhaus, C., Jammes, H., Hervieu, J., Ternois, F., & Sauvant, D. (1995). Effects of recombinant bovine somatotropin on goat milk yield, composition and plasma metabolites. *Small Ruminant Research*, 15(2), 139-148. doi:10.1016/0921-4488(94)00019-4
- Gow, C. B., Ranawana, S. S. E., Kellaway, R. C., & McDowell, G. H. (1979). Responses to post-ruminal infusions of casein and arginine, and to dietary protein supplements in lactating goats. *British Journal of Nutrition*, 41(2), 371-382.
- Hayashi, A. A., Nones, K., Roy, N. C., McNabb, W. C., Mackenzie, D. S., Pacheco, D., & McCoard, S. (2009). Initiation and elongation steps of mRNA translation are involved in the increase in milk protein yield caused by growth hormone administration during lactation. *Journal of Dairy Science*, 92(5), 1889-1899. doi: 10.3168/jds.2008-1334 PMID: 19389947.
- Hertelendy, F., Machlin, L., & Kipnis, D. M. (1969). Further studies on the regulation of insulin and growth hormone secretion in the sheep. *Endocrinology*, 84(2), 192-199.
- Hertelendy, F., Machlin, L. J., Takahashi, Y., & Kipnis, D. M. (1968). Insulin release from sheep pancreas in vitro. *Journal of Endocrinology*, 41(4), 605-606.



- Hertelendy, F., Takahashi, K., Machlin, L. J., & Kipnis, D. M. (1970). Growth hormone and insulin secretory responses to arginine in the sheep, pig, and cow. *General and comparative endocrinology*, 14(1), 72-77.
- Lassala, A., Bazer, F. W., Cudd, T. A., Li, P., Li, X., Satterfield, M. C., ... & Wu, G. (2009). Intravenous administration of L-citrulline to pregnant ewes is more effective than L-arginine for increasing arginine availability in the fetus. *The Journal of Nutrition*, 139(4), 660-665.
- McATEE, J. W., & TRENKLE, A. (1971). Effects of feeding, fasting, glucose or arginine on plasma prolactin levels in the bovine. *Endocrinology*, 89(3), 730-734.
- McAtee, J. W., and A. Trenkle. 1971. Metabolic regulation of plasma insulin levels in cattle. *J. Anim. Sci.* 33:438.
- Mephram, T. B. (1982). Amino acid utilization by lactating mammary gland. *Journal of dairy science*, 65(2), 287-298. doi.org/10.3168/jds.S0022-0302(82)82191-7
- Moncada, S., & Higgs, A. (1993). The L-arginine-nitric oxide pathway. *New England journal of medicine*, 329(27), 2002-2012.
- National Research council (2001). Nutritional Requirement of Dairy cows. Seventh Revised Edition. ISBN: 978-0-309-06997-7. doi.org/10.17226/9825.
- Oliveira, L. H., Nascimento, A. B., Monteiro Jr, P. L. J., Guardieiro, M. M., Wiltbank, M. C., & Sartori, R. (2016). Development of insulin resistance in dairy cows by 150 days of lactation does not alter oocyte quality in smaller follicles. *Journal of dairy science*, 99(11), 9174-9183. doi.org/10.3168/jds.2015-10547.
- Sallam, S. M. A., Nasser, M. E. A., & Yousef, M. I. (2005). Effect of recombinant bovine somatotropin on sheep milk production, composition and some hemato-biochemical components. *Small Ruminant Research*, 56(1-3), 165-171.
- Seifert, E. L., Estey, C., Xuan, J. Y., & Harper, M. E. (2010). Electron transport chain-dependent and-independent mechanisms of mitochondrial H<sub>2</sub>O<sub>2</sub> emission during long-chain fatty acid oxidation. *Journal of Biological Chemistry*, 285(8), 5748-5758. DOI 10.1074/jbc.M109.026203
- Squires, E. J. (2003). Endocrine manipulation of reproduction. In *Applied animal endocrinology* (pp. 154-191). Wallingford UK: CABI Publishing.
- Vicini, J. L., Clark, J. H., Hurley, W. L., & Bahr, J. M. (1988). Effects of abomasal or intravenous administration of arginine on milk production, milk composition, and concentrations of somatotropin and insulin in plasma of dairy cows. *Journal of dairy science*, 71(3), 658-665.
- Wang, M., Xu, B., Wang, H., Bu, D., Wang, J., & Loo, J. J. (2014). Effects of arginine concentration on the in vitro expression of casein and mTOR pathway related genes in mammary epithelial cells from dairy cattle. *PLoS One*, 9(5), e95985..
- Zheng, P., Song, Y., Tian, Y., Zhang, H., Yu, B., He, J., ... & Chen, D. (2018). Dietary arginine supplementation affects intestinal function by enhancing antioxidant capacity of a nitric oxide-independent pathway in low-birth-weight piglets. *The Journal of nutrition*, 148(11), 1751-1759. doi:https://doi.org/10.1093/jn/nxy198.
- Zheng, P., Yu, B., He, J., Tian, G., Luo, Y., Mao, X., ... & Chen, D. (2013). Protective effects of dietary arginine supplementation against oxidative stress in weaned piglets. *British journal of nutrition*, 109(12), 2253-2260.

Received: 27.10.2022

Accepted: 30.11.2022

## Evaluation of the estrus synchronization and reproductive performance of Farahani ewes during the breeding season following treatment with letrozole

Mohammad Yahyaei<sup>1\*</sup>, Mahdi Khodaei Motlagh<sup>2</sup> and Sobhan Akarim Alamdar<sup>3</sup>

<sup>1</sup> Assistant Professor, Department of Animal Science, Faculty of Agriculture and Environment, Arak University, Arak, Iran

<sup>2</sup> Professor, Department of Animal Science, Faculty of Agriculture and Environment, Arak University, Arak, Iran

<sup>3</sup> MSc Student of Animal Science, Faculty of Agriculture and Environment, Arak University, Arak, Iran

Received: 05.11.2022

Accepted: 18.12.2022

### Abstract

This study investigated the efficiency of substituting conventional gonadotropin-based technique with letrozole based regimen in reproductive parameters and hormonal changes in Farahani sheep during the breeding season. For this purpose, 40 Farahani ewes (3-4 years,  $44 \pm 2.3$  kg BW, BCS  $3.12 \pm 0.5$ ) were treated with intravaginal CIDR for 14 days and then were divided into four groups: one group was considered as the control, the other groups received eCG (400 IU, intramuscularly), hCG (400 IU, intramuscularly) and letrozole (7.5 mg, oral), respectively. Blood samples were taken from three days before CIDR removal. The reproductive parameters were calculated after parturition. Fecundity and multiple lambing were numerically higher in the eCG group; however, there was no significant difference in reproductive performance between treatments. Estrogen concentrations showed an increasing trend in all treatments. Results of this study showed that letrozole was not a reliable substitute for eCG to increase the ovulation rate in sheep.

**Key words:** Estrus synchronization, Farahani ewes, Letrozole, Reproductive performance

### Introduction

Control of the estrus cycle of small ruminants can be done by numerous treatments and protocols. Some of these protocols manipulate the luteal phase and others the follicular phase of the estrous cycle (Bister et al, 1999; MA, 2020). In ewes, the opportunity for estrus manipulation is greater during the luteal phase, due to its higher time period and more manipulative power (Evans, 2003).

The general strategy for estrus manipulation in ewes is the use of intravaginal devices impregnated with progesterone or synthetic progestagen such as Sponges, CIDR (Controlled Intravaginal Drug Release) (Nakafeero et al, 2020). Protocols based on the use of progesterone are associated with an injection of eCG, before (Ali, 2007), after (Moakhar et al, 2012) or at the time of CIDR withdrawal (Abecia et al, 2011;

\* **Corresponding Author:** Mohammad Yahyaei, Assistant Professor, Department of Animal Science, Faculty of Agriculture and Natural Sciences, Arak University, Arak, Iran  
E-mail: [m-yahyayi@araku.ac.ir](mailto:m-yahyayi@araku.ac.ir)



© 2020 by the authors. Licensee SCU, Ahvaz, Iran. This article is an open access article distributed under the terms and conditions of the Creative Commons Attribution-NonCommercial 4.0 International (CC BY-NC 4.0 license) (<http://creativecommons.org/licenses/by-nc/4.0/>).

Hameed et al, 2020). In these protocols eCG improves and increases the estrus response and litter size (Quintero-Elisea et al, 2011). However, the use of eCG can be associated with some constraints, including the occurrence of polycystic ovaries, increased probability of decreased eCG efficiency due to the formation of antibodies against it, and sometimes the high cost of eCG (Rahminiwati et al, 2017). Therefore, establishing alternatives compounds for eCG is necessary.

Several pharmacological agents including clomiphene citrate (CC) (Sudhakar et al, 2022), Letrozole (Requena et al, 2008) and gonadotropin releasing hormone (GnRH) (Titi et al, 2010) can induce or augment the ovulation, with varying degrees of success.

Based on Lacker's model, circulating estradiol secreted by the follicles provides systemic control over ovulation number (Shilo et al, 2022). In fact, reducing FSH concentrations to below the threshold needed to sustain the other gonadotrophin dependent follicles is one of the mechanism that determines the ovulation number (Scaramuzzi et al, 2011). Letrozole as aromatase inhibitor can reduce the negative feedback of estradiol concentration on gonadotropin production by inhibiting estrogen production (Mitwally & Casper, 2002). Letrozole is a reversible nonsteroidal inhibitor of the aromatase enzyme that regulating the synthesis of estrogen (Bhatnagar, 2007). It is used safely for treatment of estrogen induced diseases such as breast cancer (Cohen et al, 2002), induction of ovulation in women with anovulatory infertility (Gowri et al, 2022) and for ovarian superstimulation in women (Al-Fadhli et al, 2006). It is known Letrozole stimulates FSH surges and the emergence of a new follicular wave in humans (Mitwally & Casper, 2002). But in cattle, Yapura et al. (2012) showed that single and repeated (every 24 h for 3 days) administration of different formulations of letrozole did not affect FSH concentrations.

In Benoit et al, study (1992) administration of a nonsteroidal aromatase inhibitor, every 8 hr maintained decreased secretion of estradiol and altered profiles of gonadotropins. Kivrak et al, (2021) indicated that letrozole following single and repeated (every 24 h for 3 days) intravenous administrations caused an increase in the FSH concentration.

This study was conducted with the aim to evaluate the efficiency of substituting conventional gonadotropin-based protocol with letrozole on reproductive parameters and hormonal changes in Farahani ewes during breeding season.

## Materials and methods

### Animals and management

The experiment was implemented at the Small Ruminant Research Center (SRRC) of Arak University, Arak, Iran from November 2019 to April 2020. A total of 40 non-lactating Iranian Farahani ewes (3-4 years,  $44 \pm 2.3$  kg BW) with normal estrous cycles were used. The ewes were housed in individual pens with free access to feed (consisting of 10.2% CP, 2.3 Mcal/kg DM, 7g/day Ca and 4g/day P) and water.

### Experimental design

The estrous cycle was synchronized using CIDR (Controlled Internal Drug Release, EAZI-BREEDTM, CIDR®, New Zealand) for a 14-day period during the breeding season, and the ewes were randomly divided into 4 groups (n=10 per group). One group of ewes served as the control; the first group received 400IU PMSG 48 h prior to CIDR removal (eCG protocol); the second group received 400IU hCG 48 h prior to CIDR removal (hCG protocol) and the third group was orally administered with letrozole (Parsian Pharmaceuticals Co, Tehran, Iran) for 3 consecutive days (2.5 mg per day) prior to CIDR removal (Ortiz-Carrera et al, 2019). An ewe was considered in estrus only when she allowed a ram to mount and this was registered as the onset time of estrus. Six

fertile rams with colored bibs were used for daily mating (in the morning and afternoon) for 4 days, starting at 24 h after CIDR removal (Habibzad et al, 2015). The reproductive variables measured were estrus response (%): Percentage of ewes in estrus after sponge withdrawal, pregnancy rate (%): percentage of pregnant ewes to all synchronizaed ewes, lambing rate (%): percentage of ewes lambd from pregnant ewes previously diagnosed, fertility (%): percentage of ewes lambd from the total of ewes mated, multiple lambing (%): percentage of ewes lambd with two or more lambs, fecundity (%): percentage of lamb born per ewe mated.

#### Blood sampling and hormone determination

To measure changes in estradiol concentration, blood samples were collected from three randomly-selected ewes per group by jugular venipuncture at 9:00 a.m. and the sampling was repeated daily during day -3 to -1 before CIDR removal.

Blood serum was then separated by centrifugation (2500 rpm for 15 min) and stored at -20°C. Estradiol concentration was determined by ELISA Reader (ELx 808-Ultramicroplate ReaderBio-Tek Instruments INC. U.S.A) using commercial kits (Hangzhou Eastbiopharm CO., LTD. Cat. No: CK-E91162, Hangzhou, China). The intra-assay and inter-assay coefficients

of variation were <10% and <12% for estradiol.

#### Statistical analyses

The experiment was performed in a completely randomized design. The data were analyzed by Proc GLM (SAS, 2003). The statistical model included the fixed effect of treatment and the random effect of ewe. Data on reproductive performance were analyzed using PROC GENMOD. For the analysis of estradiol concentration, a mixed model for repeated measurements was used. Results were expressed as mean  $\pm$  SEM, and a probability of  $P \leq 0.05$  was considered as significant.

#### Results

##### Reproductive performance

The data for reproductive performance are presented in Table 1. There were no significant differences in any of the reproductive performance parameters between control and other groups. This indicated that estrous synchronization using the progestin CIDR could be effective in Farahani ewes during the breeding season. The fecundity (40% vs. 0) and multiple lambing (150% vs. 0) were numerically greater for ewes treated with eCG compared to other treatments which showed that the inclusion of eCG into estrous synchronization program can improve reproductive performance.

**Table 1. Reproductive performance of Farahani ewes following estrus synchronization by different protocols**

	Estrus response (%)	Pregnancy rate(%)	Lambing rate (%)	Fertility (%)	Multiple lambing (%)	Fecundity (%)
Control	10/10(100)	10/10(100)	10/10(100)	10/10(100)	0/10(0)	10/10(100)
Letrozole	10/10(100)	10/10(100)	10/10(100)	10/10(100)	0/10(0)	10/10(100)
hCG	10/10(100)	10/10(100)	10/10(100)	10/10(100)	0/10(0)	10/10(100)
eCG	10/10(100)	10/10(100)	10/10(100)	10/10(100)	4/10(40)	15/10(150)

#### Blood parameters

The results of serum estradiol concentration are presented in Figure 2. All groups had basal serum estradiol concentrations during the days before sponge removal. In all groups, the estradiol concentration showed an increasing trend

over time. No significant difference was observed in estradiol concentrations between groups ( $P > 0.05$ ). However, there were numerical differences between groups.

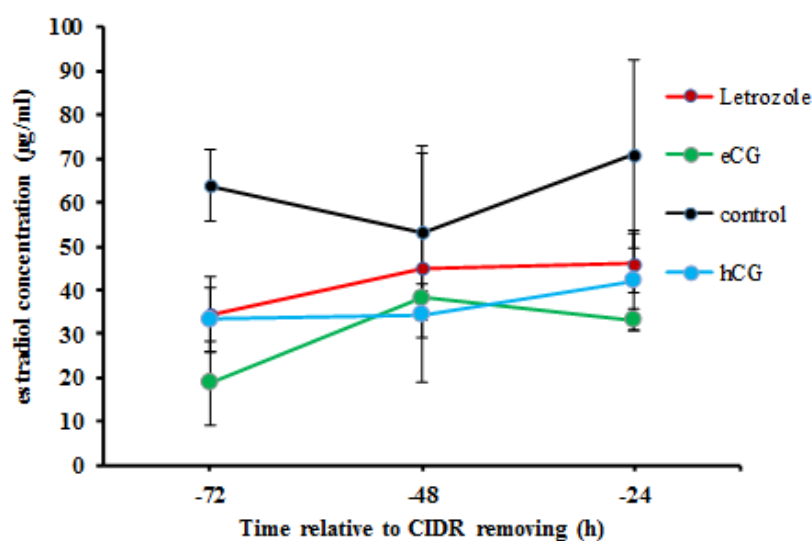


Figure 1. Comparison of serum estradiol concentration between the letrozole, eCG, control and hCG groups ( $P>0.05$ )

## Discussion

Theoretically, there are two practical ways for increasing the number of ovulatory follicles: the supplementation of endogenous gonadotrophins with exogenous products, such as eCG, around the time of mating or reducing the feedback effects of estradiol hormones on gonadotrophins (Land, 1979; Scaramuzzi et al, 2011). This study was designed to test the hypothesis that letrozole treatment, prior to CIDR removal, will reduce the feedback effects of estradiol on gonadotrophins and will improve the reproductive performance in Farahani ewe. Based on the results, orally letrozole treatment did not increase fecundity and multiple lambing compared to eCG treatment. Therefore, using letrozole with our proposed regimen was not a suitable alternative for eCG in order to estrus synchronization in farahani ewe. Abdel Dayem *et al.* (2020) showed that letrozole treatment (using an intravaginal sponge containing 7.5 mg letrozole for five days) did not significantly affect the number of small, medium and large sized follicles in Farafr ewes. Benoit *et al.* (1992) indicated that fadrozole (as a nonsteroidal aromatase inhibitor) treatment (intravenous) had a decreasing and increasing effects on estradiol and FSH respectively in ewes

during the breeding season. In another study, Kivrak *et al.* (2021) showed that letrozole following single and repeated (every 24 h for 3 days) intravenous administrations at 1mg/kg dose caused an increase in the FSH concentration in anestrus Akaraman ewes. The observed differences between the results of this study and others could be attributed to the stage of breeding season, the stage of the follicle wave, letrozole dosage, letrozole administration route and treatment regimen. In most studies, letrozole was administered through intramuscular, intravenous or intravaginal form (Benoit et al, 1992; Kivrak et al, 2021; MA, 2020; Yapura et al, 2018). While in our study, letrozole was used orally. Based on the reports, species differences are also a vital factor that can affect letrozole activity. Akbarinejad et al. (2016) showed that unlike bovine and human, in equine the oral administration of letrozole during the preovulatory period did not affect corpus lutea diameter and progesterone concentration. Yapura et al. (2012), in their study on cattle, indicated that a single treatment or 3-day regimen of letrozole was increased circulating LH while FSH remained unchanged.

There is a positive correlation between serum estradiol levels and the growth of follicles during the estrous cycle (Rahminiwati et al, 2017). In our study, in all treatments, estrogen concentration was significantly increased during the time which reflects the continuous growth of follicles. Based on the results (Figure 1), letrozol did not have a significant effect on reducing estrogen concentration during the treatment time. Insufficient circulating levels of letrozole during the treatment period can be one of the possible reasons for this result. In a study conducted by Abdel Dayem et al. (2020) treatment with letrozole using intravaginal device containing containing 7.5 mg letrozole decreased the serum concentrations of estradiol in ewes. Benoit et al. (1992) showed that fadrozole reduced the E<sub>2</sub>

concentration after 8e10 h following the treatment. However, in studies conducted by yapura et al. (2016) and Garcia-Velasco et al. (2005) on cattle and women respectively, letrozole did not reduce estradiol concentrations. In another study, it was stated that letrozole is less effective in the presence of high estradiol concentrations even if aromatase enzyme is reduced (Cortínez et al, 2005).

Based on the results of this study, using letrozole with our proposed regimen, was not effective in increasing the ovulation rate in Farahani sheep in comparison with the traditional eCG regimens. However, due to the small sample size in this study, further studies with larger sample sizes are needed to evaluate the real potential of letrozole for increasing the ovulation rate in sheep.

### Acknowledgments

Thanks are hereby given to the Research Vice-Chancellor of Arak University for funding the costs of this research.

### Conflict of interest

The authors of the article have no conflict of interest.

### Funding

Part of the financial resources for this research were provided by Arak University in the form of a student thesis project.

### References

- Abecia, J. A., Forcada, F., & González-Bulnes, A. (2011). Pharmaceutical control of reproduction in sheep and goats. *Veterinary Clinics: Food Animal Practice*, 27(1), 67-79.
- Al-Fadhli, R., Sylvestre, C., Buckett, W., Tan, S. L., & Tulandi, T. (2006). A randomized trial of superovulation with two different doses of letrozole. *Fertility and sterility*, 85(1), 161-164.
- Ali, A. (2007). Effect of time of eCG administration on follicular response and reproductive performance of FGA-treated Ossimi ewes. *Small Ruminant Research*, 72(1), 33-37.
- Benoit, A., Inskip, E., & Dailey, R. (1992). Effect of a nonsteroidal aromatase inhibitor on in vitro and in vivo secretion of estradiol and on the estrous cycle in ewes. *Domestic Animal Endocrinology*, 9(4), 313-327.
- Bhatnagar, A. S. (2007). The discovery and mechanism of action of letrozole. *Breast cancer research and treatment*, 105(1), 7-17.
- Bister, J.-L., Noel, B., Perrad, B., Mandiki, S., Mbayahaga, J., & Paquay, R. (1999). Control of ovarian follicles activity in the ewe. *Domestic Animal Endocrinology*, 17(2-3), 315-328.
- Cohen, M. H., Johnson, J. R., Li, N., Chen, G., & Pazdur, R. (2002). Approval summary: letrozole in the treatment of postmenopausal women with advanced breast cancer. *Clinical Cancer Research*, 8(3), 665-669.
- Cortínez, A., De Carvalho, I., Vantman, D., Gabler, F., Iñiguez, G., & Vega, M. (2005). Hormonal profile and endometrial morphology in letrozole-controlled ovarian hyperstimulation in ovulatory infertile patients. *Fertility and sterility*, 83(1), 110-115.

- Evans, A. (2003). Ovarian follicle growth and consequences for fertility in sheep. *Animal reproduction science*, 78(3-4), 289-306.
- Gowri, V., Al-Amri, A., Almamari, T. M. A., Al Khaduri, M., & Jaju, S. (2022). The Success of Ovulation Induction with Letrozole and Gonadotropins in Obese and Nonobese Women: A Study from a Tertiary Center. *International Journal of Reproductive Medicine*, 2022.
- Habibizad, J., Riasi, A., Kohram, H., & Rahmani, H. R. (2015). Effect of feeding greater amounts of dietary energy for a short-term with or without eCG injection on reproductive performance, serum metabolites and hormones in ewes. *Animal reproduction science*, 160, 82-89.
- Hameed, N., Khan, M. I.-u.-R., Ahmad, W., Abbas, M., Murtaza, A., Shahzad, M., & Ahmad, N. (2020). Follicular dynamics, estrous response and pregnancy rate following GnRH and progesterone priming with or without eCG during non-breeding season in anestrus Beetal goats. *Small Ruminant Research*, 182, 73-77.
- Kivrak, M. B., Corum, O., Alkan, H., Atik, O., Aydin, I., & Uney, K. (2021). The pharmacokinetics of letrozole and its effect on gonadotropins in anestrus ewes. *Theriogenology*, 176, 225-232.
- Land, R. (1979). *Improvement in gonadal function through modification of negative feed-back*. Paper presented at the Annales de Biologie Animale Biochimie Biophysique.
- MA, A. D. (2020). Effect of A Non-Steroidal Aromatase Inhibitor on Ovarian Function and Synchronicity of Estrus in Ewes at Subtropics. *Journal of Applied Veterinary Sciences*, 5(4), 1-9.
- Mitwally, M. F., & Casper, R. F. (2002). Aromatase inhibition for ovarian stimulation: future avenues for infertility management. *Current Opinion in Obstetrics and Gynecology*, 14(3), 255-263.
- Moakhar, H. K., Kohram, H., Shahneh, A. Z., & Saberifar, T. (2012). Ovarian response and pregnancy rate following different doses of eCG treatment in Chall ewes. *Small Ruminant Research*, 102(1), 63-67.
- Nakafeero, A., Hassen, A., & Lehloeny, K. (2020). Investigation of ram effect and eCG usage in progesterone based oestrous synchronization protocols on fertility of ewes following fixed time artificial insemination. *Small Ruminant Research*, 183, 106034.
- Ortiz-Carrera, L., Aceves-Ramos, A., Zarco, L., Valencia, J., & Romano, M. (2019). The effect of letrozole administration on the aggressive behavior and reproductive parameters of male goats (*Capra hircus*). *Small Ruminant Research*, 174, 69-76.
- Quintero-Elisea, J. A., Macías-Cruz, U., Álvarez-Valenzuela, F. D., Correa-Calderón, A., González-Reyna, A., Lucero-Magaña, F. A., . . . Avendaño-Reyes, L. (2011). The effects of time and dose of pregnant mare serum gonadotropin (PMSG) on reproductive efficiency in hair sheep ewes. *Tropical Animal Health and Production*, 43(8), 1567-1573.
- Rahminiwati, M., Boediono, A., & Manalu, W. (2017). Optimum dose and time of pregnant mare serum gonadotropin injections in Kacang goats to increase endogenous secretion of estrogen and progesterone without superovulation response. *Small Ruminant Research*, 149, 147-153.
- Requena, A., Herrero, J., Landeras, J., Navarro, E., Neyro, J. L., Salvador, C., . . . Farré, M. (2008). Use of letrozole in assisted reproduction: a systematic review and meta-analysis. *Human reproduction update*, 14(6), 571-582.
- Scaramuzzi, R., Baird, D., Campbell, B., Driancourt, M.-A., Dupont, J., Fortune, J., . . . McNeilly, A. (2011). Regulation of folliculogenesis and the determination of ovulation rate in ruminants. *Reproduction, Fertility and Development*, 23(3), 444-467.
- Shilo, M., Mayo, A., & Alon, U. (2022). A Mechanism for Ovulation Number Control. *Frontiers in Endocrinology*, 13.
- Sudhakar, B., Bhavya, Y., & Harika, J. (2022). Aromatase inhibitors: Their application in commercial broiler chick production.
- Titi, H., Kridli, R., & Alnimer, M. (2010). Estrus synchronization in sheep and goats using combinations of GnRH, progestagen and prostaglandin F2α. *Reproduction in domestic animals*, 45(4), 594-599.
- Yapura, M., Zwiefelhofer, E., Pierson, R., & Adams, G. (2018). Aromatase inhibitors: A new approach for controlling ovarian function in cattle. *Theriogenology*, 112, 18-25.
- Yapura, M. J., Maplettoft, R. J., Singh, J., Pierson, R., Naile, J., Giesy, J. P., . . . Adams, G. P. (2012). Effects of a non-steroidal aromatase inhibitor on ovarian function in cattle. *Reproduction, Fertility and Development*, 24(4), 631-640.

Received: 05.11.2022

Accepted: 18.12.2022



## بررسی یافته‌های اپیدمیولوژیک و بالینی پرکاری قشر غده فوق کلیه سگ در ایران

محمد اسدی ایرایی<sup>۱</sup>، رضا آویزه<sup>۲\*</sup>، محمد راضی جلالی<sup>۲</sup> و مهدی پورمهدی بروجنی<sup>۳</sup>

<sup>۱</sup> دانشجوی دکتری تخصصی بیماری‌های داخلی دام‌های کوچک، دانشکده دامپزشکی، دانشگاه شهید چمران اهواز، اهواز، ایران

<sup>۲</sup> استاد گروه علوم درمانگاهی، دانشکده دامپزشکی، دانشگاه شهید چمران اهواز، اهواز، ایران

<sup>۳</sup> استاد گروه بهداشت مواد غذایی، دانشکده دامپزشکی، دانشگاه شهید چمران اهواز، اهواز، ایران

تاریخ دریافت: ۱۴۰۱/۶/۱۴

تاریخ پذیرش: ۱۴۰۱/۸/۱۲

### چکیده

هیپرآدرنوکورتیزیسیم که به عنوان سندرم کوشینگ نیز شناخته می‌شود، در اثر مواجهه مزمن با گلوکوکورتیکوئیدها ایجاد می‌شود. هدف از این مطالعه، بررسی یافته‌های اپیدمیولوژیک و بالینی (به ویژه چشمی) سگ‌های مبتلا به هیپرآدرنوکورتیزیسیم، به منظور بهبود روند تشخیص موارد مشکوک به این بیماری، در موارد بالینی است. در این مطالعه ۳۰ قلاده سگ از استان‌های تهران، مازندران و گیلان در فاصله زمانی فروردین ۱۴۰۰ تا اردیبهشت ۱۴۰۱ مورد بررسی قرار گرفتند. سگ‌های مطالعه حاضر همگی مبتلا به پرکاری قشر غده فوق کلیه بودند و بر اساس یافته‌های بالینی حاکی از بیماری کوشینگ و همچنین مثبت بودن تست سرکوب دکزامتازون با دوز پایین انتخاب شدند. سپس اطلاعات کلی، علائم بالینی و فاکتورهای چشمی بررسی و ثبت گردید. داده‌ها با استفاده از آزمون‌های مربع کای، آزمون دقیق فیشر، آزمون مک نمار، آزمون تی مستقل، آنالیز واریانس یک طرفه و آزمون تعقیبی LSD مورد تجزیه و تحلیل قرار گرفت. میانگین سنی سگ‌های دارای هیپرآدرنوکورتیزیسیم، ۹/۷ سال بود. فراوانی هیپرآدرنوکورتیزیسیم نیز در سگ‌های عقیم شده بیشتر از سگ‌های سالم و همچنین در نژاد تریر بیشتر از سایر نژادها بود. علاوه بر این، تفاوت‌های آماری معنی‌داری در ارزیابی‌های چشم از جمله ضایعات چشمی، رفلکس پلکی، اختلالات ساختاری چشم، ملتحمه، صلبیه، عدسی، شبکیه، عنبیه و درگیری عصب بینایی مشاهده شد. با این حال، جنسیت، نژاد، تظاهرات بالینی، وضعیت رفتاری، تست پاسخ مردمک به نور، تست تهدید، تست خیره شدن، تست پنبه و درگیری قرنیه، تفاوت‌های آماری معنی‌داری را نشان ندادند و سگ‌های داخل خانه و عقیم شده، فراوانی بیشتری در جمعیت مورد مطالعه داشتند. این مطالعه اولین بررسی اپیدمیولوژیک و بالینی سندرم کوشینگ در کنار سنجش نشانگان چشمی مرتبط با این سندرم در ایران است که نتایج این مطالعه منجر به درک بهتر بیماری پرکاری قشر غده فوق کلیه سگ در ایران می‌شود. طبق این مطالعه، مشخصات بالینی جمعیت مورد مطالعه مانند مشخصات توصیف شده در مطالعات اپیدمیولوژیک اروپا و آمریکای شمالی است.

**کلمات کلیدی:** پلی‌اوری، پلی‌دیپسی، هیپرآدرنوکورتیزیسیم، سگ، چشم

\* نویسنده مسئول: رضا آویزه، استاد گروه علوم درمانگاهی، دانشکده دامپزشکی، دانشگاه شهید چمران اهواز، اهواز، ایران

E-mail: avizeh@scu.ac.ir



© 2020 by the authors. Licensee SCU, Ahvaz, Iran. This article is an open access article distributed under the terms and conditions of the Creative Commons Attribution-NonCommercial 4.0 International (CC BY-NC 4.0 license) (<http://creativecommons.org/licenses/by-nc/4.0/>).

## ارتباط بین حضور DNA و آنتی‌بادی سرم در طول انتقال عمودی نئوسپورا کنیوم

راضیه آیتی<sup>۱</sup>، حسین رضوان<sup>۲\*</sup>، مهدی نام‌آوری<sup>۳</sup>، علی صادقی‌نسب<sup>۴</sup>، سحر هامون‌نورد<sup>۵</sup> و بهرام دادمهر<sup>۶</sup><sup>۱</sup> کارشناسی ارشد، گروه پاتوبیولوژی، دانشکده پیرادامپزشکی، دانشگاه بوعلی سینا، همدان، ایران<sup>۲</sup> دانشیار، گروه پاتوبیولوژی، دانشکده پیرادامپزشکی، دانشگاه بوعلی سینا، همدان، ایران<sup>۳</sup> دانشیار، موسسه تحقیقات واکسن و سرم‌سازی رازی، شیراز، ایران<sup>۴</sup> استادیار، گروه علوم درمانگاهی، دانشکده پیرادامپزشکی، دانشگاه بوعلی سینا، همدان، ایران<sup>۵</sup> استادیار، گروه پاتوبیولوژی، دانشکده پیرادامپزشکی، دانشگاه بوعلی سینا، همدان، ایران<sup>۶</sup> مربی، گروه علوم پایه، مرکز آموزش علمی کاربردی فراب عمارلو، جیرنده، ایران

تاریخ پذیرش: ۱۴۰۱/۹/۲۳

تاریخ دریافت: ۱۴۰۱/۵/۱۱

## چکیده

نئوسپورا کنیوم یک انگل درون سلولی است که باعث سقط جنین و نارسایی تولید مثل در گاو می‌شود. هدف از مطالعه حاضر، ارتباط بین عفونت انگلی و مثبت شدن سرم در گاوهای بدون علامت سقط و گوساله‌های آن‌ها، بود. جهت این بررسی، ۴۹ نمونه سرم از گاوهای شیری با ظاهر سالم و گوساله‌های تازه متولد شده قبل از دریافت آغوز توسط PCR، Nested-PCR و یک روش الایزا مبتنی بر سلول کامل آزمایش شد. ۱۴ مورد از ۴۹ مادر (۲۸/۵۷ درصد) و ۶ مورد از ۴۹ گوساله (۱۲/۲۴ درصد) آنتی‌بادی ضد نئوسپورا و DNA نئوسپورا را در سرم نشان دادند. بر اساس آنالیزهای مختلف سرمی، همه گوساله‌های آلوده از مادران آلوده به دنیا آمدند و میزان انتقال عمودی در بین همه نمونه‌ها ۶ مورد از ۴۹ مورد (۱۲/۲۴ درصد) و از مادران آلوده ۶ مورد از ۱۴ مورد (۴۲/۸۴ درصد) بود، بر اساس آنالیزهای مختلف سرمی، هشت گوساله از ۱۴ گوساله (۵۷/۱۴ درصد) متولد شده از مادران آلوده عاری از نئوسپورا بودند. در پایان، علی‌رغم وجود آنتی‌بادی‌های ضد نئوسپورا سرم در گاوها و گوساله‌های آلوده، انگل به طور کامل از خون خارج نشد و به نظر می‌رسد وجود آنتی‌بادی لزوماً نشانه‌ای از ایمنی موثر نیست.

کلمات کلیدی: نئوسپورا کنیوم، آنتی‌بادی، DNA

\* نویسنده مسئول: حسین رضوان، دانشیار، گروه پاتوبیولوژی، دانشکده پیرادامپزشکی، دانشگاه بوعلی سینا، همدان، ایران

E-mail: h.rezvan@basu.ac.ir



© 2020 by the authors. Licensee SCU, Ahvaz, Iran. This article is an open access article distributed under the terms and conditions of the Creative Commons Attribution-NonCommercial 4.0 International (CC BY-NC 4.0 license) (<http://creativecommons.org/licenses/by-nc/4.0/>).

## بررسی ساختار بافت‌شناسی معده در پرندگان شکاری دلیجه (*Falco tinnunculus*)، عقاب صحرایی (*Aquila nipalensis*)، عقاب طلایی (*Aquila chrysaetos*) و عقاب شاهی (*Aquila heliaca*)

علی کلانتری‌حصاری<sup>۱\*</sup>، محمد بابائی<sup>۲</sup>، کاوه اسفندیاری<sup>۳</sup> و حسن مروتی<sup>۳</sup>

<sup>۱</sup> استادیار گروه پاتوبیولوژی، دانشکده پیرادامپزشکی، دانشگاه بوعلی سینا، همدان، ایران

<sup>۲</sup> استادیار گروه علوم درمانگاهی، دانشکده پیرادامپزشکی، دانشگاه بوعلی سینا، همدان، ایران

<sup>۳</sup> دانش‌آموخته دکترای تخصصی بافت‌شناسی، دانشکده دامپزشکی، دانشگاه تهران، تهران، ایران

<sup>۳</sup> استاد گروه علوم پایه، دانشکده دامپزشکی، دانشگاه تهران، تهران، ایران

تاریخ دریافت: ۱۴۰۱/۸/۲۶

تاریخ پذیرش: ۱۴۰۱/۹/۲۸

### چکیده

معه عضلانی یا سنگدان یکی از مهمترین قسمت‌های دستگاه گوارش پرندگان است که نقش مکانیکی و شیمیایی در گوارش داشته و ساختار آن به عادات غذایی پرند بستگی دارد. در مطالعه حاضر، ریخت‌شناسی معده عضلانی در دلیجه، عقاب صحرایی، عقاب طلایی و عقاب امپراتور مورد مطالعه و بررسی قرار گرفت. در این مطالعه تعداد ۴ عدد دلیجه، ۵ عدد عقاب صحرایی، ۴ عدد عقاب طلایی و ۶ عدد عقاب امپراتور که به دلیل شکستگی پا یا بال تلف شده و به دانشکده پیرادامپزشکی بوعلی سینا همدان ارسال شده بودند مورد استفاده قرار گرفتند. نمونه‌های سنگدان در داخل محلول فرمالین ۱۰ درصد بافری تثبیت و وارد مراحل تهیه مقطع شدند. نهایتاً از روش‌های رنگ‌آمیزی هماتوکسیلین-انوزین، تری کروماتون و اورسئین برای رنگ‌آمیزی لام‌ها استفاده شد. تفاوت عمده در ساختار سنگدان عقاب‌های صحرایی، طلایی و امپراتور و دلیجه، نبود لایه شاخی در قسمت سطحی سنگدان عقاب‌ها بود. ساختار بافت‌شناسی سنگدان در عقاب امپراتور بسیار شبیه به عقاب صحرایی بود. تفاوت قابل بیان سنگدان عقاب امپراتور وجود لایه عضلانی در چندین لایه با جهت‌گیری مختلف در مقایسه با عقاب‌های صحرایی و طلایی بود. می‌توان نتیجه گرفت که ساختار معده عضلانی در دلیجه مشابه ساختار سنگدان پرندگان دیگر است، در حالی که معده عضلانی سه گونه دیگر مورد مطالعه فاقد لایه شاخی سطحی بودند.

**کلمات کلیدی:** بافت‌شناسی، پرندگان شکاری، دلیجه، عقاب‌ها، معده عضلانی

\* نویسنده مسئول: علی کلانتری‌حصاری، استادیار گروه پاتوبیولوژی، دانشکده پیرادامپزشکی، دانشگاه بوعلی سینا، همدان، ایران

E-mail: a.kalantarihesari@basu.ac.ir



© 2020 by the authors. Licensee SCU, Ahvaz, Iran. This article is an open access article distributed under the terms and conditions of the Creative Commons Attribution-NonCommercial 4.0 International (CC BY-NC 4.0 license) (<http://creativecommons.org/licenses/by-nc/4.0/>).

## تأثیر افزودن عصاره پوست بادمجان (*Solanum melongena*) بر اسپرم قوچ فراهانی پس از تنش اکسیداتیو (انجماد- ذوب)

حمیدرضا خدادادی<sup>۱</sup>، مهدی خدایی مطلق<sup>۲\*</sup>، مهدی کاظمی بنچناری<sup>۲</sup> و حمیدرضا مومنی<sup>۳</sup>

<sup>۱</sup> دانشجوی کارشناسی ارشد فیزیولوژی دام، دانشکده کشاورزی و منابع طبیعی، دانشگاه اراک، اراک، ایران

<sup>۲</sup> استاد گروه علوم دامی، دانشکده کشاورزی و منابع طبیعی، دانشگاه اراک، اراک، ایران

<sup>۳</sup> استاد گروه زیست شناسی، دانشکده علوم پایه، دانشگاه اراک، اراک، ایران

تاریخ دریافت: ۱۴۰۱/۹/۲۵

تاریخ پذیرش: ۱۴۰۱/۱۱/۱۹

### چکیده

هدف از این مطالعه بررسی اثر عصاره پوست بادمجان بر کیفیت اسپرم قوچ پس از ذوب در رقیق‌کننده بر پایه تریس بود. مایع منی توسط واژن مصنوعی جمع‌آوری شد. نمونه‌ها برای جلوگیری از اثرات فردی باهم مخلوط شدند. سپس نمونه‌های مایع منی قوچ با بر پایه تریس رقیق شد و با عصاره پوست بادمجان ۰، ۲، ۴، ۶ و ۸ درصد تکمیل شد. سپس نمونه‌ها توسط نیتروژن مایع در پایوت (۰/۲۵ میلی‌لیتر) منجمد شدند. پس از ذوب، تحرک اسپرم، زنده ماندن (رنگ‌آمیزی نیگروزین-اُئوزین)، یکپارچگی غشاء با محلول هیپواسموتیک (Host) و ناهنجاری مورفولوژی (تست هانکوک) مورد بررسی قرار گرفت. نتایج نشان داد که مقدار ۲ درصد (۶۲/۴) پوست عصاره بادمجان تأثیر معنی‌داری بر تحرک اسپرم و یکپارچگی غشاء پس از ذوب داشت. همچنین گروه‌های ۲ و ۴ درصد عصاره پوست بادمجان دارای بیشترین تحرک نسبت به گروه کنترل و کمترین تحرک در غلظت ۸ درصد عصاره پوست بادمجان در مقایسه با گروه شاهد بود. بنابراین، افزودن ۲ و ۴ درصد عصاره پوست بادمجان به رقیق‌کننده بر پایه تریس سبب حفظ اسپرم قوچ فراهانی پس از ذوب شد.

**کلمات کلیدی:** پوست بادمجان، عصاره، مایع منی

\* نویسنده مسئول: مهدی خدایی مطلق، استاد گروه علوم دامی، دانشکده کشاورزی و منابع طبیعی، دانشگاه اراک، اراک، ایران

E-mail: mmotlagh2002@gmail.com



© 2020 by the authors. Licensee SCU, Ahvaz, Iran. This article is an open access article distributed under the terms and conditions of the Creative Commons Attribution-NonCommercial 4.0 International (CC BY-NC 4.0 license) (<http://creativecommons.org/licenses/by-nc/4.0/>).

# شناسایی سلول‌های زایای اولیه در گندهای نر رویان‌های قرقاول (*Phasianus colchicus*) با استفاده از تکنیک‌های هیستوشیمیایی و رنگ‌آمیزی ایمنی

فرهاد محمدی‌قشلاق<sup>۱</sup>، اعظم حسینی<sup>۲</sup> و ابوالقاسم نبی‌پور<sup>۳\*</sup>

<sup>۱</sup> دانشجوی دکتری بافت شناسی، دانشکده دامپزشکی، دانشگاه فردوسی مشهد، مشهد، ایران

<sup>۲</sup> دانش آموخته دکتری بافت شناسی، دانشکده دامپزشکی، دانشگاه فردوسی مشهد، مشهد، ایران

<sup>۳</sup> استاد، گروه علوم پایه، دانشکده دامپزشکی، دانشگاه فردوسی مشهد، مشهد، ایران

تاریخ پذیرش: ۱۴۰۱/۹/۱

تاریخ دریافت: ۱۴۰۱/۶/۱۴

## چکیده

هدف از این تحقیق شناسایی سلول‌های زایای اولیه در گندهای نر در مراحل مختلف رویانی قرقاول بود. سلول‌های زایای اولیه سلول‌هایی هستند که به اسپرم یا اووسیت تمایز می‌یابند که برای انتقال اطلاعات ژنتیکی بین نسل‌ها مهم هستند. در این مطالعه، رویان‌ها در روزهای ۲۴-۸ جنینی استخراج شدند. سلول‌های زایای اولیه در مقاطع بافتی پارافینی و رزینی در روزهای ۸ تا ۱۰ تکوین رویانی به دلیل داشتن ویژگی‌های خاص این سلول‌ها شناسایی شدند شامل: اندازه بزرگ سلولی، داشتن هسته و هستک بزرگ و سیتوپلاسم اندک. سلول‌های زایای اولیه بیضه با استفاده از تکنیک‌های هیستوشیمیایی و رنگ‌آمیزی ایمنی شناسایی شدند. روش پریودیک اسید-شیف (PAS)، ایمونوهیستوشیمی با استفاده از آنتی‌ژن جنینی اختصاصی مرحله ۱ (SSEA-1)، رنگ‌آمیزی آلکالین فسفاتاز و رنگ‌آمیزی تولوئیدین بلو برای شناسایی سلول‌های زایای اولیه استفاده شدند. سلول‌های زایا در سنین بالاتر (۲۴-۱۰ روزگی) تنها از طریق برش‌های نیمه نازک قابل شناسایی بودند. علاوه بر این، واکنش این سلول‌ها در تمام سنین به رنگ‌آمیزی‌های آلکالین فسفاتاز، پریودیک اسید-شیف و آنتی‌ژن اختصاصی ۱-جنینی منفی بود. یافته‌های این مطالعه نشان داد که سلول‌های زایای اولیه در بافت بیضه رویان قرقاول در تمام سنین مورد مطالعه به تکنیک‌های هیستوشیمیایی و ایمونوهیستوشیمی واکنش منفی نشان دادند. همچنین این مطالعه نشان داد رنگ‌آمیزی معمول هماتوکسیلین و اتوزین و استفاده از مقاطع نیمه نازک برای تشخیص بافت‌شناسی این سلول‌ها مناسب هستند.

**کلمات کلیدی:** سلول‌های زایای اولیه، ایمونوهیستوشیمی، فسفاتاز قلیائی، قرقاول، گناد نر

\* نویسنده مسئول: ابوالقاسم نبی‌پور، استاد، گروه علوم پایه، دانشکده دامپزشکی، دانشگاه فردوسی مشهد، مشهد، ایران

E-mail: napipour@um.ac.ir



© 2020 by the authors. Licensee SCU, Ahvaz, Iran. This article is an open access article distributed under the terms and conditions of the Creative Commons Attribution-NonCommercial 4.0 International (CC BY-NC 4.0 license) (<http://creativecommons.org/licenses/by-nc/4.0/>).

# اثر تغذیه میوه ویتکس بر بیان نشانگرهای هیپوتالاموس-هیپوفیز-تخمدان و سیستم ایمنی مرغ تخم‌گذار: اتصال فیتواستروژن‌های میوه ویتکس به گیرنده استروژن بتا

محمود نظری<sup>۱\*</sup>، محمدرضا قربانی<sup>۲</sup>، محمدتقی بیگی‌نصیری<sup>۳</sup>، ندا فتحی‌مقدم<sup>۴</sup>، راضیه صباحی<sup>۵</sup>  
و سیده تقوا موسوی<sup>۵</sup>

<sup>۱</sup> دانشیار گروه علوم دامی، دانشکده علوم دامی و صنایع غذایی، دانشگاه علوم کشاورزی و منابع طبیعی خوزستان، خوزستان، ملاتانی، ایران

<sup>۲</sup> دانشیار گروه علوم دامی، دانشکده کشاورزی شیروان، دانشگاه بجنورد، بجنورد، ایران

<sup>۳</sup> استاد گروه علوم دامی، دانشکده علوم دامی و صنایع غذایی، دانشگاه علوم کشاورزی و منابع طبیعی خوزستان، خوزستان، ملاتانی، ایران

<sup>۴</sup> دانش‌آموخته تغذیه دام، دانشکده علوم دامی و صنایع غذایی، دانشگاه علوم کشاورزی و منابع طبیعی خوزستان، خوزستان، ملاتانی، ایران

<sup>۵</sup> دانش‌آموخته ژنتیک و اصلاح دام، دانشکده علوم دامی و صنایع غذایی، دانشگاه علوم کشاورزی و منابع طبیعی خوزستان، خوزستان، ملاتانی، ایران

تاریخ پذیرش: ۱۴۰۱/۱۱/۱۰

تاریخ دریافت: ۱۴۰۱/۵/۱۱

## چکیده

مصرف استروژن در زنان می‌تواند خطر ابتلا به سرطان سینه را افزایش دهد. استروژن رشد سلول‌های سرطانی را از طریق گیرنده استروژن آلفا تحریک می‌کند. یکی از استراتژی‌هایی که اخیراً مورد توجه قرار گرفته است، استفاده از فیتواستروژن‌ها است. مطالعات قبلی نشان داده است که گیاه ویتکس حاوی سطوح بالایی از فیتواستروژن است. در مورد این که آیا فیتواستروژن‌های موجود در گیاه ویتکس برای اتصال کدام گیرنده (استروژن آلفا یا بتا) را انتخابی می‌کند اختلاف نظر وجود دارد. با در نظر گرفتن این موضوع که در اوویداکت مرغ تخم‌گذار تنها گیرنده استروژن آلفا حضور دارد، در این آزمایش از مرغ‌های تخم‌گذار به عنوان مدل برای یافتن پاسخ استفاده شد. در این مطالعه اثر پودر میوه ویتکس بر عملکرد، کیفیت تخم مرغ، پاسخ ایمنی و بیان ژن‌های LH، GnRH، اووئوئید و اووآلبومین در مرغ‌های تخم‌گذار بررسی شد. تعداد ۹۰ قطعه مرغ تخم‌گذار لگهورن (Hy-Line, W-36) در سن (۷۲ تا ۸۰ هفته‌گی) در قالب طرح کاملاً تصادفی با سه تیمار و پنج تکرار مورد استفاده قرار گرفت. تیمارها سطوح مختلف پودر میوه ویتکس شامل سطوح صفر، ۱ و ۲ درصد پودر میوه ویتکس به ازای هر کیلوگرم جیره بودند. نتایج تحقیق حاضر نشان داد که پارامترهای عملکرد، کیفیت تخم‌مرغ و پاسخ‌های ایمنی تحت تأثیر سطوح مختلف پودر میوه ویتکس قرار نگرفتند. نتایج واکنش زنجیره‌ای پلیمرز در زمان واقعی نشان داد که سطوح مختلف پودر میوه ویتکس تأثیر معنی‌داری بر بیان ژن‌های LH، اووئوئید و اووآلبومین ندارد. با این حال، بیان ژن GnRH در تیمار ۳ (جیره غذایی حاوی ۲ درصد ویتکس نسبت به گروه شاهد و ۱ درصد ویتکس به طور قابل توجهی افزایش یافت. علاوه بر این، افزودن ۱ درصد پودر میوه ویتکس به جیره تأثیر معنی‌داری بر بیان ژن GnRH نداشت. در نتیجه، مصرف مکمل میوه ویتکس در مرغ‌های تخم‌گذار توصیه نمی‌شود. علاوه بر این، داده‌های ما این نظریه را تقویت می‌کند که فیتواستروژن‌های موجود در میوه‌های ویتکس، گیرنده استروژن بتا را برای اتصال یافتن انتخاب می‌کند.

کلمات کلیدی: ویتکس، بیان ژن، گیرنده استروژن، سرطان

\* نویسنده مسئول: محمود نظری، دانشیار گروه علوم دامی، دانشکده علوم دامی و صنایع غذایی، دانشگاه علوم کشاورزی و منابع طبیعی خوزستان، خوزستان، ملاتانی، ایران

E-mail: M.nazari@Asnrkh.ac.ir



© 2020 by the authors. Licensee SCU, Ahvaz, Iran. This article is an open access article distributed under the terms and conditions of the Creative Commons Attribution-NonCommercial 4.0 International (CC BY-NC 4.0 license) (<http://creativecommons.org/licenses/by-nc/4.0/>).

## اثرات عصاره *Froriepia subpinnata* بر تغییرات بیوشیمیایی سرمی و هیستوپاتولوژیک کبد در موش‌های صحرایی تیمار شده با تری کلرواستیک اسید

سیده حمیده طاهری اطاقسرا<sup>۱</sup>، قاسمعلی گروسی<sup>۲</sup>، حسین نجف‌زاده‌ورزی<sup>۳\*</sup> و سهراب کاظمی<sup>۵</sup>

<sup>۱</sup> دانشجوی بیوتکنولوژی گیاهی، دانشگاه بین‌المللی قزوین، قزوین، ایران

<sup>۲</sup> دانشیار گروه بیوتکنولوژی گیاهی، دانشگاه بین‌المللی قزوین، قزوین، ایران

<sup>۳</sup> مرکز تحقیقات بیولوژی سلولی و مولکولی، پژوهشکده سلامت، دانشگاه علوم پزشکی بابل، بابل، ایران و استاد گروه فارماکولوژی، دانشکده پزشکی، دانشگاه علوم پزشکی بابل،

بابل، ایران

<sup>۴</sup> دانشیار مرکز تحقیقات بیولوژی سلولی و مولکولی، پژوهشکده سلامت، دانشگاه علوم پزشکی بابل، بابل، ایران

تاریخ پذیرش: ۱۴۰۱/۹/۲۷

تاریخ دریافت: ۱۴۰۱/۵/۲۲

### چکیده

کارسینوم سلول‌های کبدی یکی از چالش‌های سیستم سلامت است و استرس اکسیداتیو نقش مهمی در بروز آن دارد. با توجه به اثرات آنتی‌اکسیدانی گیاه اناریجه (*Froriepia subpinnata* (FS)، این مطالعه با هدف بررسی اثر آن در جلوگیری از بروز سمیت کبدی ناشی از تری کلرواستیک اسید (TCA) در مدل حیوانی انجام شد. عصاره هیدروالکی اناریجه از اندام هوایی به روش خیساندن تهیه شد. چهل و هشت سر موش صحرایی به ۸ گروه تقسیم شدند: حیوانات کنترل، گروه‌های تحت درمان با TCA (۵۰۰ میلی‌گرم بر کیلوگرم)، گروه‌های تیمار شده با TCA + FS (۴۰۰، ۲۰۰، ۱۰۰ میلی‌گرم بر کیلوگرم)، گروه تیمار شده با TCA + DOX (۴۰۰ میلی‌گرم بر کیلوگرم) و گروه تیمار شده با TCA + DOX + FS (۲۰۰ میلی‌گرم بر کیلوگرم) و گروه تیمار شده با TCA + DOX + FS (۱۰۰ میلی‌گرم بر کیلوگرم). پس از ۲۸ روز، خون جمع‌آوری و سرم جدا شد، سپس مالون دی‌آلدئید (MDA)، گلوکاتینون پراکسیداز (GPx)، TAC (ظرفیت تام آنتی‌اکسیدانی)، آلانین آمینوترانسفراز (ALT)، آسپارات آمینوترانسفراز (AST)، آلکالین فسفاتاز (ALP)، فاکتور نکروز تومور-آلفا (TNF- $\alpha$ ) اندازه‌گیری شد و بافت کبد با میکروسکوپ نوری مورد بررسی هیستوپاتولوژیک قرار گرفت. TCA به طور معنی‌داری مقدار MDA را افزایش داد و TCA با غلظت‌های مختلف FS (۴۰۰، ۲۰۰ و ۱۰۰ میلی‌گرم بر کیلوگرم) مقدار MDA را در مقایسه با سایر گروه‌ها کاهش داد ( $P \leq 0.05$ ). مقدار TNF $\alpha$  توسط TCA کاهش یافت، اما با DOX به طور قابل توجهی افزایش یافت و تیمار FS اثر TCA بر سطح TNF $\alpha$  را تغییر نداد. سطح سرمی GPx، TAC، ALT، AST و ALP با تیمار TCA یا FS از نظر آماری تغییری نکرد TCA به بافت کبد آسیب رسانده و باعث انحطاط سلول‌های کبدی، تنگی سینوسی و واکوئل شدن سیتوپلاسم شد. FS به صورت وابسته به دوز از بافت کبد محافظت کرد اما در دوز ۴۰۰ میلی‌گرم بر کیلوگرم اثر بهتری در کاهش آسیب بافت داشت. FS یک اثر محافظتی در برابر تغییرات هیستوپاتولوژیک ناشی از TCA در بافت کبد موش صحرایی دارد.

**کلمات کلیدی:** اناریجه، تری کلرواستیک اسید، استرس اکسیداتیو، سمیت کبدی

\* نویسنده مسئول: حسین نجف‌زاده‌ورزی، مرکز تحقیقات بیولوژی سلولی و مولکولی، پژوهشکده سلامت، دانشگاه علوم پزشکی بابل، بابل، ایران و استاد گروه فارماکولوژی، دانشکده پزشکی، دانشگاه علوم پزشکی بابل، بابل، ایران

E-mail: h.najafzadeh@mubabol.ac.ir



© 2020 by the authors. Licensee SCU, Ahvaz, Iran. This article is an open access article distributed under the terms and conditions of the Creative Commons Attribution-NonCommercial 4.0 International (CC BY-NC 4.0 license) (<http://creativecommons.org/licenses/by-nc/4.0/>).



## بررسی سطح چربی، پروتئین و تولید شیر در گاوهای شیری هلشتاین تیمار شده با آرجنین

علی تیرگری<sup>۱</sup>، مجید محمدصادق<sup>۲\*</sup>، مرتضی گرجی دوز<sup>۳</sup>، علی افشار بهرآباد<sup>۴</sup> و نیما فرزانه<sup>۵</sup>

<sup>۱</sup> دانش‌آموخته دکترای عمومی، دانشکده دامپزشکی، واحد گرمسار، دانشگاه آزاد اسلامی، گرمسار، ایران

<sup>۲</sup> دانشیار، گروه علوم درمانگاهی، دانشکده دامپزشکی، واحد گرمسار، دانشگاه آزاد اسلامی، گرمسار، ایران

<sup>۳</sup> استادیار، گروه علوم درمانگاهی، دانشکده دامپزشکی، واحد گرمسار، دانشگاه آزاد اسلامی، گرمسار، ایران

<sup>۴</sup> دانش‌آموخته دکترای تخصصی، گروه مامایی و بیماری‌های تولید مثل، دانشکده دامپزشکی، دانشگاه فردوسی مشهد، مشهد، ایران

<sup>۵</sup> استاد، گروه علوم درمانگاهی، دانشکده دامپزشکی، دانشگاه فردوسی مشهد، مشهد، ایران

تاریخ دریافت: ۱۴۰۱/۸/۵

تاریخ پذیرش: ۱۴۰۱/۹/۹

### چکیده

در این مطالعه ۷۳ رأس گاو هلشتاین غیر آبستن سالم شیرده و از نظر بالینی بدون هیچ علامت بالینی و با میانگین تعداد زایش  $3/2 \pm 1/4$  روزهای شیردهی ابتدای مطالعه  $110 \pm 20$  روز، وضعیت بدنی  $0/3 \pm 3/2$  و میزان تولید شیر  $4/8 \pm 1/0$  کیلوگرم انتخاب شدند و به طور تصادفی در دو گروه تیمار و کنترل قرار گرفتند. در گروه درمان ( $n=36$ ) آرجنین (۱۵۵ میکرومول بر کیلوگرم وزن بدن) هر ۸ ساعت یک بار در روز به مدت ۶ روز و در گروه شاهد ( $n=37$ ) محلول نمکی ( $0/11$  میلی‌لیتر بر کیلوگرم وزن بدن) هر ۸ ساعت یک بار در روز به مدت ۶ روز تزریق شد. نتایج نشان داد که تولید شیر ( $3/8/5$  و  $3/6$  کیلوگرم،  $P=0/3$ )، چربی ( $3/7$  و  $3/8$  درصد،  $P=0/8$ ) و پروتئین ( $3/1$  و  $3/1$  درصد،  $P=0/5$ ) به ترتیب در گروه تیمار و شاهد تفاوتی نشان ندادند. نتایج به دست آمده نشان می‌دهد که در شرایط این مطالعه، استفاده از آرجنین پس از پیک تولید شیر نمی‌تواند باعث افزایش چربی، پروتئین و سطح تولید شیر شود.

**کلمات کلیدی:** آرجنین، آمینواسید، تولید شیرگاو هلشتاین، پروتئین و چربی شیر

\* نویسنده مسئول: مجید محمدصادق، دانشیار، گروه علوم درمانگاهی، دانشکده دامپزشکی، واحد گرمسار، دانشگاه آزاد اسلامی، گرمسار، ایران

E-mail: Majid.Mohammadsadegh@iau.ac.ir



© 2020 by the authors. Licensee SCU, Ahvaz, Iran. This article is an open access article distributed under the terms and conditions of the Creative Commons Attribution-NonCommercial 4.0 International (CC BY-NC 4.0 license) (<http://creativecommons.org/licenses/by-nc/4.0/>).

## ارزیابی کارائی همزمان سازی فعلی و عملکرد تولیدمثلی میش‌های فراهانی همزمان شده در فصل تولیدمثل با استفاده از لتروزول

محمد یحیائی<sup>۱\*</sup>، مهدی خدائی مطلق<sup>۲</sup> و سبحان آکریم علمدار<sup>۳</sup>

<sup>۱</sup> استادیار گروه علوم دامی، دانشکده کشاورزی و محیط زیست، دانشگاه اراک، اراک، ایران

<sup>۲</sup> استاد گروه علوم دامی، دانشکده کشاورزی و محیط زیست، دانشگاه اراک، اراک، ایران

<sup>۳</sup> دانشجوی کارشناسی ارشد علوم دامی، دانشکده کشاورزی و محیط زیست، دانشگاه اراک، اراک، ایران

تاریخ دریافت: ۱۴۰۱/۸/۱۴

تاریخ پذیرش: ۱۴۰۱/۹/۲۷

### چکیده

این پژوهش با هدف بررسی تأثیر کارایی جایگزینی گنادوتروپین با لتروزول در برنامه همزمان‌سازی فعلی بر پارامترهای تولیدمثلی و تغییرات هورمونی گوسفند در فصل تولیدمثل انجام شد. برای این منظور، ۴۰ رأس میش فراهانی با دامنه سنی ۳ تا ۴ سال، میانگین وزنی  $44 \pm 2/3$  کیلوگرم و میانگین نمره وضعیت بدنی  $3/12 \pm 0/5$  به مدت ۱۴ روز سیدرگذاری و به سه گروه تقسیم شدند: گروه شاهد (بدون تزریق هورمون)، گروه یکم (تزریق ۴۰۰ واحد eCG، تزریق درون ماهیچه‌ای)، گروه دوم (تزریق ۴۰۰ واحد hCG، تزریق درون ماهیچه‌ای) و گروه سوم ( $7/5$  میلی‌گرم لتروزول به شیوه خوراکی). نمونه خون از سه روز قبل از بیرون آوردن CIDR گرفته شد. فراسنجه‌های عملکرد تولیدمثلی پس از زایش محاسبه شدند. یافته‌ها نشان دادند که اگرچه باروری و بره‌زایی در گروه اول از نظر عددی بیشتر بودند؛ با این وجود تفاوت معنی‌داری بین گروه‌ها برای هیچ یک از فراسنجه‌های عملکرد تولیدمثلی وجود نداشت. غلظت استروژن در تمام تیمارها تا زمان برداشت سیدر روند افزایشی داشتند. به طور کلی، یافته‌های این پژوهش نشان دادند لیتروزول جایگزین قابل اعتمادی برای eCG برای افزایش میزان تخم‌کریزی در گوسفند نیست.

**کلمات کلیدی:** لتروزول، عملکرد تولیدمثلی، همزمان سازی فعلی

\* نویسنده مسئول: محمد یحیائی، استادیار گروه علوم دامی، دانشکده کشاورزی و محیط زیست، دانشگاه اراک، اراک، ایران

E-mail: m-yahyayi@araku.ac.ir



© 2020 by the authors. Licensee SCU, Ahvaz, Iran. This article is an open access article distributed under the terms and conditions of the Creative Commons Attribution-NonCommercial 4.0 International (CC BY-NC 4.0 license) (<http://creativecommons.org/licenses/by-nc/4.0/>).

## **Acknowledgement**

We sincerely thank all the esteemed reviewers who have had valuable and wise cooperation in reviewing and evaluating the articles in this issue of the Iranian Veterinary Journal.

### **The names of the reviewers in alphabetical order**

Mohadeseh Abouhosseini Tabari, Baharak Akhtardanesh, Zahra Basir, Mohammad Hassan Hablolvarid, Saeid Hosseinzadeh, Ghader Jalilzadeh-Amin, Meysam Makki, Behrooz.Mihandoost, Mohammadreza Mohammadabadi, Majid Mohammad Sadegh, Bahman Mosallanejad, Ahmad Reza Raji, Gholamhosein Tahmasbi, Shahnaz yusefizadeh and Abdolkarim Zamani Moghaddam.

# بسم الله الرحمن الرحيم

## مجله دامپزشکی ایران

### فهرست مطالب

#### عنوان

#### صفحه

۱

• راهنمای تدوین مقاله

۹۶

• بررسی یافته‌های اپیدمیولوژیک و بالینی پرکاری قشر غده فوق کلیه سگ در ایران  
محمد اسدی ایرایی، رضا آویزه، محمد راضی جلالی و مهدی پورمهدی بروجنی

۹۷

• ارتباط بین حضور DNA و آنتی‌بادی سرم در طول انتقال عمودی نئوسپورا کنیوم  
راضیه آیتی، حسین رضوان، مهدی نام‌آوری، علی صادقی‌نسب، سحر هامون‌نورد و بهرام دادمهر

۹۸

• بررسی ساختار بافت‌شناسی معده در پرندگان شکاری دلججه (*Falco tinnunculus*)، عقاب صحرایی (*Aquila nipalensis*)، عقاب طلایی (*Aquila chrysaetos*) و عقاب شاه‌ی (*Aquila heliaca*)  
علی کلانتری‌حصاری، محمد بابائی، کاوه اسفندیاری و حسن مروتی

۹۹

• تأثیر افزودن عصاره پوست بادمجان (*Solanum melongena*) بر اسپرم قوچ فراهانی پس از تنش اکسیداتیو (انجماد-ذوب)  
حمیدرضا خدادادی، مهدی خدایی‌مطلق، مهدی کاظمی‌بنچناری و حمیدرضا مومنی

۱۰۰

• شناسایی سلول‌های زایای اولیه در گندهای نر رویان‌های قرقاول (*Phasianus colchicus*) با استفاده از تکنیک‌های هیستوشیمیایی و رنگ‌آمیزی ایمنی  
فرهاد محمدی‌قشلاق، اعظم حسینی و ابوالقاسم نبی‌پور

۱۰۱

• اثر تغذیه میوه ویتکس بر بیان نشانگرهای هیپوتالاموس-هیپوفیز-تخمدان و سیستم ایمنی مرغ تخم‌گذار: اتصال فیتواستروژن‌های میوه ویتکس به گیرنده استروژن بنا  
محمود نظری، محمدرضا قربانی، محمدتقی بیگی‌نصیری، ندا فتحی‌مقدم، راضیه صباحی و سیده تقوا موسوی

۱۰۲

• اثرات عصاره *Froriepiea subpinnata* بر تغییرات بیوشیمیایی سرمی و هیستوپاتولوژیک کبد در موش‌های صحرایی تیمار شده با تری کلرواستیک اسید  
سیده حمیده طاهری اطاقسرا، قاسمعلی گروسی، حسین نجف‌زاده‌ورزی و سهراب کاظمی

۱۰۳

• بررسی سطح چربی، پروتئین و تولید شیر در گاوهای شیری هلشتاین تیمار شده با آرجنین  
علی تیرگری، مجید محمدصادق، مرتضی گرجی‌دوز، علی افشار بهرآباد و نیما فرزانه

۱۰۴

• ارزیابی کارایی همزمان سازی فحلی و عملکرد تولیدمثلی میش‌های فراهانی همزمان شده در فصل تولیدمثل با استفاده از لئروزول  
محمد یحیائی، مهدی خدائی‌مطلق و سبحان آکریم‌علمدار

# مجله دامپزشکی ایران

صاحب امتیاز: دانشگاه شهید چمران اهواز

مدیرمسئول: دکتر منصور میاحی

سر دبیر

دکتر محمدرحیم حاجی حاجیکلائی

کارشناس مجله

منا عباسی

اعضاء هیأت تحریریه (به ترتیب حروف الفبا)

دکتر معصومه احمدی زاده، استاد سم شناسی، دانشکده بهداشت، دانشگاه علوم پزشکی جندی شاپور اهواز  
دکتر بهارک اختر دانش، استاد بیماری های داخلی دام های کوچک، دانشکده دام پزشکی، دانشگاه شهید باهنر کرمان  
دکتر علی بنی آدم، دانشیار جراحی، دانشکده دام پزشکی، دانشگاه شهید چمران اهواز  
دکتر مهدی پور مهدی بروجنی، دانشیار اپیدمیولوژی، دانشکده دام پزشکی، دانشگاه شهید چمران اهواز  
دکتر عباس جلودار، دانشیار ژنتیک ملکولی، دانشکده دام پزشکی، دانشگاه شهید چمران اهواز  
دکتر محمدرحیم حاجی حاجیکلائی، استاد بیماری های داخلی دام های بزرگ، دانشکده دام پزشکی، دانشگاه شهید چمران اهواز  
دکتر حسین حمیدی نجات، استاد انگل شناسی، دانشکده دام پزشکی، دانشگاه شهید چمران اهواز  
دکتر محمد راضی جلالی، استاد کلینیکال پاتولوژی، دانشکده دام پزشکی، دانشگاه شهید چمران اهواز  
دکتر رضا رنجبر، دانشیار علوم تشریحی، دانشکده دام پزشکی، دانشگاه شهید چمران اهواز  
دکتر شیمیا شاهین دوران، استاد بیماری های داخلی، دانشکده دام پزشکی، دانشگاه مهمت آکیف ترکیه  
دکتر مسعود رضا صیفی آباد شاپوری، استاد ویروس شناسی، دانشکده دام پزشکی، دانشگاه شهید چمران اهواز  
دکتر ملیحه عباسعلی پور کبیره، استاد بیوشیمی بالینی، دانشکده دام پزشکی، دانشگاه تهران  
دکتر محمد کاظم غریب ناصری، استاد فیزیولوژی، دانشکده پزشکی، دانشگاه علوم پزشکی جندی شاپور اهواز  
دکتر مهری غفوریان بروجردنیا، استاد ایمونولوژی، دانشکده پزشکی، دانشگاه علوم پزشکی جندی شاپور اهواز  
دکتر مسعود قربانپور، استاد میکروبیولوژی، دانشکده دام پزشکی، دانشگاه شهید چمران اهواز  
دکتر گیتی کریم، استاد بهداشت مواد غذایی، دانشکده دام پزشکی، دانشگاه تهران  
دکتر راگونات کوهلی، استاد جراحی و سر دبیر مجله انجمن ملی علوم دام پزشکی هندوستان  
دکتر حسن مروتی، استاد بافت شناسی، دانشکده دام پزشکی، دانشگاه تهران  
دکتر ثریا نائم، استاد انگل شناسی، دانشکده دام پزشکی، دانشگاه ارومیه  
دکتر حسین نجف زاده ورزی، استاد فارماکولوژی، دانشکده پزشکی، دانشگاه علوم پزشکی بابل  
دکتر فرید همت زاده، دانشیار ویروس شناسی، دانشکده علوم دام پزشکی، دانشگاه آدلاید، استرالیا

هیأت مشاورین علمی

اعضاء هیأت علمی کلیه دانشکده های دام پزشکی و دیگر دانشکده ها و مراکز تحقیقاتی زیربط کشور

آدرس پستی سر دبیر

اهواز، دانشگاه شهید چمران اهواز، دانشکده دام پزشکی، سر دبیر مجله علمی، کد پستی ۶۱۳۵۵، صندوق پستی ۱۴۵

تلفن و دورنگار: ۳۳۳۳۶۳۱۲ (۰۶۱)

E-mail: ivj@scu.ac.ir

- این مجله به استناد نامه شماره ۵۴۵/۲۹۱۰ مورخ ۸۴/۵/۸ کمیسیون برر سی ذریات وزارت علوم، تحقیقات و فناوری دارای درجه علمی - پژوهشی می باشد.
- این مجله در فهرست ذریات علمی پژوهشی معتبر ISC که دارای ضریب تأثیر (IF) می باشد، قرار دارد. این اعتبار از سوی وزارت علوم، تحقیقات و فناوری تعیین شده است و در آئین نامه ارتقای مرتبه علمی دانشگاه ها و موسسات آموزشی مورد بهره برداری قرار می گیرد.
- متن کامل مقالات در پایگاه استنادی علوم جهان اسلام (ISC) قابل دسترسی می باشد.

چاپ و صحافی

مرکز منطقه ای اطلاع رسانی علوم و فناوری و پایگاه استنادی جهان اسلام