

Recurrent Pemphigus Foliaceus in Horse: A Case Report

Ali Sadeghi-nasab^{1*}, Seyed Massoud Zolhavarieh¹, Javad Ashrafihelan²,
Zainab Sadeghi Dehkordi³, Aliasghar Bahari⁴ and Alireza Nourian⁵

¹ Assistant professor, Department of Clinical Sciences, Faculty of Veterinary Sciences, Bu-Ali Sina University, Hamedan, Iran

² Professor, Department of Pathobiology, Faculty of Veterinary Medicine, University of Tabriz, Tabriz, Iran

³ Assistant Professor, Department of Pathobiology, Faculty of Veterinary Sciences, Bu-Ali Sina University, Hamedan, Iran

⁴ Associate Professor, Department of Clinical Sciences, Faculty of Veterinary Sciences, Bu-Ali Sina University, Hamedan, Iran

⁵ Associate Professor, Department of Pathobiology, Faculty of Veterinary Sciences, Bu-Ali Sina University, Hamedan, Iran

Received: 15.03.2023

Accepted: 09.06.2023

Abstract

An 8-year-old crossbred thoroughbred chestnut stallion was suspected to an autoimmune mediated skin disease based on history, clinical observations, microbiological and clinicopathologically findings. The clinical signs disappeared completely after five weeks of treatment with PO prednisolone. However, approximately eight months later, the lesions recurred in a more severe form. There was no improvement despite the repeating previous treatment by horse's owner; therefore, oral azathioprine was added to prednisolone after skin biopsy. A significant therapeutic effect was observed by this combination, however; the use of azathioprine was discontinued after fifteen days due to diarrhea, while prednisolone continued for another week. After improvement of the symptoms, oral prednisolone was also stopped with a decreasing trend. Vesiculobullous to pustular lesions with acantholytic characteristic of the stratum corneum and stratum granulosum of epidermis were the histopathological findings, characteristics of pemphigus foliaceus. This is the first reported case of recurrent pemphigus foliaceus in Iran.

Key words: Autoimmune, Histopathology, Relapse, Skin, Type II Hypersensitivity

Introduction

Pemphigus refers to a group of uncommon to rare autoimmune skin diseases characterized clinically by pustules, blisters, scabs, and ulcers and histologically by acantholysis (Maxie, 2015; Scott and Miller, 2010). However, pemphigus foliaceus is the most common type of the pemphigus disease in horses (Felippe, 2016; Olivry and Chan, 2001; Rosenkrantz, 2013; Scott and Miller, 2010). The disease is classified as type II

hypersensitivity reaction associated with the production of autoantibodies against keratinocyte surface proteins responsible for cell attachment (Maxie, 2015; Scott and Miller, 2010). Pemphigus foliaceus has been reported in horses aged 2 months to 25 years (Felippe, 2016; Rosenkrantz, 2013; Scott and Miller, 2010) and age, sex, and breed have not been proven to be a predisposing factor (Felippe, 2016; Olivry and Chan, 2001). Clinical signs may appear

* **Corresponding Author:** Ali Sadeghi-nasab, Assistant Professor, Department of Clinical Sciences, Faculty of Veterinary Science, Bu-Ali Sina University, Hamedan, Iran
E-mail: sadeghinasabali@basu.ac.ir



after stress, drug administration, vaccination, general illness or hypersensitivity urticarial (Felippe, 2016; Scott and Miller, 2010). The first clinical manifestation is edema of the abdomen and hind limbs (Felippe, 2016; Petersen and Schott, 2005). Seborrhea and scaling are the most prominent lesions in most horses with pemphigus foliaceus, which are mostly seen on the face, legs, trunk, and abdomen (Felippe, 2016; Olivry and Chan, 2001; Rosenkrantz, 2013; Scott and Miller, 2010). Often fragile and temporary vesicular, bullous or pustular lesions appear, then crusts form on the lesions. The circular pattern of alopecia is patchy with varying degrees of skin exudation (Felippe, 2016; Rosenkrantz, 2013; Scott and Miller, 2010). In some cases, the coronary band of the hoof, prepuce and breast are also involved (Scott and Miller, 2010). One of the remarkable points in the clinical diagnosis of pemphigus foliaceus lesions is confined to hairy skin areas, while mucous membranes are involved simultaneously and even earlier than the skin in pemphigus vulgaris. Typically, the lesions spread to other areas of the body within one to three months (Felippe, 2016; Scott and Miller, 2010). Variable itching and pain have been reported in 50% of cases (Scott and Miller, 2010). General symptoms such as depression, lethargy, loss of appetite, weight loss and fever have been observed in some patients (Felippe, 2016; Olivry and Chan, 2001; Petersen and Schott, 2005; Scott and Miller, 2010).

Case history

Clinical examination of an 8-year-old thoroughbred chestnut stallion weighing approximately 400 kg was performed for skin lesions in December 2018 in a riding club, Hamedan-Iran. Based on the history, the animal displayed normal behavior, proper nutritional status and appetite. However, along with mild itching, some skin lesions including scaling and exfoliation in the seborrheic areas of the groin, under the tail, and around the anus were arisen about 10 days earlier, which were later spread to other areas. Despite repeated topical antifungal treatments with Licoderm® solution, sulfur soap, washing with 10% povidone-iodine, and oral and injectable ivermectin, no signs of improvement were observed.

Body temperature was 38.9 °C, and cardiovascular, respiratory and digestive systems were clinically normal. Severe desquamation, hyperkeratosis, leathery texture, and skin lichenification with annular distribution were observed along with hair loss in different parts of the body (Figure 1). There was no obvious erythroderma, but mild tenderness and mild symptoms of pain and itching were noted on palpation. Nikolsky's sign was presented. Although most parts of the skin were involved to varying degrees, the majority of involvement was concentrated in the crest, withers, croup to dock, and under tail (Figure 1). Oral mucous membrane, conjunctiva and prepuce were normal. One week after discontinuation of all medications, skin scraping and hair clipping were carried out for parasitic and fungal examination.

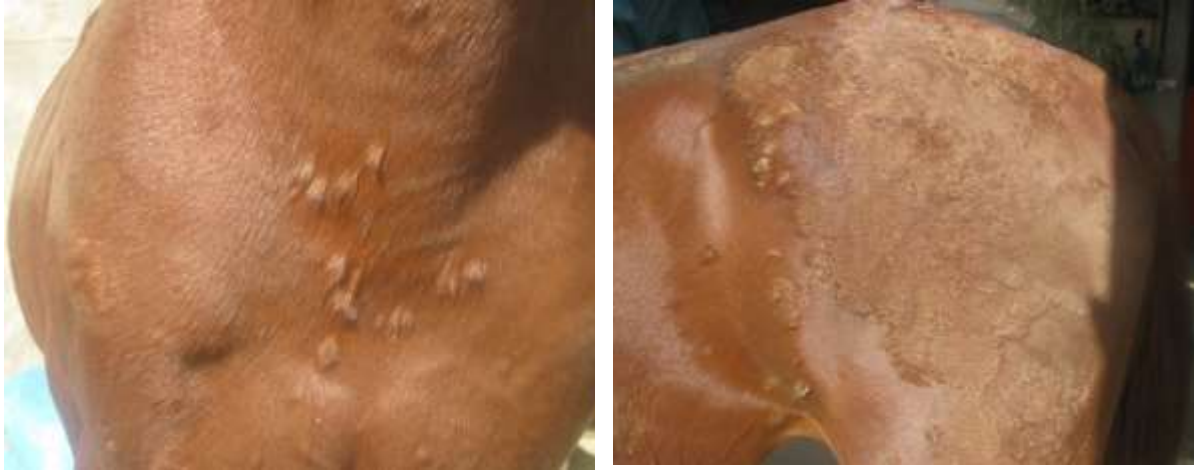

Figure 1: Skin lesions related to the first involvement of an 8 years old thoroughbred chestnut stallion; Left) Large separated bullae of the chest area. Right) distribution pattern of lesions on hindquarter area, lichenification and leathery skin.

Clinical pathology and histopathological findings

Direct microscopic examination and fungal culture did not reveal any dermatophyte or ectoparasite involvement. Clinicopathological findings were as follows: PCV: 31%, RBC: 4.74×10^6 cells/McL, Hg: 11.48 g/dL, MCV: 67.65 fL, MCH: 24.27 pg, MCHC: 35.85 g/dL, WBC: 14800 cell/McL, Neut: 76%, Lym: 16%, Mon: 6%, Eos: 2%, Urea: 26 mg/dL, Creatinine: 1.15 mg/dL, Total Bilirubin: 1.9 mg/dL, Direct Bilirubin: 0.17 mg/dL, Indirect Bilirubin: 1.73 mg/dL, SGOT: 135 IU/L, SGPT: 10 IU/L, ALP: 303 IU/L, GGT: 10 IU/L, Fibrinogen: 700 mg/dL, Serum Total Protein: 9.4 g/dL, Albumin: 3.1 g/dL, Na: 136 mEq/L, K: 4.46 mEq/L, Desmoglein-1: 1 IU/mL, Desmoglein-3 1.8 IU/mL.

An increase in the number of white blood cells, percentage of neutrophils, urea, serum protein and plasma fibrinogen were considered as indicators of an acute phase inflammatory process. Based on the findings, anamnesis and clinical observations, an autoimmune mediated skin disease was proposed. An increasing dose of prednisolone at 0.2 mg/kg/day PO was prescribed which was increased up to 1 mg/kg/day PO after 5 days. This therapeutic

dose was continued for three weeks. Brushing and exposure to direct sunlight were prohibited. One week after receiving the full dose, an acceptable response was observed with reduced scaling, less leathery skin and new hair growth. Prednisolone was eventually stopped with 0.2 mg/kg reduction every other day.

In September 2019, the previous skin lesions appeared more severe and spread with excessive emaciation of the body (Figure 2). After two weeks of using the previous year's treatment by the owner and not responding properly, the horse was referred for medical examination. An intact rounded bulla at pectoral region was biopsied under local anesthesia and fixed in 10% buffered formalin for histopathological examination.

In addition to 1 mg/kg/day PO prednisolone, an oral administration of azathioprine was added. Azathioprine was also started at 0.2 mg/kg PO and increased up to 1 mg/kg PO after 5 days. Despite the significant effects of this combined treatment, azathioprine administration was stopped on the 15th day of treatment due to diarrhea, while prednisolone treatment was continued for another week and stopped with a decreasing trend when signs of improvement were observed.

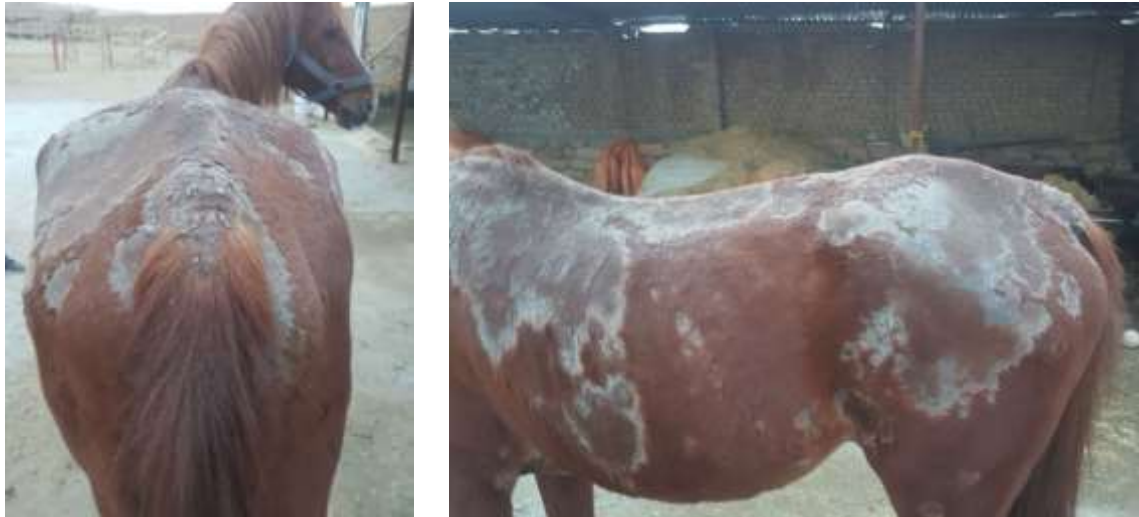

Figure 2: Shape and distribution pattern of skin lesions related to the second involvement of a 9 years old chestnut thoroughbred stallion. Right) Lateral view of the body, withers, chest, back and croup. Left) Posterior view of the body.

Vesiculobullous to pustular lesions with acantholytic features (decreased connectivity and continuity between keratinocytes) were observed in cutaneous histopathology (Figure 3). Primary blisters appeared as acantholysis under the stratum corneum and in the stratum granulosum. The severity of the lesions was clearly milder than typical histopathological lesions, which seems to be due to glucocorticoid treatment before biopsy. The stratum corneum was thin due to removal of the superficial layer, but the deeper areas of the epidermis were intact. Small vacuoles were observed in the intercellular space of primary lesions in the upper parts of the epidermis, and surface cracks or blisters were created from the connection of these vacuoles in the upper parts of the stratum granulosum or immediately below the stratum corneum. Older lesions were acantholytic, papillomatous and hyperkeratotic with focal parakeratosis. In these granular lesions, keratinocyte changes were observed, distinguishing pemphigus foliaceus from pemphigus vulgaris (Figure 3). Eosinophilic and neutrophilic infiltration was observed in the dermis.

Discussion and conclusion

Based on histopathology results, pemphigus foliaceus was confirmed. This is the first

report of equine recurrent pemphigus foliaceus from Iran.

Definitive diagnosis is based on the observation of vesiculopustular lesions in the stratum corneum and within the epidermis of the skin with acantholysis (Felippe, 2016; Maxie, 2015; Petersen and Schott, 2005; Scott and Miller, 2010). Although the desmosomal protein, desmoglein-1 can be identified as the most important internal antigen in the blood of infected humans and dogs (Petersen and Schott, 2005; Smith, 2015; Tizard, 2017), it is undetectable in about 50% of patient horses (Rosenkrantz, 2013).

The differential diagnosis of pemphigus foliaceus in horses includes diseases with alopecia and scaling manifestations such as dermatophytosis, dermatophilosis, bacterial folliculitis, sarcoidosis, multi-systemic eosinophilic epitheliotrope disease, seborrhea, skin side effects, and epitheliotropic drug reactions (Felippe, 2016; Maxie, 2015; Scott and Miller, 2010). Moreover, dermatophytosis caused by *Trichophyton equinum* can cause some clinical and histopathological evidences of pemphigus foliaceus that can be ruled out by mycological examination or immunohistochemical staining of skin biopsies (Felippe, 2016; Maxie, 2015).

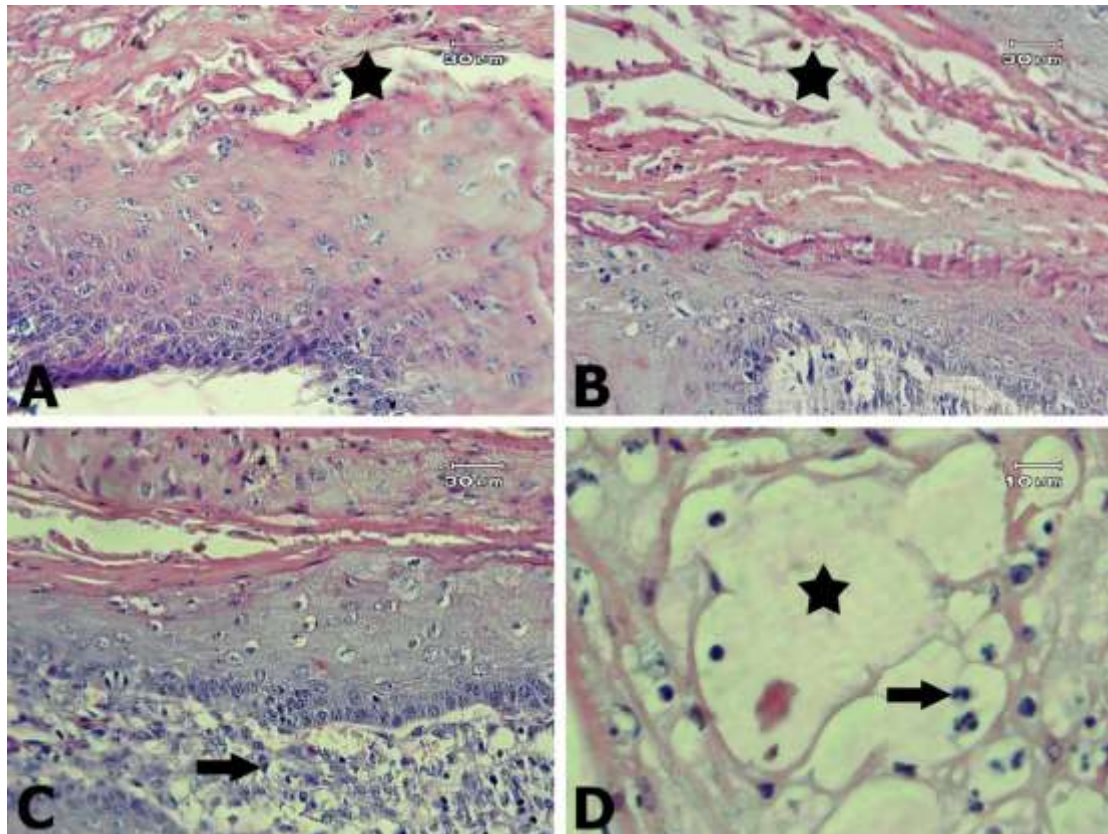


Figure 3: Light microscopic view of pemphigus foliaceus lesions in the horse's skin. A, B) Intraepidermal vesiculopustular dermatitis along with the cleavage of epidermis (asterisks). C) Inflammation with the mild infiltration of polymorphonuclear leukocytes (arrow). D) A closer view of the vesiculopustular lesion (asterisk) within the stratum granulosum of the epidermis along with the mild infiltration of polymorphonuclear leukocytes (arrow). A, B, C $\times 400$, D $\times 1000$; Hematoxylin & Eosin.

Immunosuppressive drugs, such as corticosteroids, azathioprine, pentoxifylline, or sodium aurothiomalate, are generally recommended as the selective first line treatment for pemphigus foliaceus and other bullous dermatoses (Olivry and Chan, 2001). It seems that treatment in yearling foals has a better prognosis than animals over five years of age (Felippe, 2016; Scott and Miller, 2010). Although spontaneous remission is rarely reported,

the treatments must be prolonged for life in more than half of patients due to relapse after months to years. Treatments are often effective, but unfortunately, long-term treatment with glucocorticoids may lead to diseases such as equine laminitis (Felippe, 2016; Petersen and Schott, 2005; Scott and Miller, 2010). Unfortunately, due to the sale of the horse and inability to contact with the new owner the possibility of follow-up was lost in 2020.

Acknowledgements

The authors are grateful for the scientific guidance of Dr. Parvaneh Seifory.

Conflict of interest

The authors confirm the absence of any conflict of interest with any natural or legal person.

Funding

This case report was funded by the research grants of Faculty of Veterinary Sciences, Bu-Ali Sina University, Hamedan, Iran

References

- Felippe, M. J. B. (2016). *Equine Clinical Immunology (1st ed)*. Oxford, UK: John Wiley and Sons.
- Maxie, M. G. (2015). *Jubb, Kennedy & Palmer's pathology of domestic animals (6th ed), volume 1*. St. Louis, Missouri: Elsevier Health Sciences, Saunders.
- Olivry, T., & Chan, L. S. (2001). Autoimmune blistering dermatoses in domestic animals. *Clinics in Dermatology*, 19(6), 750-760 .
- Petersen, A. D., & Schott, H. C. (2005). Cutaneous markers of disorders affecting adult horses. *Clinical Techniques in Equine Practice*, 4(4), 324-338 .
- Rosenkrantz, W. (2013). Immune-mediated dermatoses. *Veterinary Clinics: Equine Practice*, 29(3), 607-613 .
- Scott, D. W., & Miller, W. H. (2010). *Equine Dermatology (2nd ed)*. Maryland Heights, Missouri: Elsevier Health Sciences, Saunders.
- Smith, B. (2015). *Large Animal Internal Medicine (5th ed)*. Portland, Oregon: Mosby publishing.
- Tizard, I. R (2017). *Veterinary Immunology (10th ed)*. St. Louis, Missouri: Elsevier Health Sciences, Saunders.
- Received: 15.03.2023
Accepted: 09.06.2023

گزارش یک مورد پمفیگوس فولیاسئوس راجعه در اسب

علی صادقی نسب^{۱*}، سید مسعود ذوالحواریه^۱، جواد اشرفی هلان^۲، زینب صادقی دهکردی^۳،
علی اصغر بهاری^۴ و علیرضا نوریان^۵

^۱ استادیار گروه علوم درمانگاهی، دانشکده پیرادامپزشکی، دانشگاه بوعلی سینا، همدان، ایران

^۲ استاد گروه پاتوبیولوژی، دانشکده دامپزشکی، دانشگاه تبریز، تبریز، ایران

^۳ استادیار گروه پاتوبیولوژی، دانشکده پیرادامپزشکی، دانشگاه بوعلی سینا، همدان، ایران

^۴ دانشیار گروه علوم درمانگاهی، دانشکده پیرادامپزشکی، دانشگاه بوعلی سینا، همدان، ایران

^۵ دانشیار گروه پاتوبیولوژی، دانشکده پیرادامپزشکی، دانشگاه بوعلی سینا، همدان، ایران

تاریخ پذیرش: ۱۴۰۲/۳/۱۹

تاریخ دریافت: ۱۴۰۱/۱۲/۲۴

چکیده

بر اساس سابقه، مشاهدات بالینی و آزمایش‌های میکروبیولوژی و کلینیکال پاتولوژی، یک رأس نریان ک رنگ ۸ ساله نژاد تروبرد دوخون، مشکوک به بیماری پوستی با منشأ خودایمن تشخیص داده شد. درمان با استفاده از تجویز خوراکی پردنیزولون به مدت پنج هفته به صورت موفقیت‌آمیزی انجام شد. حدود هشت ماه بعد و پس از عود ضایعات پوستی شدیدتر، علیرغم استفاده از رژیم درمانی قبلی به مدت دو هفته توسط اسبدار، پاسخ مناسبی مشاهده نشد. بنابراین پس از بیوپسی پوست جهت آزمایش‌های هیستوپاتولوژی، تجویز خوراکی آزاتیوپرین نیز به درمان خوراکی پردنیزولون اضافه گردید. رژیم درمانی جدید تأثیر چشمگیری بر روند درمان داشت ولی پس از پانزده روز به دلیل بروز اسهال، مصرف آزاتیوپرین قطع شد و درمان با پردنیزولون تا یک هفته دیگر ادامه یافت. پس از مشاهده نشانه‌های بهبودی، تجویز این دارو با روند کاهشی قطع گردید. یافته‌های هیستوپاتولوژی شامل ضایعات وزیکولوبولوس تا پوستول با مشخصه آکانتولیز زیر لایه شاخی و در لایه دانه‌دار پوست، پمفیگوس فولیاسئوس را تأیید نمود. این مورد اولین گزارش پمفیگوس فولیاسئوس راجعه در ایران می‌باشد.

کلمات کلیدی: افزایش حساسیت تیپ ۲، پوست، خودایمن، راجعه، هیستوپاتولوژی

* نویسنده مسئول: علی صادقی نسب، استادیار گروه علوم درمانگاهی، دانشکده پیرادامپزشکی، دانشگاه بوعلی سینا، همدان، ایران

E-mail: sadeghinasabali@basu.ac.ir



© 2020 by the authors. Licensee SCU, Ahvaz, Iran. This article is an open access article distributed under the terms and conditions of the Creative Commons Attribution-NonCommercial 4.0 International (CC BY-NC 4.0 license) (<http://creativecommons.org/licenses/by-nc/4.0/>).