

Short paper, Morphometric study of the cerebrum and cerebellum in Indian Gray Mongoose (*Herpestes edwardsii*)

Babak Rasouli¹, Soghra Gholami^{2*} and Younes Kamali³

¹Assistant Professor, Department of Basic Sciences, Faculty of Veterinary Medicine, Semnan University, Semnan, Iran

²Professor, Department of Basic Sciences, Faculty of Veterinary Medicine, Shiraz University, Shiraz, Iran

³Assistant Professor, Department of Basic Sciences, Faculty of Veterinary Medicine, Shiraz University, Shiraz, Iran

Received: 10.11.2020

Accepted: 14.07.2021

Abstract

Mongoose is a common name for 30 species of the family Herpestidae found in a vast area of southwestern Asia, especially Iran. Morphometric studies of the brain have been topics of interest to anatomy researchers due to their high importance in veterinary and zoology fields. The present study was conducted to better understand the brain's morphometric features in Mongoose because of the lack of information about the brain structure in wild carnivores. For this purpose, eight carcasses of adult mongooses were used. They were found in different Fars province areas in Iran, which were dead due to natural causes. The brain was then carefully separated from the skull, and all the measurements and observations related to different parts of the brain were recorded. The values entered the computer separated by gender, and SPSS 22 and T. student tests were used for statistical analysis while the significance level of $P \leq 0.05$ was considered. This study showed that the ratio of brain weight to body weight (EQ) and the ratio of cerebellum weight to total brain weight in mongoose are higher than other carnivores. All the brain's morphometric findings in mongooses are in unparalleled harmony with their lifestyle. Also, no difference was found between the mongoose and other carnivores such as dogs and cats regarding the gyri and sulci's number and pattern. The current work is a preliminary assessment, and new imaging methods are suggested for more advanced studies.

Key words: Mongoose, Brain, Anatomy, Morphometry

Introduction

Mongoose fall into the order of carnivores and infra-order of feliformia. This family includes 30 species, all of which are generally called mongooses. Mongoose is relatively widespread geographically and is found in many areas in Asia and the north of Africa. The Indian gray mongoose is seen in Fars Province's southern areas with a body of 30 to 50 cm long and fawnish-tawny color and a hairy tail as long as the body (Rasouli *et*

al. 2015). Despite extensive studies on the domestic animals' nervous system, this has received little attention in wild and exotic animals. Nonetheless, in recent years the research has been carried out on the anatomy of cerebrum and cerebellum in giraffe (Graicet *et al.*, 2017), rat (Ibegbu *et al.*, 2013), rabbit and hamsters (Abraham *et al.*, 2016), and chinchilla (Irimescu *et al.*, 2014). The only study on the mongoose's brain in 2020 was conducted by

* **Corresponding Author:** Soghra Gholami, Department of Basic Sciences, Faculty of Veterinary Medicine, Shiraz University, Shiraz, Iran, E-mail: Gholami@shirazu.ac.ir



Rasouli and Gholami, which focused on the brain's histological aspects. The aim of a comparative evaluation of the properties of mature mongooses and finding the differences and similarities between mongooses and other animals.

Due to the lack of information about the brain's morphometric properties in mongooses, the present study was designed and conducted to find the differences and similarities between mongooses and other animals. The findings of this study can be considered as the basis for more comprehensive studies. In case the conditions are provided to keep the animal and investigating the anatomical properties of the brain structure in their fetus, there can be hope that complete findings will be obtained in this regard in the future. These findings can be practical and useful to study the nervous system's teratology and pathology, behavioral research, increase the anatomical knowledge in carnivores, and introduce mongoose as an indigenous animal (Irimescu et al., 2014 Rasouli *et al.* 2020).

Materials and Methods

To conduct the present study, eight adult Indian gray mongoose carcasses (four males and four females). The animals' age was estimated to be more than one-year-old concerning the teeth inspection (Rasouli *et al.* 2020). These specimens were newly found in nature that had died of natural causes, collected from different parts of Fars province, Iran. It is noteworthy that everything was conducted under the Department of Environmental Protection in Fars Province. The head moved away from the rest of the body and placed in 10% Formalin. After a week, the brain was extracted from the skull for more accurate examinations. A graded caliper (INSIZE,

Model: 1502S-1205, USA) was used to measure the length of different areas, and laboratory scales (A&D, Model: EK6100I, Japan) were used to measure the weight of the different structure. The values entered the computer, and SPSS 22 and T. student tests were used for statistical analysis while the significance level of $P \leq 0.05$ was considered.

Results

The weight of different areas of the cerebrum and cerebellum is presented in table 1, separated by gender. Considering the total body weight, which is 1182.85 gr. in males and 830.72 gr. in females, the total brain weight ratio to body weight or the encephalization quotient (EQ) is 0.95 % in male and 1 % in female mongooses on average. Also, the mean ratio of cerebellum weight to brain weight was 16.21 % in males and 15.1 % in female mongooses.

From the lateral view, the olfactory bulbs were in the most rostral part of the brain. As the holder and base of the olfactory bulb, the olfactory peduncle was in the ventral position in a piriform shape. From this view, the cerebral hemispheres were tangled and in a triangle form. Moreover, the transverse fissure was the deepest at this view. The occipital lobe that forms the occipital pole of the cerebral hemispheres covered the frontal half of the cerebral hemispheres dorsally (figure 1).

After the median section and separation of the two cerebral hemispheres, the fully developed sickle-shaped corpus callosum showed up. The rostral part of the brain was wide, and the caudal part was narrow. From this view, the rostral and caudal colliculus were observed at the same size, and the midbrain tegmentum area was below them (figure 2).

Table 1. Mean and standard deviation of morphometric characteristics of cerebrum and cerebellum in males and females (* significant difference P≤0.05)

	Male (n= 4)	Female (n =4)
Total brain weight/g	11.26 ± 1.6	8.94 ± 1.15*
Cerebellum weight / g	1.83 ± 0.12	1.35 ± 0.07*
Total brain length ¹ mm	49.35 ± 5.5	45.93 ± 7.32
Right cerebral hemisphere length ² /mm	43.72 ± 9.48	40.08 ± 2.53
Left cerebral hemisphere length /mm	41.35 ± 5.5	39.89 ± 3.1
Right cerebral hemisphere width ³ /mm	26.42 ± 1.06	23.70 ± 1.56*
Left cerebral hemisphere width/mm	23.25 ± 5.73	22.19 ± 2.40
Cerebellum length ⁴ mm	14.56 ± 1.60	11.42 ± 0.96
Cerebellum width ⁵ mm	16.86 ± 1.67	12.1 ± 2.05
Right olfactory bulb length ⁶ mm	9.74 ± 1.45	7.05 ± 0.75*
Left olfactory bulb length/ mm	8.95 ± 0.56	7.10 ± 1.34*
Right olfactory bulb width ⁷ mm	6.6 ± 0.13	5.31 ± 0.26*
Left olfactory bulb width/ mm	6.23 ± 1.87	4.45 ± 0.87*
Rostral Colliculus length / mm	4.35 ± 0.18	3.85 ± 0.26
Caudal Colliculus length / mm	4.23 ± 0.82	3.93 ± 0.50

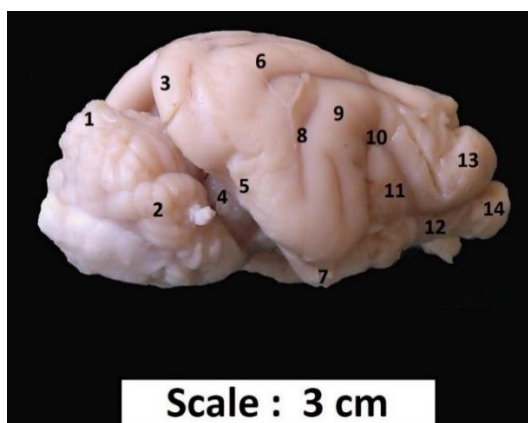


Figure 1. Lateral view of the brain in male mongoose.

1. Vermis of the cerebellum, 2. Cerebellar hemisphere, 3. Occipital lobe, 4. Transverse fissure, 5. Suprasylvian gyrus, 6. Ectomarginal gyrus, 7. Piriform lobe, 8. Suprasylvian sulcus, 9. Ectosylvian gyrus, 10. Ectosylvian sulcus, 11. Sylvian gyrus, 12. Olfactory peduncle, 13. Frontal lobe, 14. Olfactory bulb

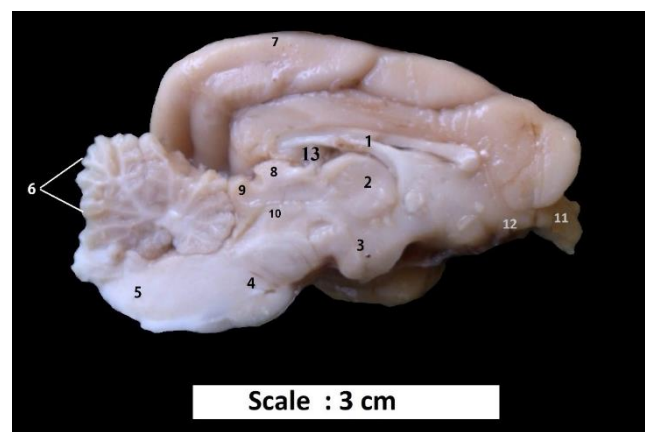


Figure 2. Median section of the brain in male mongoose.

1. Corpus callosum, 2. Inter-thalamic adhesion 3. Hypothalamus, 4. Pons, 5. Medulla oblongata, 6. Cerebellar folia, 7. Cerebral cortex, 8. Rostral Colliculus 9. Caudal Colliculus, 10. Tegmentum, 11. Olfactory bulb, 12. Olfactory peduncle, 13. Lateral ventricle.

¹The distance between the apex of the left olfactory lobe to the end of the cerebellum.

²The distance between the apex of the right olfactory lobe to the end of the cerebral hemisphere.

³Maximum width at the base of the right cerebral hemisphere.

⁴Maximum length of the cerebellum

⁵Maximum width of the cerebellum.

⁶Maximum length of the right olfactory bulb.

⁷Maximum width of the right olfactory bulb.

Discussion

It was found in this study that the EQ is 0.95 % and 1 % in mature males and females, respectively, which is due to the more weight in male mongooses. In chinchilla and most rodents, no difference was between males and females in brain weight. The EQ is 2% in humans and rhesus macaques, 0.63 % in rabbits, 0.64 % in giraffes, 0.5 % in laboratory rats, 0.85 % in cats, 0.3% in cows, 0.56 % in sheep, 0.83% in dogs and 0.25 % in catfish (Nieuwenhuys *et al.*, 1998; Irimescu *et al.*, 2014). Among the terrestrial mammals, the elephant brain is the heaviest, with 4873 gr. of weight, which forms about one percent of its total body weight (Shoshani *et al.*, 2006). In general, the EQ is the highest in humans and primates and the least in fish. The EQ in mongooses is slightly higher than other carnivores such as dogs (Nieuwenhuys *et al.*, 1998; Graic *et al.*, 2017). According to Eric (2006) and Russel (1979), high EQ is directly related to animals' intelligence and mental capacity. Also, according to studies by González-Lagos *et al.* (2010), in mammals with a higher EQ, there is longer physical and sexual life.

The mean weight of the cerebellum to the brain is 16.2 % in male and 15.1 % in female mongooses, while it is 10 % in humans, 8.1 % in cows, 15.3 % in sheep, 8.3 % in dogs, 16.5 % in rabbits, 14.5 % in rats, 17.6 % in cats and 15.2 % in mice (Sultan and Braitenberg, 1993). The relatively greater size of the cerebellum is associated with the center of equilibrium. In hunting and escape processes, this feature is noticeable compared to the other carnivores. (Pal *et al.* 2003; Rasouli *et al.* 2020).

No difference was found between the mongoose and other carnivores such as dogs and cats regarding the gyri and sulci's number and pattern on the cerebral cortex. However, no Sylvian sulcus was seen from

the lateral view of the brain (Figure 1). The number of gyri and sulci was fewer than that in humans, elephants, horses, and more than other rodents. More gyri and sulci lead to more brain volume and more neurons. Therefore, the cerebrum develops more in these animals. (Treuting and Dintzis, 2012; Pakozdy *et al.*, 2014).

After the median section, it was found that the rostral and caudal colliculus were of the same size (Figure 2). The rostral colliculus in rabbits and cows is larger and related to the optical path (König and Leibich, 2020). Simultaneously, the caudal colliculus is larger in dolphins and pigs related to the auditory path. Therefore, it can be concluded that sight in mongoose is considerable as hearing, which is a positive point for the animal's sensory abilities. The existence of complex voice communications among the monkey population has been proven and can match these characteristics (Schmidt *et al.*, 2009).

There were grooves on the vermis in median view, and the number of the grooves in the samples was 10 to 12, which are also found in cats and dogs (Dyce *et al.*, 2017). Previous studies estimated the number of these grooves to be 8 in the mice and 12 to 13 in elephants (Shoshani *et al.*, 2006).

According to this study, it can be inferred that the properties of the mongoose brain are consistent with behavioral and social habits. More specifically, this study showed that morphologically, mongoose brain and carnivores such as dogs and cats are similar (Dyce *et al.*, 2017). But in terms of morphometric features, and especially about EQ, and the mongoose is superior. The high brain coefficient shows the high mental abilities of the animal. The present study is a preliminary assessment of the anatomical properties of the brain in the mongoose. For more complete studies in the future, the use of new imaging methods and assessing the development of the nervous system in the fetuses are suggested.

Acknowledgments

The authors would like to thank Shiraz University for financial support.

Conflict of interest

The authors have no conflicts of interest.

Funding

This research project has been financially supported by Shiraz University.

References

- Abraham, M.S., Muhammad, Y.F., Ademola, O.A., Ibegbu, J.A., & Oseloka, A. (2016). Comparative Anatomical Studies of the Cerebrum, Cerebellum, and Brainstem of Males Guinea pig (*Cavia porcellus*) and Rabbit (*Oryctolagus cuniculus*). *Journal of Veterinary Anatomy*. 9(2),1–14.
- Danmaigoro, A., Hena, S.A., Ibrahim, A.A., Shehu, S.A. & Mahmud M.A. (2016). Comparative Morphometry and Histological Studies of the Cerebellum of Catfish (*Clarias gariepinus*) and Tilapia (*Oreochromis niloticus*). *Journal of Applied Life Sciences International* .7(4)1-6.
- Dyce, K.M., Sack, W.O. & Wensing, C.J.G. (2017) Textbook of Veterinary Anatomy. 5th edition. Philadelphia, US, Saunders. pp 479 – 490.
- Eric, H.C. (2006). Brain facts and figures. In: Neurosciences for Kids. University of Washington, Washington, America. pp 1-8.
- González-Lagos, C., Sol, D. & Reader, S.M. (2010). Large-brained mammals live longer. *Journal of Evolutionary Biology*. 23(5),1064-74.
- Graic, J.M., Peruffo A., Ballarin, C., & Cozzi B. (2107). The Brain of the Giraffe (Giraffe Camelopardalis) Surface Configuration, Encephalization Quotient, and Analysis of the Existing Literature. *Anatomical Records*. 300(8),1502-1511.
- Ibegbu, A.O., Adubazi, P., Yahaya, B.O., Musa, S.A. (2014) Comparative Micromorphological Studies of the Cerebrum in Three Mammalian Species: Rabbits (*Oryctolagus cuniculus*), Wistar Rats (*Rattus norvegicus*) and African Giant Rats (*Cricetomys gambianus*). *Journal of Veterinary Anatomy*. 7(1),33 – 47.
- Irimescu, I., Bolfa, P., Crisan, M., Dezdrobitu, C. & Damian A. (2015). Macroscopical and histological aspects of the cerebellum in chinchillas, *Agriculture and Agricultural Science Procedia* 6, 350-357.
- König, H.E. & Leibich, H.G. (2020). Veterinary Anatomy of Domestic Animals Textbook and Colour (7th ed.) Schattauer Verlag, Vienna, Austria. pp. 233-258.
- Nieuwenhuys, R., Ten Donkelaar, H.J. & Nicholson, C (1998) The Central Nervous System of Vertebrates., Berlin: Springer. 3, 25 -29.
- Pakozdy, A., Angerer, C., Klang, A., König, E.H. & Probst, A. (2014). Gyration of the feline brain: localization, terminology and variability. *Anatomia Histologia Embryologia*, 44(6):422-7
- Pal, B., Chowdhury, S., & Ghosh, R.K., (2003). Comparative anatomical study of the cerebellum of the man and fowl. *Journal of the Anatomy Society of India*. 52 (1), 1-8.
- Russel, M.S. (1979). The brain size and intelligence: comparative perspective in brain behavior and evolution (Oakly and Plotkin ed.), Associated Book Publishers, London. pp: 127-53.
- Rasouli, B., Gholami, S. Ahrari. M.S. 2015. Topographic and morphometric studies on the spinal cord of the male and female indian gray mongoose (*herpestes edwardsii*), *Cibtech Journal of Zoology*. 4(3):75-82.
- Rasouli, B. & Gholami, S. (2020). Histological Aspects of Cerebrum and Cerebellum in Adult Male and Female Mongoose (*Herpestes edwardsii*). *Iranian Journal of Veterinary Medicine*. 14(3), 305-314
- Schmidt, M.J., Pilatus, U., Wigger, A., Kramer, M. & Oelschlager, H.A. (2009). Neuroanatomy of the calf brain as revealed by high-resolution magnetic resonance imaging. *Journal of Morphology*. 270,745–758.
- Shoshani, J., kupsky, W.J. & Merchant, G.H. (2006). Elephant Brain. Part 1: Gross Morphology functions, comparative anatomy and evolution. *Brain Research Bulletin*, 70,124-157.
- Sultan, F. & Braitenberg, V. (1993) Shapes and sizes of different mammalian cerebella. A study in quantitative comparative neuroanatomy. *Journal of Hirnforsch*. 34,79-92.
- Treuting, P.M., Dintzis, S.M., (2012). Comparative Anatomy and Histology, A Mouse and Human Atlas, 1st edition, Academic Press, Elsevier, New York. pp: 340-370.

Received: 10.11.2020

Accepted: 14.07.2021

مطالعه‌ی مورفومتریک مخ و مخچه در خدنگ هندی خاکستری (*Herpestes edwardsii*)

بابک رسولی^۱، صغرا غلامی^{۲*} و یونس کمالی^۳

^۱ استادیار گروه علوم پایه، دانشکده دامپزشکی، دانشگاه سمنان، سمنان، ایران

^۲ استاد گروه علوم پایه، دانشکده دامپزشکی، دانشگاه شیراز، شیراز، ایران

^۳ استادیار گروه علوم پایه، دانشکده دامپزشکی، دانشگاه شیراز، شیراز، ایران

پذیرش: ۱۴۰۰/۴/۲۳

دریافت: ۱۳۹۹/۸/۲۰

چکیده

خدنگ نام حیوانی است که شامل ۳۰ گونه از خانواده‌ی خدنگیان (*Herpestidae*) می‌باشد و در نواحی وسیعی از جنوب غرب آسیا و به خصوص در ایران یافت می‌شوند. مطالعات آناتومیکی و مورفومتریک مغز به دلیل اهمیت بالای آن در زمینه‌های مختلف دامپزشکی و جانورشناسی مورد توجه متخصصین علوم تشریح بوده است. به دلیل کمبود اطلاعات لازم پیرامون ساختمان مغز در گوشته‌خواران وحشی، مطالعه‌ی حاضر به منظور ادراک بهتر از ویژگی‌های مورفومتریک آن در خدنگ انجام گرفت. بدین منظور از لاشه‌ی ۸ قلاده خدنگ بالغ که در نواحی مختلف استان فارس بر اثر حوادث طبیعی مرده بودند، استفاده گردید. در ادامه مغز به دقت از جمجمه جدا شده و اندازه‌گیری و مشاهدات لازم بر روی قسمت‌های مختلف آن ثبت گردید. اعداد به دست آمده از اندازه‌گیری‌ها به تفکیک جنسیت، به کامپیوتر داده شده و به منظور آنالیز آماری از برنامه‌ی SPSS (نسخه‌ی ۲۲) و آزمون تی دانشجویی (T.student) استفاده گردید. سطح $P \leq 0.05$ برای معنادار بودن اختلاف بین داده‌ها در نظر گرفته شد. نتایج این مطالعه نشان داد که نسبت وزن مغز به وزن بدن (EQ) و همچنین نسبت وزن مخچه به وزن کل مغز در خدنگ از سایر گوشته‌خواران بیش‌تر است. به طور کلی، یافته‌های مورفومتریک مغز خدنگ با سبک زندگی حیوان هم‌مانگی دارد. از لحاظ الگوی برآمدگی‌ها و فرورفتگی‌های سطح مخ تفاوتی بین خدنگ و بقیه گوشته‌خواران دیده نشد. این مطالعه یک ارزیابی اولیه بوده و به منظور مطالعات پیشرفته‌تر، استفاده از روش‌های تصویربرداری جدید پیشنهاد می‌شود.

کلمات کلیدی: خدنگ، مغز، آناتومی، مورفومتری

*نویسنده مسئول: صغرا غلامی، استاد گروه علوم پایه، دانشکده دامپزشکی، دانشگاه شیراز، شیراز، ایران

E-mail: Gholami@shirazu.ac.ir



© 2020 by the authors. Licensee SCU, Ahvaz, Iran. This article is an open access article distributed under the terms and conditions of the Creative Commons Attribution-NonCommercial 4.0 International (CC BY-NC 4.0 license) (<http://creativecommons.org/licenses/by-nc/4.0/>).